

## Dental Implants and Osseoperception: A Systematic Review

Dr. Bini K Ravi<sup>1</sup>, Dr. Harshakumar K<sup>2</sup>, Dr. Prasanth V<sup>3</sup>, Dr. Kavitha Janardanan<sup>4</sup>.

<sup>1</sup>Junior resident, <sup>2</sup>Professor and H.O.D., <sup>4</sup>Assistant Professor, Department of Prosthodontics & Crown and Bridge, Government Dental College, Thiruvananthapuram, Kerala, India)

<sup>3</sup>(Associate Professor, Department of Prosthodontics & Crown and Bridge, Government Dental College, Alappuzha, Kerala, India)

---

### Abstract:

**Background:** Toothloss and its replacement have significant functional and psychosocial consequences. The removal of intra-dental and periodontal mechanoreceptors accompanying toothloss changes the fine proprioceptive control of jawfunction and influences the precision of magnitude, direction, and rate of occlusal load application. Implant-supported prostheses restore jawfunction more appropriately, with improved psychophysiological discriminatory ability and oral stereognosis. The term osseoperception describes the capability of developing a subtle tactile sensibility over dental implants. In this article, an attempt to discuss the various aspects regarding the perception of mechanical stimuli in the vicinity of osseointegrated oral implants have been done.

**Materials and Methods:** An electronic search was done of PubMed, Google Scholar, Institutional Library and manual search of various journals. The inclusion criteria composed of all randomised control trials and observational studies evaluating the neurophysiological and histological aspects of osseoperception around dental implants. All articles and abstracts of articles selected were in English language. The articles included were from the year 1966 to 2019

**Results:** To date, the published literature describing osseoperception around dental implants is very less. 127 articles were found in literature of which 11 satisfied the inclusion criteria were included in this systematic review.

**Conclusion:** The question to what extent dental implants are integrated in the existing stomatognathic control circuit is still unanswered. But the study shows that patients with osseointegrated implants subjectively feel tactile sensation.

**Key Words:** Dental implants, osseointegration, osseoperception

---

Date of Submission: 20-12-2019

Date of Acceptance: 03-01-2020

---

### I. Introduction

Normal functioning of the stomatognathic system requires perfect anatomic and physiological integration among the jaw bones, teeth, periodontium, and temporomandibular joint through reflex arcs controlled by the neuromuscular system (Ramfjord & Ash 1972)<sup>1</sup>. Proprioceptive feedback plays an important role in tuning fine motor control and modulating complex mandibular movements, sensory discriminative capabilities, and masticatory protective reflex<sup>1</sup>. In dentate individuals, this sensory input might be provided by the following two groups of mechanoreceptors. Remote fibers which originate in the temporomandibular joint, oral mucosa, masticatory muscles, periosteum, and even dental pulp, correspond only to discriminating larger particles; whereas, proprioceptors in periodontal ligament (PDL) can respond to finer stimuli, contributing to specification of the direction, magnitude, and the point of attack of the occlusal forces<sup>1-3</sup>. Removal of proprioceptor fibers in the PDL after tooth extraction<sup>4</sup> might undermine this precision.

With the loss of all teeth, complete denture restoration is a compromised replacement which only partially restores function. Edentulism leads to an impairment of oral function with esthetic and psychological changes. Adaptation to conventional complete dentures is a complex learning process, when considered on a somatic and psychological basis. Patients, who are originally adaptive wearing complete denture, may become maladaptive with time, due to ongoing residual ridge resorption<sup>2</sup>. Removable dentures have slowly given way to fixed prosthetic options as a result of the increased demand for esthetics and comfort.

Rehabilitation of partially or totally edentulous patients with dental implants has become a common practice in recent decades, with reliable long-term results<sup>2</sup>. In the last two decades, it became clear that clinical implantology had advanced to the point that this treatment represented a predictable approach to the replacement of lost teeth. Since the description of the process of osseointegration by Brånemark et al., dental implants have

become ideal replacements for missing teeth<sup>3</sup>. The introduction of osseointegrated implants in dentistry symbolizes a turning point in dentistry.

Osseointegrated implants provide alternative treatment options for such patients with better functional integration due to certain tactile sensitivity called osseoperception<sup>5</sup>. It has even been assumed that by anchoring prosthetic limbs directly to the bone via osseointegrated implants, a partial sensory substitution can be achieved (Jacobs 1998)<sup>6</sup>. Indeed, patients with a lower limb prosthesis anchored to percutaneous osseointegrated implant reported that this allows them to feel the type of soil they walked on, while with a socket prosthesis, they only detected contact that was made with the floor (Branemark 1997). This phenomenon was denoted as “osseoperception”, suggesting that the peripheral feedback pathway can be (partly) restored by means of prostheses anchored to osseointegrated implants (Feine et al. 2006)<sup>6</sup>.

## II. Material And Methods

An electronic search was done of PubMed, Google Scholar, Institutional Library and manual search of various journals. The inclusion criteria composed of all randomised control trials and observational studies evaluating the neurophysiological and histological aspects of osseoperception around dental implants. All articles and abstracts of articles selected were in English language. The articles included were from the year 1966 to 2019.

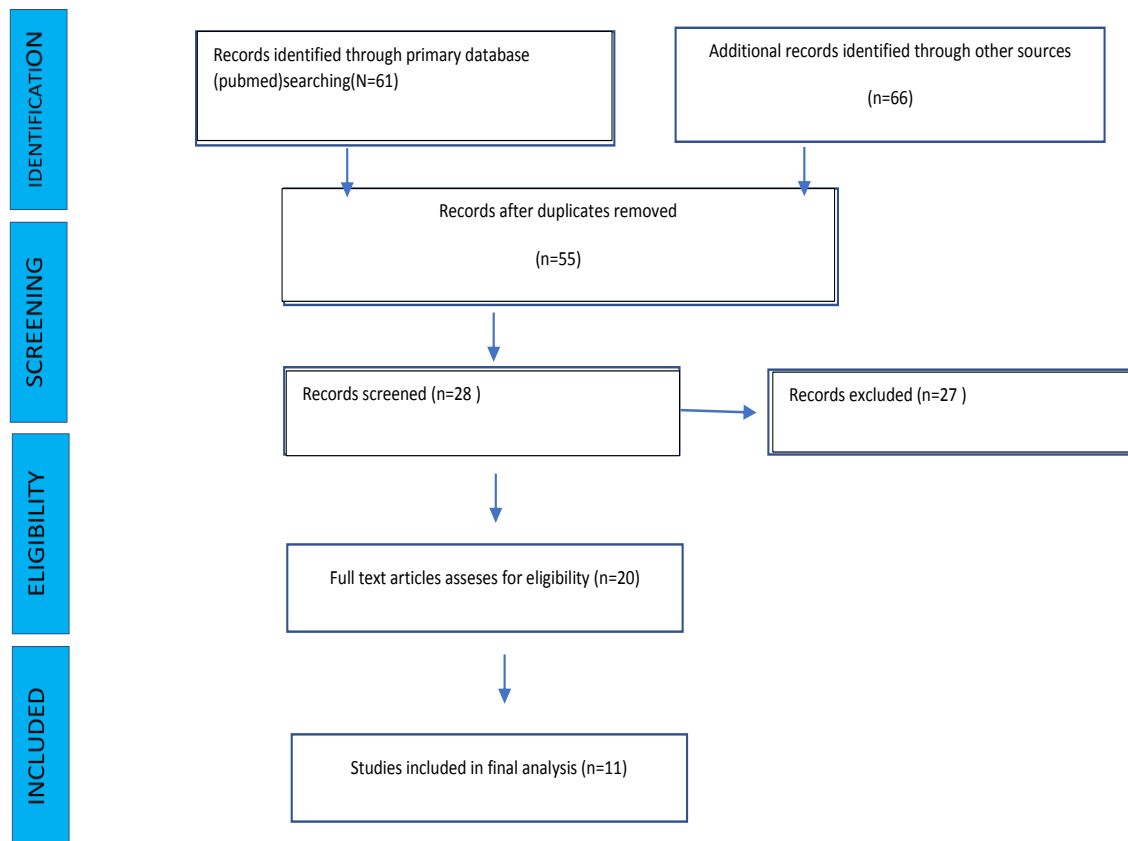
**Study Design:** observational study

**Study Duration:** 1966 to 2019

**Inclusion criteria:**

1. The inclusion criteria composed of all randomised control trials and observational studies evaluating the neurophysiological and histological aspects of osseoperception around dental implants. All articles and abstracts of articles selected were in English language. The articles included were from the year 1966 to 2019.

**Flow chart showing the study design and the details of inclusion / exclusion of article**



## III. Result

An increased innervations in the peri-implant epithelium after implant placement<sup>5</sup> Animal studies have demonstrated that regenerated nerve fibers in the periimplant gingiva show the same neural characteristics as those in the normal, dental junctional epithelium<sup>6,7</sup>. Regenerative nerve fibers invade the superficial layer of the peri-implant epithelium. These nerve fibers contain substance P and possess free nerve endings. They may respond to pain, touch, and pressure<sup>8</sup>.

The changes in bone innervation patterns associated with implant placement were first reported by Sawada et al<sup>9</sup>. The presence of nerve fibres involved in bone remodelling and growth at the interface between living and necrotic bone tissue has shown that nerve fibres can regenerate after implant placement<sup>9-11</sup> recently, Habre-Hallage et al<sup>12</sup> proved that pure mechanical stimulation of an implant could be perceived at the sensory cortex using functional magnetic resonance imaging (fMRI). The study shows that patients with osseointegrated implants subjectively feel tactile sensation<sup>13</sup>.

#### **IV. Discussion**

##### **CONCEPT OF OSSEOPERCEPTION**

Perceptions of static jaw position and velocity of jaw movement (whether imposed or voluntarily generated) and forces generated during contractions of the jaw muscles constitute oral kinesthetic and proprioceptive sensations<sup>2</sup>.

Tooth loss implies the elimination of periodontal ligament receptors and the destruction of the great majority of the peripheral feedback pathways. Edentulous individuals rehabilitated with conventional complete dentures (CDs) present a significant reduction in the sensory function, such as inter-occlusal tactile perception and stereognosis, as compared with dentate individuals<sup>3</sup>.

This is fully explained because edentulous subjects wearing conventional CDs make use of less efficient proprioceptive receptors, including Meissner's corpuscles, glomerular endings, Merkel cells, and free nerve endings, located on the gingival tissues over the residual alveolar crest, muscles, tendons, and joint capsules of the temporomandibular joint to compensate for the lack of mechanoreceptors in the periodontal ligament; consequently, the oral function remains impaired. When patients wearing complete dentures are rehabilitated with implant-supported dentures, the interocclusal tactile threshold is recovered. Thus, it may be concluded that there is a close relationship between osseointegrated implants and improved oral functions. This phenomenon is called osseoperception and is defined as the conscious perception of external stimulus transmitted by means of a bone-anchored prosthesis through the activation of neural terminations and/or receptors in the peri-implant environment, such as the bone and, more likely, the periosteum<sup>11</sup>.

The osseointegrated dental implants physiologically differ from natural teeth as they lack periodontal ligament support and hence when loaded mechanically, evoke the peculiar sensation of osseoperception. Hence the osseointegrated implants not only become a part of the body but also of the mind and this mental acceptance is named as osseoperception<sup>12</sup>.

##### **FACTORS AFFECTING OSSEOPERCEPTION**

Factors that could affect the tactile sensibility or 'osseoperception' of alloplastic implants include age and gender, the time of implantation, the prosthetic period of function, and the properties of the implant: implant surface and implant geometry, i.e., implant length and diameter. The amount of bone attached to the implant, may be of importance. The larger the bone-to-implant contact surface, tactile sensibility could be the greater. In tests with the Periotests device, it could be shown that implants with a smaller diameter, and therefore a smaller surface, had a markedly smaller area of bone contact.

The presence or absence of periodontal mechanoreception must have direct bearing on tactile discrimination. Passive tactile discrimination is dependent on periodontal mechanoreception and is assessed by the application of controlled forces to a tooth. Active tactile discrimination is based on objects placed between teeth, and involves a number of mechanoreceptor inputs located in teeth, periodontium, jaw muscles, and temporomandibular joint (TMJ) capsules and ligaments. Both active and passive discriminative abilities decrease with age<sup>14</sup>.

##### **NEUROPHYSIOLOGY OF OSSEOPERCEPTION**

The physiological basis of osseoperception is not yet fully known. But two thesis are suggested as probable reasons for this :

- a) an activation of local receptors in the bone and
- b) an activation of more remote receptors<sup>4</sup>

Normal functioning of the stomatognathic system requires perfect anatomic and physiological integration among the jaw bones, teeth, periodontium, and temporomandibular joint through reflex arcs controlled by the neuromuscular system. The oral sensory function involves several activities, including the control of mandibular positioning and movement, masticatory forces, stereognosis, as well as inter-occlusal tactile sensibility. For this purpose, by activation of specific peripheral receptors on several sites in the masticatory system, the nervous impulse follows the afferent pathway, involving first and/ or second-order neurons, reaching the integration nuclei in the thalamus or the cerebellum, and potentially activating the cerebral cortex to become<sup>3</sup>.

The pathway of proprioceptive signals is initiated by a tactile stimulation of the Ruffini-like ending receptors located in the periodontal ligament, which pass through the first-order neuron, whose body is located in the trigeminal ganglion. It then passes via the main sensitive nucleus to connect with the second-order neuron, whose body is located in the thalamus, where there is also a connection with the third-order neuron. This, in turn, reaches the primary sensitive cortex, where the stimulus is interpreted and a motor response is triggered<sup>1</sup>.

Some evidence tends to support the hypothesis of physiological and functional integration of implants in the body and thus, the sprouting of new fibers and free nerve endings close to the bone-to-implant interface, with partial regeneration of periodontal ligament on the implant surface. It has also been assumed that the fast elastic deformation of a bone during loading over implants may in fact activate the periosteal mechanoreceptors in the fascia, periosteum, and periodontal ligament, and thus contribute to the restoration of peripheral feedback<sup>1</sup>.

Edentulous patients with implant-supported prostheses report improved tactile discriminative capabilities and motor function compared with when they wore complete dentures. Sensation of osseoperception is generated from the temporomandibular joint, masticatory muscle, mucosa, and periosteum, and provides sensory and motor information related to mandible movements and occlusion<sup>15</sup>.

To evaluate oral sensorimotor function of a patient, psychophysical studies can be carried out determining tactile threshold levels, as well as Oral Stereognostic Ability and Oral Motor Ability<sup>10,16</sup>. Other functional tests such as the directional cutaneous kinaesthesia (DCK) and graphaesthesia (G) can be used<sup>12</sup>.

A study on Cortical correlates of osseoperception by Habre-Hallage et al demonstrates for the first time that punctuate mechanical stimulation of osseointegrated maxillary implants activates cortical somatosensory areas. This activation may represent the underlying mechanism of osseoperception. It also suggests that tooth loss and its replacement by an osseointegrated implant induces brain plasticity as indicated by the difference between the cortical network activated when stimulating either the implant or a natural tooth at the same location<sup>14</sup>.

## HISTOLOGICAL FINDINGS

It has been histologically documented that the number of nerve fibers per unit area is greater in the anterior areas of the oral cavity, making this region the most sensitive part of the oral mucosa<sup>17</sup>. They demonstrate a lower sensitivity when localized on the ridge (crest) when compared with the vestibular areas, suggesting that receptor density is more important in the former<sup>6,7</sup>. The changes of the dental representation in the primary somatosensory cortex was investigated after the extraction of a single lower tooth in the naked mole-rats<sup>16</sup>. Five to eight months after tooth extraction, a dramatic reorganization of the orofacial representation in the primary somatosensory cortex was observed for the zone that lost input from the extracted teeth. Neurons in the cortical lower tooth representation were responsive to tactile inputs from surrounding orofacial structures, including the contralateral upper incisor, ipsilateral lower incisor, tongue, chin, gums, and buccal pad. These results suggest that the representation of the dentition in mammals is capable of significant reorganization after the loss of sensory inputs from the teeth<sup>16</sup>.

Histological findings reported an increased innervations in the peri-implant epithelium after implant placement<sup>16</sup>. Animal studies have demonstrated that regenerated nerve fibers in the periimplant gingiva show the same neural characteristics as those in the normal, dental junctional epithelium<sup>6,7</sup>. Regenerative nerve fibers invade the superficial layer of the peri-implant epithelium. These nerve fibers contain substance P and possess free nerve endings. They may respond to pain, touch, and pressure<sup>8</sup>.

The changes in bone innervation patterns associated with implant placement were first reported by Sawada et al<sup>9</sup>. The presence of nerve fibres involved in bone remodelling and growth at the interface between living and necrotic bone tissue has shown that nerve fibres can regenerate after implant placement<sup>6</sup> recently, Habre-Hallage et al proved that pure mechanical stimulation of an implant could be perceived at the sensory cortex using functional magnetic resonance imaging (fMRI). The study on Histological findings in humans in relation to Peri-implant bone innervations by Corpas et al is the first to report nerve fibres in the peri-implant bone of the human jaw<sup>14</sup>.

Along with the increasing evidence of osseoperception in neurophysiology and psychophysics, histological studies further demonstrated that this phenomenon may be attributed not only to neural endings in the bone-implant interface itself but also to neural endings located at some distance such as the periosteum, which was described as "osseoreceptors"<sup>17</sup>. An increased innervation in the epithelium around implants was confirmed after implant placement, proving that existing mechanoreceptors in the periosteum may play a role in tactile function upon implant loading. On the other hand, although surgical trauma due to implant placement may induce the degeneration of enviroing neural fibres, some reinnervation occurs around osseointegrated implants<sup>17</sup>.

The CNS has two mechanisms for obtaining information about the positions and movements of limbs and forces of limb muscle contraction, i.e., limb kinesthesia<sup>2</sup>. These mechanisms are also likely to operate for oral kinesthetic perception :

(a) The first is by monitoring a corollary discharge (or efference copy or collateral discharge) of the descending central command to muscles. Corollary discharge, possibly together with an input from Golgi tendon organs (GTOs) associated with the jaw-closing muscles, is therefore presumably important in the sensation of effort in voluntary biting. Corollary discharge, however, does not provide a sensation of movement or altered position.

(b) The second mechanism is derived from mechanoreceptors activated during limb and jaw movements and at different limb and jaw positions. In the context of implant-supported prostheses, the term osseoperception was proposed (P-I Branemark, personal communication) to recognize oral kinesthetic perceptual abilities, in the absence of a functional periodontal mechanoreceptive input. This input is derived from temporomandibular joint (TMJ), muscle, cutaneous, mucosal, and/or periosteal mechanoreceptors, and provides mechanosensory information for oral kinesthetic sensibility in relation to jaw function and artificial tooth contacts. The relative contributions of these different mechanoreceptors to osseoperception in patients with implant-supported prostheses are unclear<sup>2</sup>. Unfortunately, it remains difficult to link neurophysiological observations with histological data, i.e. function to morphology.)

Dense innervations of myelinated nerve fibres are distributed heterogeneously in the human PDL with increased density in the loaded (i.e. the apical) areas. Tooth extraction may thereby be considered as a form of amputation causing changes in oral motor behaviour and impairment of natural biting function with loss of periodontal mechanoreceptors as well as intradental nociceptors<sup>17</sup>.

The peripheral feedback pathway can be (partly) restored by means of prostheses anchored to osseointegrated implants. Psychophysical studies indicated that fixed or removable implant-supported prostheses allowed for the recovery of the interocclusal tactile threshold and even for the activation of the primary sensorimotor cortex at levels similar to that of natural teeth. It was further found that active tactile sensibility of implants with natural antagonistic teeth is very similar to that of teeth implying that receptors near the implant form the basis of osseoperception. Moreover, the magnitude of passive sensation consistently increased with an increase in loads . The sensory nerve action potential of the inferior alveolar nerve stem could be recorded following stimulations to implants. Recently, neurophysiological evidence was obtained using functional MRI, showing an activation of the human sensory cortex after mechanical stimulation of incisor implants and teeth<sup>18</sup>

## V. Conclusion

The question to what extent dental implants are integrated in the existing stomatognathic control circuit is still unanswered. But the study shows that patients with osseointegrated implants subjectively feel tactile sensation. More studies should be conducted in an attempt to locate specific groups of tactile receptors that transmit information to the central nervous system in subjects with implant-supported prostheses. Furthermore, efforts should be made to promote greater interaction with other areas of medicine to investigate neurologically sensory impulses originating from oral osseointegrated implants..

## References

- [1]. Enkling N, Heussner S, Nicolay C, Bayer S, Mericske-stern R, Utz K. Tactile Sensibility of Single-Tooth Implants and Natural Teeth Under Local Anesthesia of. 2009;273–81.
- [2]. Klineberg I, Murray G. Osseoperception : sensory function and proprioception . 2019;1–2.
- [3]. Batista M, Bonachela W, Soares J. Progressive recovery of osseoperception as a function of the combination of implant-supported prostheses. 2008;565–70.
- [4]. Enkling N, Heussner S, Nicolay C, Bayer S, Mericske-stern R, Utz K. Tactile Sensibility of Single-Tooth Implants and Natural Teeth Under Local Anesthesia of the Natural Antagonistic Teeth. 2019;2019:1–16.
- [5]. Peres MS, Chaves E, Rodriguez-Martinez J, Munoz-Soto E. Ridge expansion with motor driven bone expanders: A clinical case report. Eur J Gen Dent. 2015;4(1):12.
- [6]. Medicine E. Microscopic , immunocytochemical , and ultrastructural properties of peri-implant mucosa in. 2019;73(5):9–10.
- [7]. Prosthodontics F, Sciences D. Regeneration of nerve fibres in the peri-implant epithelium incident to implantation in the rat maxilla as demonstrated by immunocytochemistry for protein gene product 9 . 5 ( PGP9 . 5 ) and calcitonin gene-related peptide ( CGRP ). 2019;14(2):1–2.
- [8]. Tanaka T, Kido MA, Ibuki T, Yamaza T, Kondo T, Nagata E. Connect with Wiley. 2019;31(3):25–7.
- [9]. Sawada M, Kusakari H, Sato O, Maeda T, Takano Y. Nihon Hotetsu Shika Gakkai Zasshi Histological Investigation on Chronological Changes in Peri-implant Tissues. 2019;37(1):10–3.
- [10]. Oral stereognosis and oral ability in relation to prosthetic treatment . 2019;120(4):5216507.
- [11]. Fransson B. Oral ability to recognize forms and oral muscular coordination ability in dentulous young and elderly adults . 2019;2(2):1–2.
- [12]. Habre-hallage P, Abboud-naaman NB, Reychler H, Steenberghe D Van, Jacobs R. Perceptual Changes in the Peri-Implant Soft Tissues Assessed by Directional Cutaneous Kinaesthesia and Graphaesthesia : 2009;296–305.
- [13]. Yan C, Ye L, Zhen J, Ke L, Gang L, Ye L. Neuroplasticity of edentulous patients with implant - supported full dentures. 2019;116(5):10–2.

- [14]. Habre-hallage P, Dricot L, Jacobs R, Steenberghe D Van, Van D. Brain plasticity and cortical correlates of osseoperception revealed by punctate mechanical stimulation of osseointegrated oral implants during fMRI. 2012;5(2):175–90.
- [15]. Angeles L. Pressure-pain threshold of oral mucosa and its region-specific modulation by pre-loading . 2019;30(11):11–2.
- [16]. Plasticity of the cortical dentition representation after tooth extraction in naked mole-rats . 2019;485(1):25–6.
- [17]. Huang Y, Jacobs R, J VD, Mm B, Lambrichts I, Politis C. A systematic review on the innervation of peri-implant tissues with special emphasis on the influence of implant placement and loading protocols . 2019;26(7):1–2.
- [18]. Huang Y, Dessel J Van, Martens W, Lambrichts I, Zhong W, Ma G, et al. Sensory innervation around immediately vs . delayed loaded implants : a pilot study. Int J Oral Sci [Internet]. 2015;7(1):49–55. Available from: <http://dx.doi.org/10.1038/ijos.2014.53>

Dr.Bini K Ravi. “Dental Implants and Osseoperception: A Systematic Review.” IOSR Journal of Dental and Medical Sciences (IOSR-JDMS), vol. 19, no. 1, 2020, pp 55-60.