

## “A Retrospective Analysis of 137 Chronic Dacryocystitis Cases Treated with Endonasal Endoscopic Approach to Dacryocystorhinostomy with and Without Silicon Stent”

<sup>1</sup>Dr Shailendra Gupta<sup>2</sup>, Dr Anupam Minj<sup>3</sup>, Dr. Abhijeet Jain

<sup>1</sup>Assistant professor , Otorhinolaryngology[E.N.T] department, G.M.C. Ambikapur(c.g)

<sup>2</sup>Senior resident Otorhinolaryngology[E.N.T]department, G.M.C. Ambikapur(c.g)

<sup>3</sup> Assistant professor , ophthalmology[EYE] department, G.M.C. Ambikapur(c.g)

Corresponding Author: Dr Shailendra Gupta

### Abstract

#### Background: -

Nasolacrimal duct obstruction is the commonest factor affecting the lacrimal drainage system leading to chronic dacryocystitis. Various methods are used to improve nasolacrimal duct obstruction. Endonasal Endoscopic Dacryocystorhinostomy [EEDCR] is highly rewarding Endoscopic procedure for definite management of nasolacrimal duct obstruction. The formation of granulation tissue at stomal site is known to play an important role in failure of surgical outcome. In cases where the silicon Stent placed intra-operatively, the patency of the lacrimal apparatus is well maintained and yielded better results. The aim of present study was to evaluate the subjective and anatomic success of primary Endonasal DCR with and without silicon stent.

#### Material and method: -

The study involved the retrospective evaluation of 137 patients from department of ENT and referred cases from ophthalmology department of government medical college Ambikapur with complaint of chronic epiphora were included after evaluating inclusion and exclusion criteria and informed written consent. After the provisional diagnosis was done 55 control cases were taken retrospectively who had undergone endoscopic DCR without stenting through the upper and lower canaliculi. Endonasal DCR was done under local anesthesia with sedation. The free flow and patency was confirmed by syringing under endoscopic guidance. Stent was kept for a period of 6 weeks. This time allows all the raw surfaces in surgical site to heal. Cases were followed up for a period of 6 months and the results were compared. Outcome is considered as failure whenever the patients were subjective symptoms of severe epiphora.

#### Results: -

The current study included 137 patients. Females were predominant in both group ( $p$  values more than .05), with around 63% being females in group with stenting. Male to female ratio was 1:1.73 and 1:1.67 in group with stenting and without stenting. Failure rate of surgery was found to be 30.90% in group without stenting and 6.09% with stenting. The symptomatic success rate of the surgery at the end of 6 months was 94% in group with stenting and 69% in group without stenting.

**Conclusion:** - Overall success rate of the Endonasal DCR was 94% in group with stenting and indicate that lacrimal silicon tube intubation is an effective treatment procedure for patients of chronic dacryocystitis disease with common nasolacrimal duct obstruction.

**Key words:** Chronic Dacryocystitis, Dacryocystorhinostomy [DCR] Endonasal Endoscopic Dacryocystorhinostomy [EEDCR], lacrimal apparatus, nasolacrimal duct [NLD], silicon Stent.

Date of Submission: 03-09-2019

Date of Acceptance: 18-09-2019

### I. Introduction:-

Lacrimal system starts with lacrimal glands which secretes lacrimal fluid And drains into conjunctival sac via canalicular ducts [1].The lacrimal fluid provides moisture over corneal surface preventing dryness of eye.

Lacrimal fluids collect in the medial canthal segment Of eye where lacrimal sac is situated. During contraction phase of Orbicularis oculi muscle [2]the lacrimal fluid pump into upper puncta(30%) and lower puncta (70%)while Relaxation of Orbicularis oculi and lacrimal

muscle directs fluid from puncta and canaliculus to the lacrimal sac [3]Again contraction of these muscles compresses the fluid collected in the sac to the nasolacrimal duct situated in anterolateral wall of nose. Blockage of NLD whether intra luminal, extra luminal causes decreased outflow of lacrimal fluid and

resultant stasis of secretions causes inflammation of NLD as well as lower sac area. Recurrent blockage leads to complete adhesions and permanent blockage of NLD, resulting in Dacryocystitis. The term derives from the Greek *dákryon*(tear), *cysta* (sac), and *-itis* (inflammation). Chronic Dacryocystitis is a common ophthalmic problem, characterized as an inflammatory state of the nasolacrimal sac due to persistent infection and secondary to obstruction of the nasolacrimal duct at the junction of lacrimal sac. When the lacrimal sac inflames and swells at the inferomedial canthus, dacryocystitis can be judged clinically. It causes annoying symptoms like Persistent tearing (epiphora), mucous or mucopurulent discharge from the lacrimal puncti, chronic conjunctivitis and swelling of the lacrimal sac in the medial canthus. Even in mild conditions it may cause a significant ocular morbidity and can be socially embarrassing. It affects all ages but there is a bimodal distribution of onset age with most cases either occurring below one year of age in congenital cases or in adults older than 40 years of age. Females are affected at a higher rate than males.

Dacryocystorhinostomy (DCR) is a surgical procedure used for the treatment of chronic dacryocystitis. In DCR surgery, a stoma is created between medial wall of lacrimal sac and nasal cavity which will heal and form a fistula which will lead to the continuous drainage of tears into the nasal cavity thus curing the excess watering and stagnation of tears in the sac which caused the infection [4]. DCR can be performed by two different approaches, External approach and Endoscopic approach.

Various surgical procedures of Dacryocystorhinostomy (DCR) are used to improve continuous drainage of tears into the nasal cavity thus curing the excess watering and stagnation of tears in the sac which caused the infection. DCR can be performed by two different approaches, External approach and Endoscopic approach. Because of high failure rate and cosmetic importance; nowadays Endoscopic DCR is the surgery of choice over the older external approach [5]. Toti in 1904 described surgical treatment of NLD obstruction in chronic dacryocystitis as external Dacryocystorhinostomy, traditionally performed by the Ophthalmologist [6]. Mc Donogh and Meiring were the pioneer for the Endoscopic lacrimal sac surgery [7]. In the Dacryocystorhinostomy, reports suggest that Endoscopic approach is more successful with success rates ranging from 84% to 98% as compared to external approach Dacryocystorhinostomy thus gaining more popularity. Many factors influence the outcome of endoscopic DCR, and one of the most important prognostic factor is the obstruction level in the lacrimal drainage system. The use of stenting for DCR takes less time, less bleeding, increased patency rate, absence of scar and possibility to correct associated intranasal pathology during the same procedure. Okuyucu et al suggest that efficacy, defined as anatomic and functional success, is equally high for both silicone and prolene stents (Prolene; Ethicon, Inc.) [8].

As no such studies were undertaken before in our institution, a need for this study is required to determine the outcome in success rate of Endonasal Endoscopic lacrimal sac surgery with and without silicon stent which enables us to formulate better treatment guidelines for chronic nasolacrimal duct obstruction cases in our hospital.

## **II. Material and methods:-**

The study involved the retrospective evaluation of 137 patients with the diagnosis of chronic Dacryocystitis or failed previous DCR surgery that came to Otorhinolaryngology (ENT) and ophthalmology department of Government medical college Ambikapur and underwent Endonasal Endoscopic Dacryocystorhinostomy (EEDCR) procedure. Patients were included after evaluating inclusion and exclusion criteria and informed, written consent. Inclusion criteria were age more than 18 years, nasolacrimal duct obstruction, patent upper and lower canaliculi, previous failed Endonasal Endoscopic DCR. While cases of Congenital Dacryocystitis, gross systemic diseases, common canaliculi obstruction, granulomatous diseases of nose, polyps and patients not willing to consent were excluded from study. The pre-operative evaluation consisted of complete history taking, standard otolaryngologic and ophthalmic examination, palpation of lacrimal fossa to look for enlarged lacrimal sac, lacrimal syringing followed by irrigation and Nasal Endoscopy. After the diagnosis was done 55 control cases were taken retrospectively who had undergone endoscopic DCR without stenting by same method.

### **Operative procedure:-**

The procedure was done under local anaesthesia with sedation. Xylocaine 4% with adrenaline (1:3000) for topical anaesthesia in form of neurosurgical patties were kept in the middle meatus area of lateral wall of nose for 10 minutes.

It was followed by injecting local anaesthesia 2% Xylocaine in 1:20,000 adrenaline in the nasal mucosa around the area of lacrimal Sac. This also helps in vaso constriction and less blood loss during surgery thus giving clear field of vision intra operatively. Anterior end and axilla of middle turbinate was identified. Horizontal Incision was made that run over lateral wall mucosa of nasal cavity, 8-9 mm above the axilla and Extended anteriorly for approximately 1 cm onto the ascending process of the maxilla thus created posteriorly based c shaped mucoperichondrium flap. Ascending process of maxilla, adjacent lacrimal bone and agger nasii

were exposed .Kerrison’s 2 mm punches, up cutting and down cutting were used to remove the bone overlying the lacrimal sac. The bone removal was then continued nasally The NLD was traced superiorly and laterally to identify the lacrimal sac.

Bowman’s probe was used for Lacrimal probing to tent the medial wall of sac after dilating the punctum with punctum dilator. Saline Syringing was done to confirm the free flow and patency, which was observed endoscopically .The lacrimal sac was then slit open. The medial wall of sac was removed.

A Silicon bi-canalicular stent introduced from both the puncta and the inferior free ends were brought out through the nasal cavity. A threaded piece of merocele nasal pack was placed in the in the exposed sac field. Broad spectrum oral antibiotics were given for 7days. Together with ciprofloxacin eye drops and nasal saline drops were prescribed after pack removal for 4 weeks. Nasal pack was removed after 24 hours. Clots and crusts were cleared from nasal cavity in the follow up period. Syringing of lacrimal passage was done at 1 week, 1 month, 2 months, 3 months and six for patency. Patients were instructed to not blow nose during first week after surgery. Stent was kept for a period of 6 weeks. This time allows all the raw surfaces in surgical site to heal. Post operatively regular syringing of the puncta and nasal wash were done and followed up for a period of 6 months and the results were compared. Outcome is considered as failure whenever the patients were subjective symptoms of severe epiphora.

### III. Observation:-

Age and Sex wise Distribution of Cases

**Table No. 1** Patient with endoscopic DCR without stent

Age group	Male	Female	Total
20-29	0	02	02
30-39	05	07	12
40-49	10	13	23
50-59	03	01	04
60-69	01	07	08
70-79	02	04	06
	21	34	55
	38.18	61.8	

**Table No. 2-** Patient with endoscopic DCR with stent

Age group	Male	Female	Total
20-29	01	01	02
30-39	08	12	20
40-49	12	26	38
50-59	02	03	05
60-69	05	07	12
70-79	02	03	05
	30	52	82
	36.58	63.41	

Male to Female Ratio in Patient with endoscopic DCR without Stent –1: 1.67

Male to Female Ratio in Patient with endoscopic DCR with Stent – 1:1.73

There was no statistical difference between the two group ( P>0.05)

Study Out-come :- EEDCR without stent

Total Operative Case – 55

Success Cases – 38 Cases (69.01%)

Failure Cases– 17Cases (30.90%)

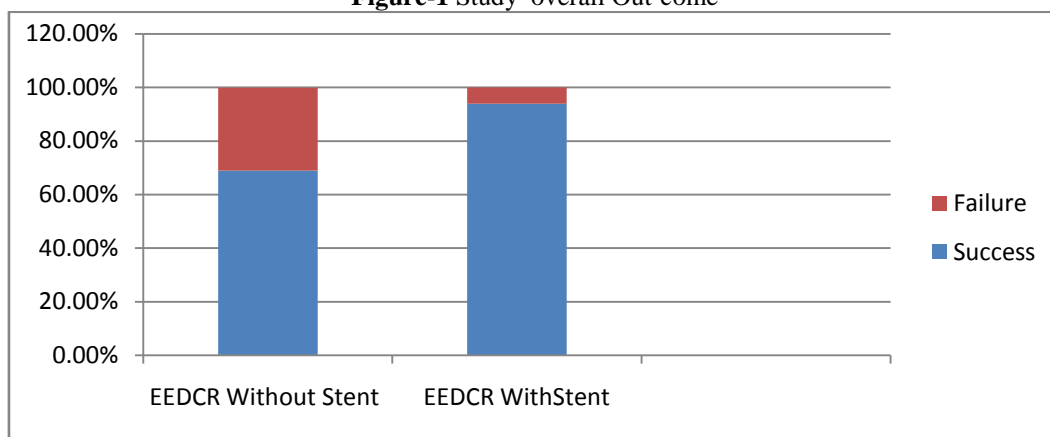
EEDCR with stent: -

Total Operative Case – 82

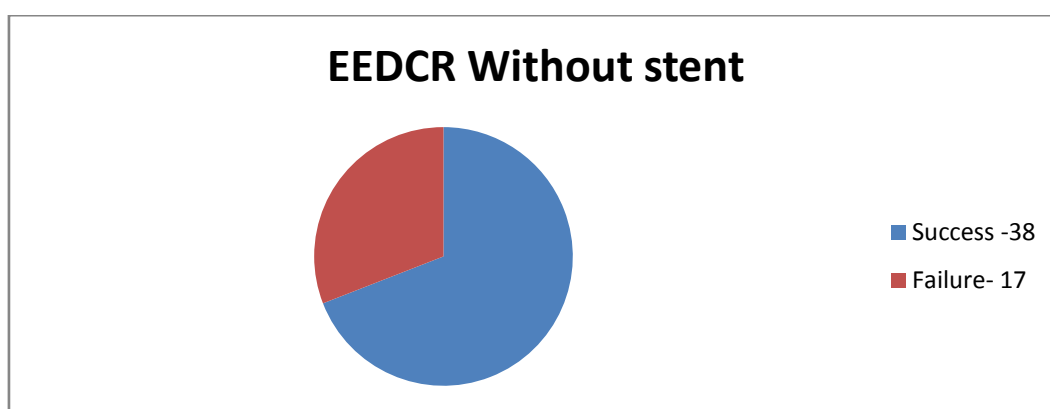
Success Cases – 77 Cases (93.95 %)

Failure Cases – 05 Cases (6.09 %)

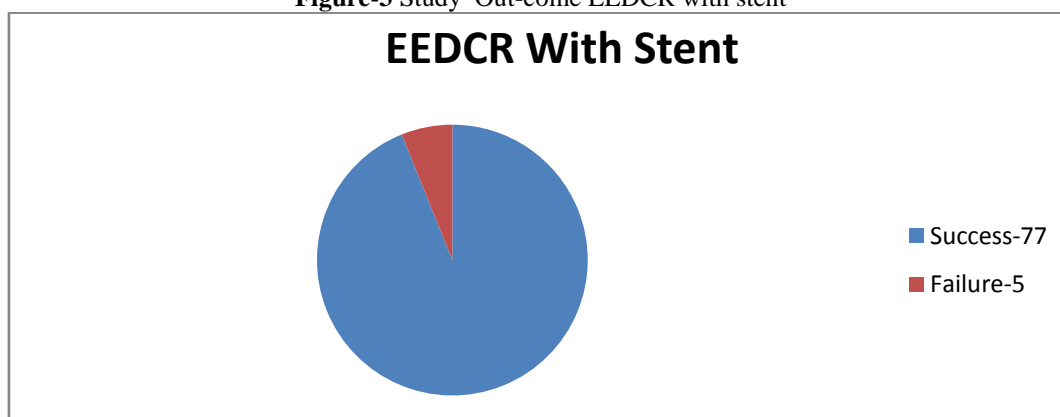
**Figure-1** Study overall Out-come



**Figure-2** Study Out-come EEDCR without stent



**Figure-3** Study Out-come EEDCR with stent



**IV. Results: -**

The current study included 137 patients. Females were predominant in both groups (p values more than .05), with around 63% being females in the group with stenting. Male to female ratio was 1:1.73 and 1:1.67 in the group with stenting and without stenting. Failure rate of surgery was found to be 30.90% in the group without stenting and 6.09% with stenting. The symptomatic success rate of the surgery at the end of 6 months was 94% in the group with stenting and 69% in the group without stenting.

**V. Discussion:-**

The present study included 137 patients presenting with epiphora due to NLD obstruction who were undergone through definite treatment for chronic dacryocystitis by Endonasal endoscopic DCR in Government medical college Ambikapur. Study subjects cater mostly to the rural population.

Endonasal endoscopic DCR surgery is a gold standard in treatment of nasolacrimal duct obstruction, has advantage of direct inspection of lacrimal sac pathology involved ,better cosmetic outcome as well as for immediate correcting mistakes during surgery [9]. In the present study, the patients operated were of mean age of 43.2 years and 44.75 years for Patient with endoscopic DCR with Stent and Patient with endoscopic DCR without Stent respectively.

This indicates that acquired nasolacrimal duct obstruction is more common in middle age group. Similar findings were reported by Gupta *et al*[10] . Moras *et al.* in his study reported maximum incidence in third and fourth decade of life, which is comparable to our study[11] .

In our study females were predominant in both groups, with around 63%being females in group with stenting. Male to female ratio was1:1.73 and 1:1.67 in group with stenting and without stenting. Females have significantly smaller dimensions in lower nasolacrimal duct. Hormonal changes that bring about a generalized de-epithelization in the body may cause the same within the lacrimal sac and duct. An already narrow lacrimal fossa in women predispose them to obstruction by the sloughed of debris. Moreover injudicious use of Kaajal and adulterated cosmetics applied on the wrong side of eyelashes can also play an important role in obstruction of nasolacrimal system.

**Table-3 Male to Female Ratio in similar studies.**

Male to Female Ratio	Present study		Unlu et al[12]		mortimore et al[13]	Naik SM et al[14]	
	with stent	without stent	with stent	without stent	with stent	with stent	without stent
	1:1.73	1:1.67	1:3.7	1:7	1:3.33	1:1.7	1:1.86

The successful outcome of surgery is defined by subjective improvement of symptoms and patency of NLD neo ostium on syringing that's observed in post operative nasal endoscopy. Patency is also maintained by the pumping action of tears by regular contraction of orbicularis oculi muscle while blinking of eyes.

The stent was kept in place for 6 weeks. This time allows the raw surface in surgical site to heal. Hence the remote chance of synechiae formation is ruled out by putting Silicon bi-canalicular stent at operative site. This technique giving 94% success rate.. Kim Proposed theory, explain the effect of silicon tube on the lacrimal pump; first, it controls the punctual position and enhances lacrimal pump function; second, the small canaliculi performance improved in patients who exhibit the narrow capillary phenomenon.

The surgery is reported to be failure if there is no improvement of symptoms and blocked neo ostium indicated by regurgitation of saline on lacrimal syringing .

Failure rate of surgery was found to be 30.90% in group without stenting and 6.09%with stenting. In Endoscopic DCR without stenting the symptoms is recurring because of closure of stoma created between the lateral wall of nose and lacrimal sac. In cases where the stent has been placed intra-operatively, the patency of the lacrimal apparatus is maintained even in post operative. The reasons behind the failure cases in EEDCR with stent is given below in table

**Table- 4 Causes for Failure in EEDCR with stent.**

Reason	No.of Cases
Fibrotic Leccrimal sac	02
Late Infection	01
Postoperative Synechiae formation	01
Very Wide Osteotomy From Previous Surgery	01

The success rate of the surgery at the end of 6 months were 94%in group with stenting and 69% in group without stenting.

In our study, both groups had almost similar rate of complications which was statistically not significant. In present study only intra-operative complication seen was hemorrhage which was seen in 11% cases of endoscopic DCR without Stent and 13.6% cases of endoscopic DCR with Stent. Similar intraoperative complication rate was seen in the study conducted by Cokkeser *et al*[15]. . Duwal and Saiju in their study reported intraoperative bleeding in 6.45% patients of endoscopic DCR[16] . Our results are comparable to Gauba who reported 13% cases of intraoperative haemorrhage in endonasal DCR[17] . The haemorrhage in endoscopic DCR can occur from branches or ethmoidal vessels and from nasal mucosal.

Postoperative case of epistaxis was not seen in both endoscopic DCR group. This corresponds to the study of Moras *et al*[11]. and also similar result in study conducted by Cokkeser *et al.*, zero out of 51 patients in the endoscopic Endonasal group[15] .

Synechiae formation at rhinostomy site between middle turbinate and septum was seen in 1 case in each group and was managed on OPD basis. This can be resulted from the injury caused on the opposing surface of middle turbinate and septum. The decreased incidence of postoperative epistaxis and synechiae formation in endoscopic DCR in our study can be attributed to the use of merocel nasal pack which acts as a haemostatic pack and also local infiltration and topical application of adrenaline helps for vaso constriction haemostatic action.

## VI. Conclusion

Overall success rate of the Endonasal DCR was 94% in group with stenting is more beneficial and gives less post operative morbidity and indicate that lacrimal silicon tube intubation is an effective treatment procedure for patients of chronic dacryocystitis disease with common nasolacrimal duct obstruction.

## References

- [1]. Clemente CD (ed) (1985) Gray's anatomy of the human body, 30th edn. Lea and Febiger, Philadelphia
- [2]. Kassel EE and Schatz CJ (1996) Lacrimal apparatus chapter 10. In: Som PM, Curtin HD (eds) Head and neck imaging, vol 3, Mosby St., Louis, pp 1129–1183, [www.similima.com/books/anatomybooks/anatomybook33.pdf](http://www.similima.com/books/anatomybooks/anatomybook33.pdf)
- [3]. Bartlett JD, Jaanus SD (2008) Clinical Ocular pharmacology. Butterworth-Heinemann/Elsevier, St. Louis
- [4]. Saha R, Sinha A, Phukan JP. Endoscopic versus external approach dacryocystorhinostomy: A comparative analysis. *Niger Med J.* 2013; 54:165-9.
- [5]. Welham RA, Henderson PH. Results of dacryocystorhinostomy. Analysis of causes for failures. *Trans Ophthalmol Soc UK.* 1973; 93:601–9.
- [6]. Toti A. Nuovo metodo conservatore di cure radicale della suppurazioni croniche del sacco lacrimale (dacriocistorhinostomia) *Clin Moderna Firenze.* 1904;10:385
- [7]. McDonogh M, Meiring JH. Endoscopic transnasal dacryocystorhinostomy; *J Laryngol Otol.* 1989 June; 103(6): 585-587.
- [8]. Okuyucu S, Gorur H, Oksuz H, Akoglu E. Endoscopic dacryocystorhinostomy with silicone, polypropylene, and T-tube stents; randomized controlled trial of efficacy and safety. *Am J Rhinol Allerg.* 2015;29(1):63-8.
- [9]. Zhou W, Zhou M, Li Z, Wang T. Endoscopic intranasal dacryocystorhinostomy in fortyfive patients. *Chin Med J (Engl).* 1996; 109:747-8.
- [10]. Gupta S, Goyal R, Thakur AS, Singh H. Conventional dacryocystorhinostomy versus endonasal dacryocystorhinostomy-a comparative study. *People's J Scientific Res.* 2008; 1:1-4.
- [11]. Moras K, Bhat M, Shreyas CS, Mendonca N, Pinto G. External dacryocystorhinostomy versus endoscopic dacryocystorhinostomy: a comparison. *J Clin Diagn Res.* 2011; 5:182-6.
- [12]. Unlu HH, Toprak B, Aslan A, Guler C. Comparison of surgical outcomes in primary endoscopic dacryocystorhinostomy with and without silicone intubation. *Ann Otol Rhinol Laryngol.* 2002;111(8):704-9.
- [13]. Mortimore S, Banhegy GY, Lancaster JL, Karkanevatos A. Endoscopic dacryocysto-rhinostomy without silicone stenting. *J Royal Coll Surg Edinburgh.* 1999;44(6):371-3.
- [14]. Naik SM, Mushannavar AS, Ravishankara S, Appaji MK, Goutham M, Devi NP, et al. Endonasal Dacryocystorhinostomy done with and without Silicon Tube Stents: A Comparative Case Series Analysis Study. *Head Neck Surg.* 2012;3(3):147-53.
- [15]. Cokkeser Y, Evereklioglu C, Hamdi E. Comparative external versus endoscopic dacryocystorhinostomy: results in 115 patients (130 eyes). *Otolaryngol Head Neck Surg.* 2000; 123(4):488-91.
- [16]. Duwal S, Saiju R. Outcomes of external and endoscopic dacryocystorhinostomy. *Nepal J Ophthalmol.* 2015; 7(13):39-46.
- [17]. Gauba V. External versus endonasal dacryocystorhinostomy in a specialized lacrimal surgery center. *Saudi J Ophthalmol.* 2014; 28:36-9.

Dr Shailendra Gupta. “A Retrospective Analysis of 137 Chronic Dacryocystitis Cases Treated with Endonasal Endoscopic Approach to Dacryocystorhinostomy with and Without Silicon Stent”. *IOSR Journal of Dental and Medical Sciences (IOSR-JDMS)*, vol. 18, no. 9, 2019, pp 23-28.