

## Myofibroma—A Rare Entity with Masquarading Clinical Presentation

Dr. Jesmith Elsa Jacob<sup>1</sup>, Dr. Asish Rajasekharan<sup>2</sup>, Dr. Tinky Bose. C<sup>3</sup>,  
Dr. K.L. Girija<sup>4</sup>, Dr. Nabeel A.K.<sup>5</sup>, Dr. Vinimol. C.<sup>6</sup>

<sup>1</sup>(Senior Resident, Department of Oral Medicine & Radiology, Government Dental College, Alappuzha, Kerala, India)

<sup>2</sup>(Associate Professor & Head, Department of Oral Medicine & Radiology, Government Dental College Alappuzha, Kerala, India)

<sup>3</sup>(Professor & Head, Department of Oral Medicine & Radiology, Government Dental College, Thiruvananthapuram, Kerala, India)

<sup>4</sup>(Associate Professor, Department of Oral Medicine & Radiology, Government Dental College, Thiruvananthapuram, Kerala, India)

<sup>5</sup>. (Senior Resident, Department of Oral Medicine & Radiology, Government Dental College, Thrissur, Kerala, India)

<sup>6</sup>(Assistant Professor, Department of Pharmacology, Government Medical College, Kollam, Kerala, India)

---

**Abstract:** Myofibroma and myofibromatosis is a well-recognized spindle cell neoplasm that occurs predominantly in infants and young children. They have been described under different names since 1951. These lesions are a benign fibroblast and myofibroblast proliferation containing a biphasic presentation of spindle shaped cells, surrounding a central zone of less differentiated cells focally arranged in a hemangiopericytoma like pattern. Classically these lesions are described in children younger than two years, with 2/3rd present at birth and rarely in adults. Controversy exists as to an autosomal dominant or recessive inheritance or to a sporadic occurrence. Presented here is a unique case of myofibroma involving the mandible in a 47 year-old male patient. Clinically it mimicked more like a consolidated abscess and not exhibiting any of its classical signs. The diagnosis could be established only after complete excision of the lesion and histopathological examination. There was no recurrence after a follow up period of 4 months.

**Keywords:** Myofibroma, Spindle cell neoplasm, Smooth muscle

---

Date of Submission: 26-08-2019

Date of Acceptance: 10-09-2019

---

### I. Introduction

Myofibroma is a benign tumor composed of myoid spindle cells arranged around thin-walled blood vessels. Myofibromas are classified as either a solitary or multicentric type.<sup>1</sup> The tumor may present as single or multiple nodules. The solitary type is called myofibroma, whereas the multicentric type is known as myofibromatosis.<sup>2</sup> The majority of myofibromas present in children less than 2 years of age.<sup>3</sup> Approximately half of myofibromas occur in the cutaneous and subcutaneous tissues of the head and neck region, followed by the trunk and the extremities. The other half occur in skeletal muscle or aponeuroses. The prevalence of myofibroma in the oral cavity is very low, and the mandible is recognized as the most common site followed by the tongue and buccal mucosa.<sup>4</sup> In 1951, Williams and Schrum<sup>5</sup> first named the lesion as congenital fibrosarcoma, subsequently Stout<sup>6</sup> amended term to congenital generalized fibromatosis following a study of fibrous growth in children. These terms were used to denote a multicentric and multinodular benign fibroblastic process composed of spindle cells. In 1965, Kauffman and Stout<sup>7</sup> divided this tumor into two types: those with a good prognosis that affect the skin, subcutaneous tissue, or skeleton; and those with a poor prognosis that affect the soft tissue, muscles, bones, or internal organs.<sup>2</sup> In 1981, Chung and Enzinger<sup>3</sup> at the US Armed Forces Institute of Pathology studied 61 cases of both solitary and multicentric types and renamed the lesion as infantile myofibromatosis to indicate its myofibroblastic nature and its predilection for infants finally. In 1989 Smith et al. and Daimaru et al. reformed to the solitary variant in adults using the term myofibroma and myofibromatosis, respectively. The latter terms have been adopted by the WHO to describe solitary (myofibroma) or multicentric (myofibromatosis) benign neoplasm.<sup>7</sup> The exact etiology of the condition is unknown with most cases reported as sporadic, however some reported cases suggest the possibility of a familial pattern of inheritance suggesting that myofibromatosis may be inherited as an autosomal dominant or recessive trait. These lesions can occur over a wide age range with many occurring in the 1st decade of life, according to some authors, 90% of cases manifest before the age of 2 years. The solitary form (myofibroma) occurs most often in the dermis and subcutis, with head and neck accounting for a majority of the lesions. Reported here is a unique case report of a patient with a slow growing lesion in the left side of the mandible extraorally. Therefore, there are few reports of adult cases

of oral myofibroma. The case is unique in clinical aspect. Ultrasound features were non suggestive of a myofibroma and initial incisional biopsy could not establish the diagnosis. It was only after complete excision of the lesion followed by post operative histopathology that a diagnosis of myofibroma was established. Through this paper, we emphasize the diagnostic value of USG.

## **II. Case Report**

A 47 year old male patient presented to the Oral Medicine & Radiology, OPD with swelling on left side of face for 3 months. Swelling was of primary incidence, insidious onset and had gradually increased to the present size over three months. He experienced restriction in opening mouth since one month for which he consulted a Taluk hospital two weeks back and was prescribed antibiotics that provided with reduction in the size of the swelling. As considerable resolution in the size was not observed, he was referred to our setup for further management. His medical history & family history were unremarkable. On extraoral examination, (Figure 1) there was a diffuse swelling of size 4 x 5 cm, over the region of the left body of mandible, anterior to left masseter and was associated with mild trismus. Palpation revealed a non-tender firm swelling. Swelling was non-mobile, non-compressible, non-reducible, and non-pulsatile. However there weren't any significant findings on intraoral examination (Figure 2). Based on these findings, a provisional diagnosis of Benign soft tissue neoplasm was arrived. Panoramic radiograph (Figure 3) and mandibular occlusal view did not reveal any significant findings. Ultrasonographic examination (Figure 4) revealed a well-defined hypoechoic area with irregular border immediately anterior to left masseter with irregular hyperechoic internal streaks within the lesion. Left masseter, parotid and submandibular glands appeared sonographically normal. Enlarged left level Ib lymph node seen with retained hilum. On CT Imaging of Maxillofacial Region (Figure 5) with 3D Imaging (Plain and Contrast): Well defined soft tissue dense mass lesion adjacent to the left mandibular alveolus at the level of 3rd molar tooth with moderate homogenous enhancement and significant cortical erosion along the outer aspect of left mandibular alveolus without any involvement of the alveolar canal. The fat plane between the lesion and the cervical fascia remains intact. The retromandibular vein was seen coursing anterior to the lesion. Cytology WFPS smear showed few salivary acinar cells interspersed with scattered lymphocytes in background of blood.

H and E stained section (Figure 6) revealed intertwining bundles of spindle cells with abundant extracellular collagenous matrix & groups of densely packed cells adjacent to angular hemangiopericytoma like blood vessels.

Immunohistochemistry (Figure 7) revealed SMA and Vimentin positivity and negative reaction for S 100. Bundles of lesional spindle cells were intensely positive for alpha-smooth muscle actin. These findings were consistent with the diagnosis of myofibroma. The postoperative course was uneventful.

## **III. Discussion**

There are few reports of adult patients with myofibroma of the mandible. Myofibroma (unifocal) and myofibromatosis (multifocal) are rare spindle cell neoplasms composed of myofibroblasts, i.e., cells with characteristics intermediate between smooth muscle, fibroblasts, and undifferentiated cells.<sup>8</sup> These lesions typically appear in children and infants. Nonetheless both solitary and multicentric lesions can occur at any age. In adults the solitary lesion is the most common form. Clinically these lesions show a predilection for the head and neck, with the oral lesions typically presenting in the mandible, lips, cheek, and tongue.<sup>1</sup> These lesions can occur over a wide age range with many occurring in the 1st decade of life, according to some authors, 90% of cases manifest before the age of 2 years. The solitary form was more common in males (69%), primarily affecting the tissues of the head, neck, and trunk.<sup>7</sup> The multicentric form was more common in females (63%), being found in the soft tissues, skeleton, and viscera.

In the present case, the preoperative diagnosis based on the biopsy specimen findings was a myofibroblastic tumor, probably benign. However, the tumor grew rapidly in a few weeks. In the oral and maxillofacial region, approximately one-fourth of cases of myofibroma exhibit rapid enlargement, and some lesions show accelerated growth after incisional biopsy.

Myofibroma of the mandible is a tumor typically diagnosed in children (mean 7.2 years, median 6 years), usually in the first decade of life, with a definite male predominance (male/female ratio 2.3:1).<sup>8</sup> These features vary considerably from those presented by the myofibroma of the oral mucosa, which is usually diagnosed in an older age group (mean 21.7 years, median 13 years) with a female predominance (1.6:1).

The exact etiology of the condition is unknown with most cases reported as sporadic, however some reported cases suggest the possibility of a familial pattern of inheritance suggesting that myofibromatosis may be inherited as an autosomal dominant or recessive trait. The solitary form (myofibroma) occurs most often in the dermis and subcutis, with head and neck according for a majority of the lesions. On gross examination, these lesions present as firm circumscribed non encapsulated nodules, often with lobulation. Histologically, interlacing bundles of spindle cells with tapered and blunt ended nuclei and eosinophilic cytoplasm suggest

smooth muscle and fibroblast differentiation. A biphasic or zonation pattern is commonly seen composed of nodular fascicles of spindle cells surrounding cellular zones of undifferentiated cells with small round basophilic nuclei. The latter exhibit scattered normal mitotic figures and are organized in central vascular hemangiopericytoma—like areas.<sup>4</sup> Immunohistochemical studies reveal positivity for smooth muscle actin, muscle specific actin (HHF 35), vimentin and pac-actin whereas desmin, S-100, epithelial membrane antigen, and cytokinin are negative.<sup>7</sup>

Treatment of myofibroma of the mandible was usually conservative excision (75%). In only a few cases (25%), an aggressive surgical procedure of segmental jaw resection was performed to remove extensive and destructive tumors.

Pharmacological agents that have been used with a fair degree of clinical success in another more aggressive myofibroblastic lesion, the fibromatoses, are the selective estrogen receptor modulators, i.e., tamoxifen, raloxifene, and toremifene.<sup>9</sup> Their mechanism of action on myofibroblasts is not dependent on the presence of estrogen receptors. It is proposed that in the future, these agents, either alone, or in combination with limited surgery, be used in cases of large and destructive myofibroma of the mandible. In summary, myofibroma of the mandible is a typical tumor of childhood and adolescents located solely in the mandible. Increased awareness of the presence of myofibroma within the mandible may lower the possibility of inaccurate diagnoses. Treatment of choice for myofibroma is local excision. In the case presented here, the lesion appeared clinically as a benign tumor with no clinical, radiological or histological evidence of myofibroma and was treated by excision with no recurrence till to date. Both periapical, occlusal and OPG were used to show the extent of the involvement and aided us in successful complete resection. It was only in post op histopathology that a correct diagnosis of a myofibroma could be established. The rarity of the lesion lead to misdiagnosis initially, There are few reports of adult patients with myofibroma of the mandible. Clinical differences between adults and pediatric patients with myofibroma have suggested that pediatric patients are likely to demonstrate bone involvement and that lesions in adults almost invariably presented as the solitary form, with exceptional cases of the multicentric form. However, no specific differences in histologic features between adult and pediatric patients have been reported.

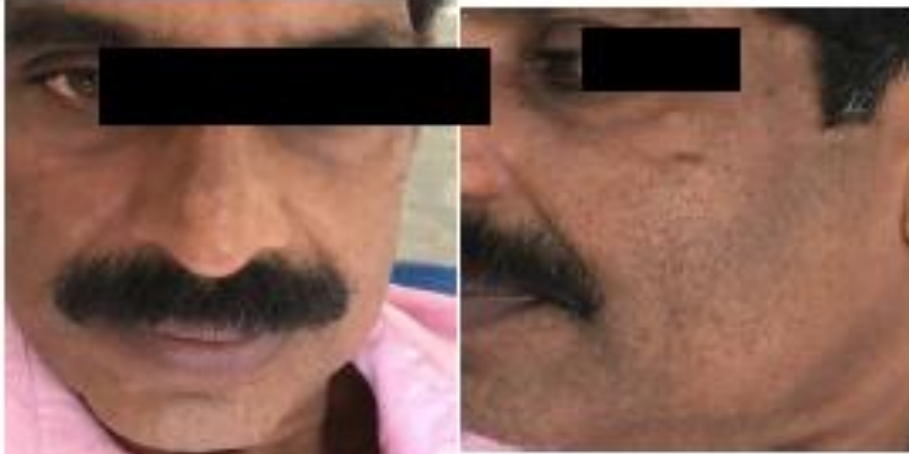The clinical features of our solitary case without bone destruction are in accordance with those of adult oral myofibroma. To avoid unnecessarily aggressive surgery, the clinician should be aware that myofibroma could show false positive results in a PET study aiming for detection of malignant tumors. Recurrence is rare, and such cases are usually controlled with reexcision. To avoid unnecessarily aggressive surgery, the clinician should be aware that myofibroma could show false positive results in a PET study aiming for detection of malignant tumors. Although a preoperative specific diagnosis of myofibroma could not be established in our case, clinical findings in combination with MRI and PET could narrow down the differential diagnoses. Complete local excision is performed for the treatment of solitary myofibroma. Recurrence is rare, and such cases are usually controlled with re-excision. In the present case, the tumor was completely removed by marginal resection of the left mandible and we found no evidence of recurrence at the postoperative 34-month follow-up.

Conclusions In this report, we described an adult case of myofibroma that arose on the mandible and discussed the diagnostic value of preoperative MRI and PET findings.

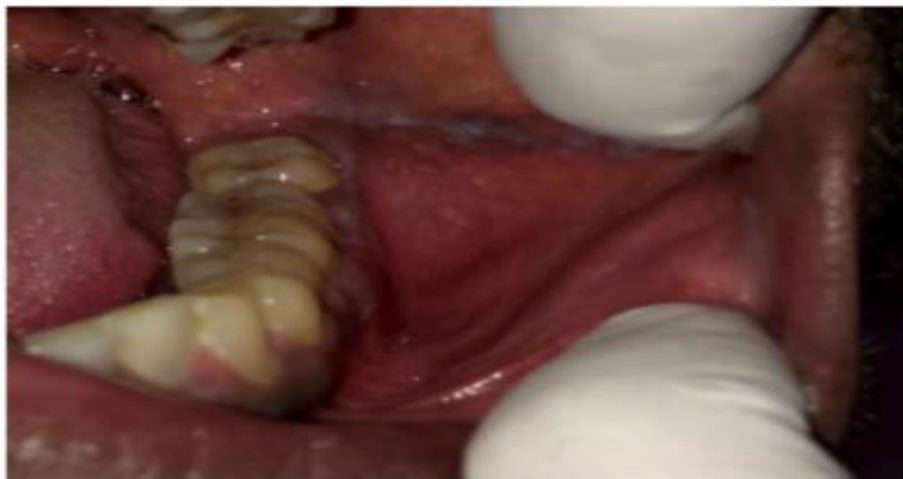### References

- [1]. Fletcher CDM, Unni KK, Mertens F editor. L. Myofibroma/myofibromatosis; Int Agency Res Cancer. 2002;59–61.
- [2]. Kanfman SL SA. Congenital mesenchymal tumors. Cancer. 1965;(18):460–476.
- [3]. Chung EB EF. Infantile myofibromatosis. Cancer. 1981;(48):1807–1818.
- [4]. Neville BW, Damm DD, Allen CM BJ. Oral and Maxillofacial Pathology. 2nd ed. Philadelphia: WB.; Saunders Co.; 2004.
- [5]. WILLIAMS, J. O., and SCHRUM D. Congenital fibrosarcoma; report of a case in a newborn infant. A ill A Arch Path. 1951;(51):548–52.
- [6]. AP: S. Fibrosarcoma in infants and children. Cancer. 1962;(15):1028–40.
- [7]. Daimaru Y, Hashimoto H EM. Myofibromatosis in adults (adult counterpart of infantile myofibromatosis). Am J Surg Pathol. 1989;(13):859–865.
- [8]. Slootweg PJ MH. Localized infantile myofibromatosis: report of a case originating in the mandible. J Maxillofac Surg. 1984;(12):86–89.
- [9]. Sahin AA, Ro JY, Ordonez NG et al. Myofibroblastoma of the tongue. Am J Clin Pathol. 1990;(94):773–777.

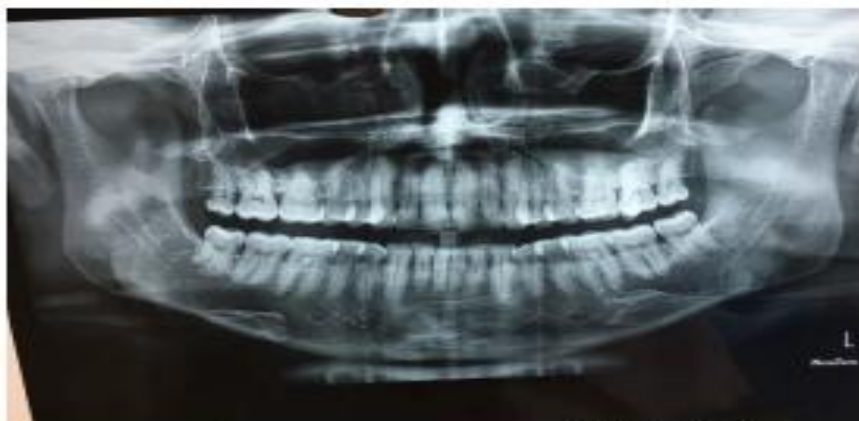**LIST OF FIGURES**



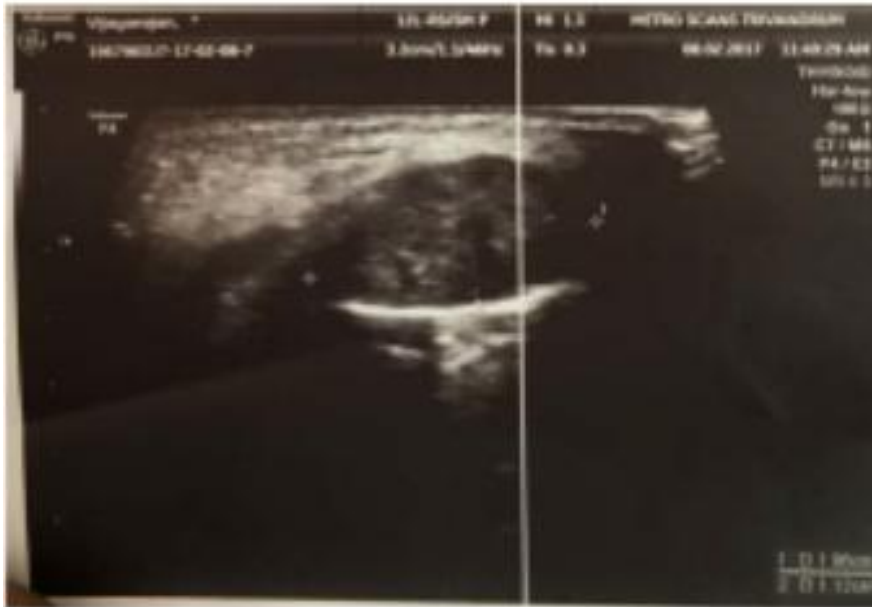
**Fig 1** :Extraoral photograph showing diffuse swelling anterior to left masseter



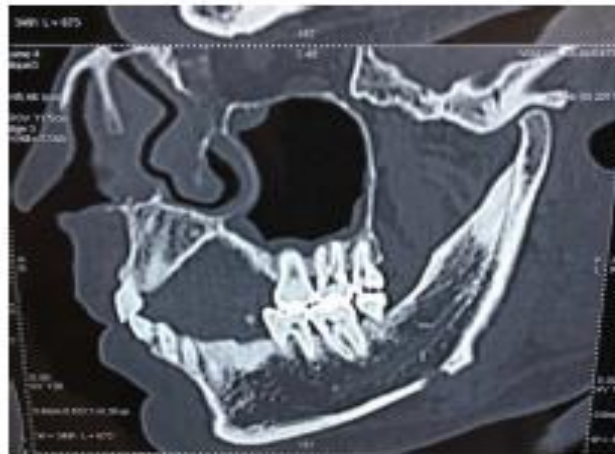**Fig 2** :Intraoral photograph



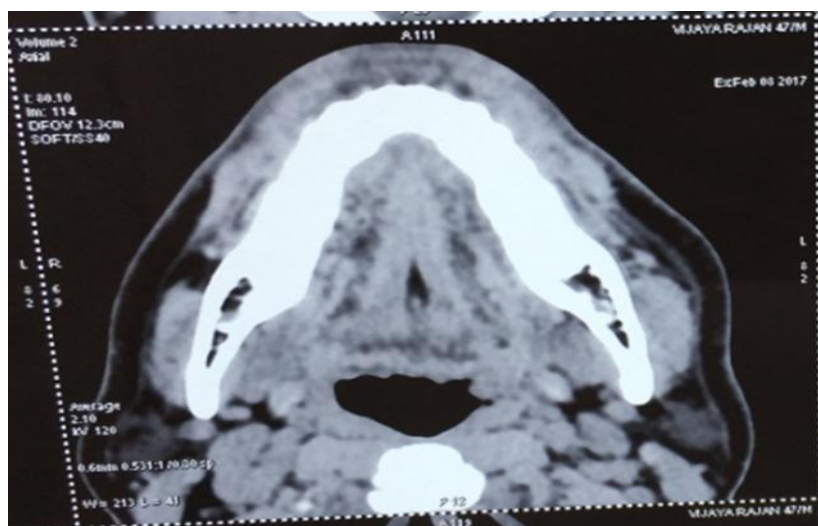
**Fig 3** : Panoramic radiograph



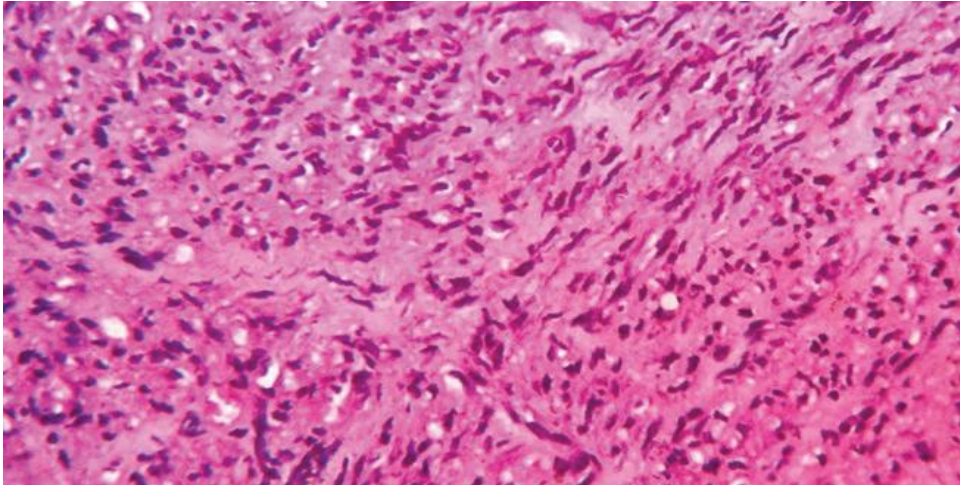
**Fig 4 : USG :** Well defined hypoechoic area with irregular border noted extending to left body of mandible immediately anterior to left masseter with irregular hyperechoic internal streaks within the lesion.



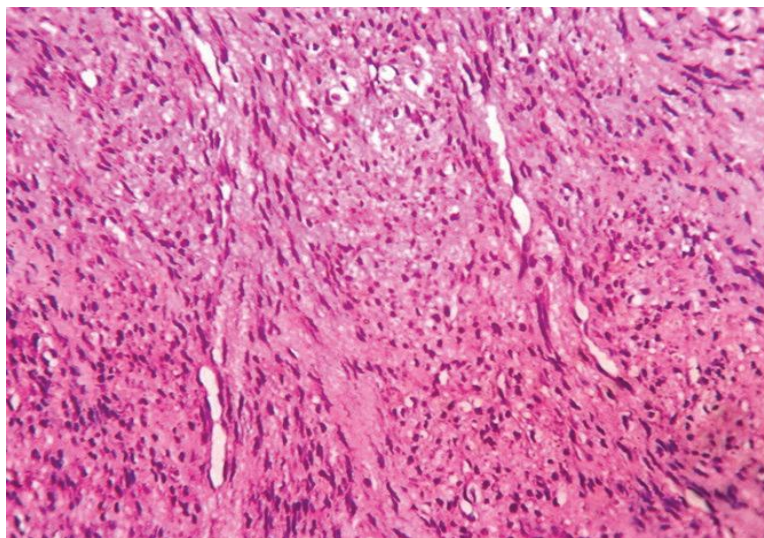
**Figure 5(a) :** CECT: Significant cortical erosion along the outer aspect of left mandibular alveolus.



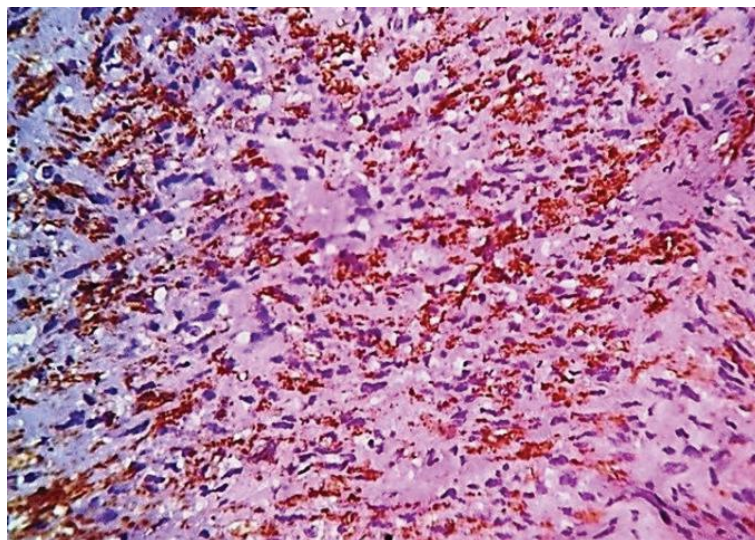
**Figure 5 (b) :** Well defined soft tissue density mass lesion with moderate homogenous enhancement



**Figure 6 (a):** H and E stained section showing intertwining bundles of spindle cells with abundant extracellular collagenous matrix (H&E stain, original magnification  $\times 40$ ).



**Figure 6 (b):** Groups of densely packed cells adjacent to angular hemangiopericytoma-like blood vessels. (H&E stain, original magnification  $\times 40$ ).



**Figure 7:** Immunohistochemistry SMA and Vimentin positivity and negative reaction for S 100 Bundles of lesional spindle cells intensely positive for alpha-smooth muscle actin (original magnification  $\times 40$ ).