

## Expression of AMACR ( $\alpha$ -Methylacyl CoA racemase) in Prostatic Lesion.

Dr.L.Arthi<sup>1\*</sup>, Dr.A.Dhanalakshmi<sup>2</sup>

<sup>1</sup>Assistant Professor, MD Pathology, Dept. Pathology, Govt. Dharmapuri Medical College, Dharmapuri, Tamil Nadu

<sup>2</sup>Associate Professor, MD Pathology, Dept. of Pathology, Coimbatore Medical College, Coimbatore, Tamil Nadu

\*Corresponding Author: Dr.L.Arthi

**Abstract:** Prostate cancer is the second most common cause of cancer and the sixth leading cause of cancer death among men worldwide. To diagnose prostate cancer, no specific single histologic feature is sufficiently available. It is a challenging task to accurately diagnose small foci of prostate cancer for pathologists and to distinguish cancer from its benign mimickers. Establishing a definitive diagnosis of malignancy in prostate needle biopsies with very little foci of adenocarcinoma is a major diagnostic challenge for pathologists. A positive diagnostic marker specific for prostatic adenocarcinoma may enhance the ability to detect limited prostate cancer and reduce errors in diagnosis. The recent discovery of the overexpression of P504S/ $\alpha$ -Methylacyl coenzyme A racemase (AMACR) in prostate cancer is a successful example of translating an advanced molecular finding into clinical practice. AMACR (P504S) has been proven to be one of the few biomarkers that can help distinguish cancer from benign cells, with high sensitivity and specificity for prostate carcinoma. This study focuses on the study of AMACR (P504S) expression in prostate cancer, premalignant lesions, benign prostate tissues, and other normal and malignant tissues and a discussion of its clinical usefulness. We recommend the interpretation of the AMACR immunohistochemical results in routine surgical pathology practice and also discuss the potential future applications of this marker in diagnosis of various lesions

**Key words:** Prostate cancer, AMACR, Immunohistochemistry, Basal cell marker

Date of Submission: 09-09-2019

Date of Acceptance: 25-09-2019

### I. Introduction

Prostate cancer is the second most common cause of cancer and the sixth leading cause of cancer death among men worldwide. The worldwide Prostate cancer burden is expected to grow to 1.7 million new cases and 499 000 new deaths by 2030 simply due to the growth and aging of the global population.<sup>1</sup> To diagnose prostate cancer; no specific single histologic feature is sufficiently available. It is a challenging task to accurately diagnose small foci of prostate cancer for pathologists and to distinguish cancer from its benign mimickers. The diagnosis of prostatic cancer is based on a combination of architectural, cytological and ancillary features rather than any single diagnostic feature none of which is absolutely sensitive and specific. Accurate tissue diagnosis can be very challenging due to the presence of either a small focus of cancer or due to the presence of many benign mimickers of malignancy like adenosis, sclerosingadenosis, atrophy, partial atrophy, basal cell hyperplasia, clear cell cribriform hyperplasia, post atrophic hyperplasia, nephrogenic adenoma, mesonephric hyperplasia, radiation atypia, seminal vesicle and cowpers glands.<sup>2,3,4</sup>

Wrong diagnosis leads to serious issues, like radiation induced adverse effects, prostatectomies done unnecessarily because of false positive diagnosis. Also, false negative results lead to delay in early effective treatment. Hence, definitive diagnosis with the available specimen is essential for the benefit of patients.

Benign glands contain basal cells, which are absent in cancerous glands and hence the basal cell markers are used to label the basal cells<sup>5, 6</sup> which is being used to diagnose prostate cancer. More recently a positive marker for prostate carcinoma,  $\alpha$ -Methylacyl CoA racemase (AMACR) has been reported to have sensitivity ranging from 82-100%.<sup>7</sup> which help to confirm the diagnosis when small atypical glands are identified by routine H&E staining

### II. Materials and Method

A prospective study at Coimbatore Medical College hospital was conducted from August 2011 to July 2012. A sample of 37 cases was taken up for the study. Based on case records, clinical data were collected including age, presenting complaints, digital rectal examination (DRE) findings, serum PSA levels and clinical

diagnosis. Among 37 cases 29 needle biopsies and 8 TURP (Trans Urethral Resection of Prostate) specimens were analysed.

The following inclusion and exclusion criteria were adopted in selecting the samples

**Inclusion criteria-**

1. All prostatic specimens- needle biopsies, TURP- transurethral resection of prostate and radical prostatectomy specimens.
2. Patients in all age groups

**Exclusion criteria-**

1. Ill fixed samples
2. Inadequate sample

The received samples were fixed in 4% formalin, embedded in paraffin and stained with H&E. After Eosin and Haematoxylin staining all slides were reviewed by pathologists and assigned to the following groups - Benign prostatic hyperplasia (10), Basal cell hyperplasia(1), PIN(5), Malignant (20) and suspicious (1). Numbers in parenthesis denote number of cases.

**III. Procedure and Methodology**

The blocks from control and selected cases were cut and mounted on poly l- lysine coated glass slides. Blocking of endogenous peroxidase activity was done by 0.3% hydrogen peroxide in methanol, freshly prepared, for twenty minutes. Then, epitope retrieval by heat was performed by using buffer of Tris EDTA at pH 9. Immunohistochemistry was done by rabbit monoclonal anti-AMACR antibody (p504 S, clone no 13H4 of 1:50 dilution).

Tumor cells were scored positive if there was golden brown cytoplasmic, nuclear or membrane staining in the neoplastic cells. Negative diagnosis was made when no golden brown staining was noted.

**Interpretation of Immunohistochemistry:**

**Criteria for positive/ negative staining for AMACR<sup>8</sup>**

Positive staining refers to granular or dark diffuse, luminal or cytoplasmic staining. The percentage positivity was graded between 0+ and 3+ as below:-

- negative (0+, 0% cells)
- mild (1+, 5-10% cells)
- moderate (2+, 11-50% cells)
- strong (3+, 51% cells)

Negative staining refers to focal or no staining, fine or weak and partial or non-circumferential staining.

**IV. Results**

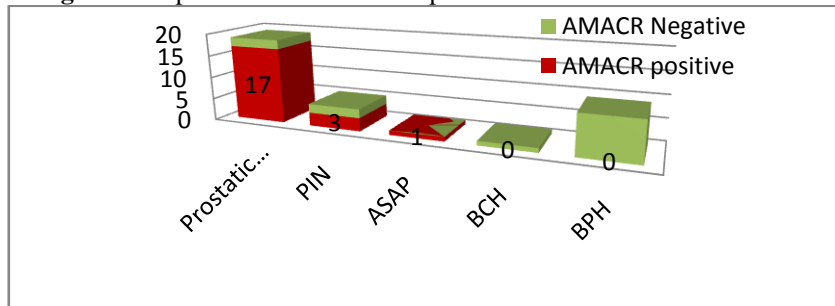
A total of 37 cases were selected as per inclusion and exclusion criteria. Among 37 cases 19 were prostatic cancer, 5 were prostatic intraepithelial neoplasia, 1 case was atypical foci, and 9 were benign prostatic hyperplasia cases. 17 out of 19 cases categorised as prostatic carcinoma showed moderate to strong positive cytoplasmic staining of AMACR in malignant areas, but it did not positive staining in any benign glands. 2 out of 19 cases of prostatic carcinoma showed negative staining with AMACR. 3 out of 5 cases categorised as prostatic intraepithelial neoplasia showed focal, weak and granular cytoplasmic positivity with AMACR. Compared to prostate cancers, a weaker intensity of AMACR expression was noted in high grade PIN cases. One case categorised as ASAP, showed positive staining in luminal cells by AMACR. All the 9 cases of benign prostatic hyperplasia showed negativity for AMACR. (Table 1). The AMACR expression among the slides studied is given in Figure 1.

**Table no 1- Expression of AMACR in various Prostatic Lesions**

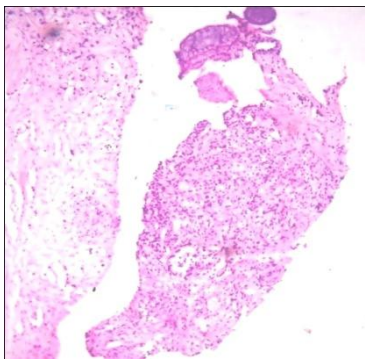
Prostatic Lesions	No. of cases	AMACR positive	AMACR Negative
Prostatic Carcinoma	19	17	2
PIN	5	3	2
ASAP	1	1	0
BCH	1	0	1
BPH	9	0	9

- BPH - Benign Prostatic Hyperplasia
- BCH - Basal Cell Hyperplasia
- PIN - Prostatic Intra epithelial Neoplasia
- ASAP - Atypical Small Acinar Proliferation

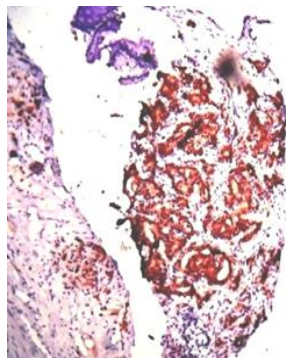
**Figure 1.** Expression of AMACR expression in various Prostatic Lesions



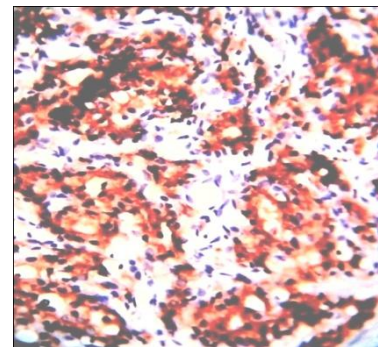
The immunohistochemical profile of AMACR expression in prostate carcinoma is given in Figures 2, 3, 4



**Figure.2.** H&E shows High grade carcinoma of Prostate in needle biopsy.10X

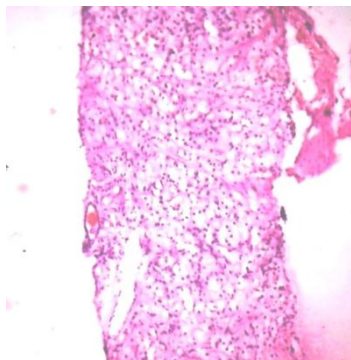


**Figure.3.** AMACR shows diffuse, strong positivity of malignant foci in Carcinoma of Prostate.10X

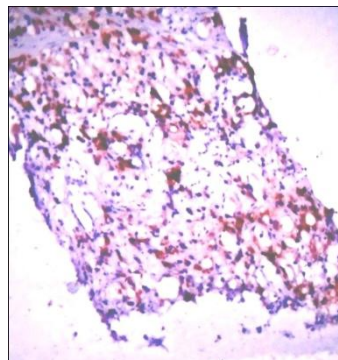


**Figure.4.** AMACR shows diffuse, strong and granular positivity of Carcinoma of Prostate in needle biopsy.40X

Signet ring carcinoma constitutes 25 % or more of tumor mass consisting of signet-ring-appearing cells, this histologic variant is a rare entity with less aggressive clinical course. Microscopically, the signet ring-like tumor cells display displacement of nuclei and clear cytoplasmic vacuolar indentation. In majority of cases, these vacuoles contain lipid rather than mucin, as with true signet cells. The cancer cells grow as single cells, in small clusters and in sheets as shown in Fig.5,6.

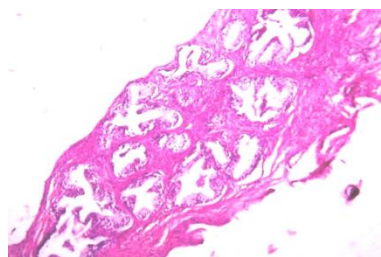


**Figure.5.** H&E Signet ring carcinoma of Prostate.10X

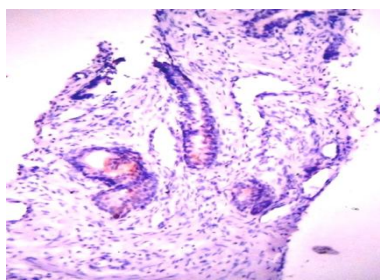


**Figure.6.** AMACR shows strong and granular cytoplasmic positivity in Signet ring carcinoma of Prostate.10X

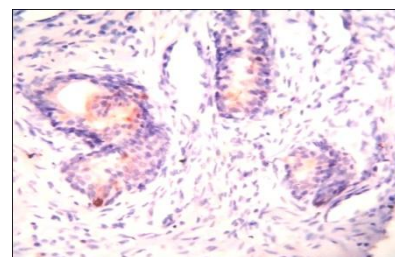
The immunohistochemical profile of AMACR expression in prostatic intraepithelial neoplasia is given in Fig.7,8,9 and benign prostatic hyperplasia showing negativity is shown in Fig.10



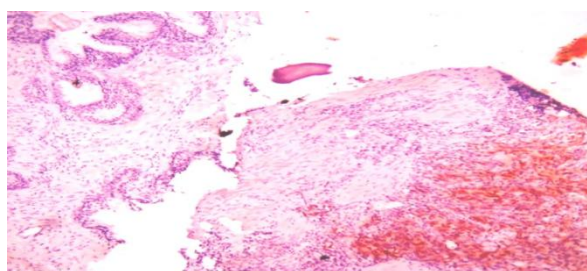
**Figure.7.**H&E. Low grade Prostatic Intraepithelial Neoplasia.10X



**Figure.8** Weak & Non-circumferential positivity of AMACR in luminal epithelial cells in Prostatic Intraepithelial Neoplasia.10X



**Figure.9.** Weak & Non-circumferential positivity of AMACR in luminal epithelial cells in Prostatic Intraepithelial Neoplasia.40X



**Figure.10.** Granular & Strong cytoplasmic positivity of AMACR in malignant cells & its absence in adjacent benign glands in Prostatic carcinoma.10X

## V. Discussion

Prostate carcinoma is the most common form of extra cutaneous cancer in men and the second leading cause of death<sup>9</sup>. The wide use of serum prostate-specific antigen (PSA) screening has resulted in an increased detection of patients with prostate cancer.<sup>10</sup> Tissue examination of a prostate needle biopsy or transurethral resection specimen of prostate is mandatory for the diagnosis of prostate cancer and permits patients to receive appropriate therapy.

However, tissue diagnosis can be difficult and inaccurate if the cancer is very limited, because the establishment of a pathologic diagnosis requires the presence of a combination of multiple histologic features of tumor cells such as pattern of growth, nuclear atypia, absence of basal cells, and the presence of characteristic extracellular material in malignant glands.<sup>11-13</sup> PSA is the most commonly used biomarker for the diagnosis and the prediction of prognosis in prostate cancer.<sup>14</sup> With the major effort in the early detection of prostate cancer by mass screening of men, there have been an increasing number of small foci of cancer encountered on prostate needle biopsy specimens. The diagnosis of these small foci of prostate cancer in needle biopsy specimens is one of the major diagnostic challenges in surgical pathology. Under diagnosis of a small focus of prostatic adenocarcinoma or the over diagnosis of a benign lesion mimicking cancer is not uncommon and can cause unfortunate consequences. Prostate cancer diagnosis is usually made using histological, traditional parameters, not with any single diagnostic feature. They include nuclear features, tissue architecture and other features. In needle biopsies, tissue diagnosis of prostatic carcinoma is difficult. This is because of either the many benign mimickers of malignancy or a small focus of cancer. With the major effort in the early detection of prostate cancer by mass screening of men, there have been an increasing number of small foci of cancer encountered on prostate needle biopsy specimens.<sup>15</sup> It has been shown that using  $\alpha$ -methylacyl coenzyme A racemase (AMACR, or P504S) as a positive marker can help to confirm the diagnosis when small atypical glands are identified by routine H&E staining.<sup>16</sup>

AMACR is an enzyme involved in the intermediates of bile acid metabolism and metabolism of fatty acids (branched-chain). It is overexpressed in the most of prostate cancers<sup>17</sup>. Because of its intratumoralheterogenous patterns of expression, in only eighty percent of cancers, AMACR is positive. Numerous prostate carcinoma histologic variants, such as atrophic, foamy gland, and psedohyperplastic prostate carcinoma, exhibit decreased expression of AMACR. It is not completely specific for prostate carcinoma. This is due to the reason that it is present in HGPIN (90%), partially atrophic glands, adenosis (17.5%), and at times, morphologically benign glands. AMACR is used as a confirmatory staining for prostate cancer, in combination with basal cell markers and H&E histology.

Thus, a specific and sensitive positive immunohistochemical marker is necessary. This increases the accuracy in pathological diagnosis of prostate malignancies. Also known as p504 S or racemase, AMACR, is an

enzyme identified recently by microarray and cDNA subtraction technology. It is invariably up regulated in prostate cancer, being a specific and sensitive IHC tool. It is overexpressed in prostate cancer with marked differential staining between malignant and benign glands. It is highly sensitive and is seen in 75-95% in prostatic carcinomas.<sup>18</sup>

The AMACR gene product, in prostate cancer, was identified to be over expressed. This was identified with a small number of prostate adenocarcinoma samples in conjunction with high-throughput microarray analysis by complementary DNA library subtraction. It is a protein whose activity is increased in prostatic adenocarcinoma. Its gene is located on 5p13, and its product resides in peroxisomes and mitochondria. The protein has an important role in the  $\beta$  oxidation of bile acid intermediates and branched-chain fatty acids. Since beef and dairy products are the major sources of branched - chain fatty acids, their intake has been linked with an increased risk of prostate cancer. AMACR overexpression and diet have, in the natural history of prostate cancer, complementary roles.<sup>19</sup>

It has been recognized that AMACR is also expressed in the precursor lesion to prostate cancer, HPIN, and even in low grade PIN<sup>20</sup>. At the protein level, AMACR overexpression is tightly linked to prostate cancer. It occurs in almost all stages and grades and also in untreated and hormone-refractory patients. DNA microarray analyses have also found significant overexpression of AMACR in prostate carcinoma

## VI. Conclusion

AMACR has the potential to be a useful marker which can be used separately for diagnosis of prostate carcinoma in clinical pathology practice. The conclusion is that in conjunction with the clinical scenario and morphology, use of prostatic epithelial marker AMACR is of better value in diagnosing the prostate carcinoma cases and other morphologically difficult lesions. The accuracy of diagnosis in prostate cancer is significantly increased. It can be inferred from this study that use of AMACR can be regarded as an inexpensive marker for assessing prostate carcinoma.

## References

- [1]. Yeole, B.B., 2008. Trends in the prostate cancer incidence in India. Asian Pacific journal of cancer prevention: APJCP, 9(1), pp.141-144.
- [2]. Epstein JI, Yang XJ: Prostate biopsy interpretation.3rd ed. Philadelphia, PA:LippincottWilliams & Wilkins. 2002
- [3]. Srigley JR: Benign mimickers of prostatic adenocarcinoma. Mod Pathol. 2004, 17: 328- 348. 10.1038/modpathol.3800055
- [4]. Helpap B: Differential diagnosis of glandular proliferations in the prostate:a conventional and immunohistochemical approach. VirchowsArch. 1998, 433: 397-405.10.1007/s004280050266
- [5]. Varma M, Jasani B: Diagnostic utility of immunohistochemistry in morphologicallydifficult prostate cancer: review of current literature. Histopathology. 2005, 47 (1): 1-16.10.1111/j.1365-2559.2005.02188.x
- [6]. Jiang Z, Wu CL, Woda BA, Iczkowski KA, Chu PG, Tretiakova MS, et al: Alpha- methylacyl-CoA racemase: a multi-institutional study of a new prostate cancer marker.Histopathology. 2004, 45 (3): 218-225. 10.1111/j.1365-2559.2004.01930.x
- [7]. Kahane H, Sharp JW, Shuman GB, Dasilva G, Epstein JI: Utilization of high molecularweight cytokeratin on prostate needle biopsies in an independent laboratory. Urology. 1995, 45 (6): 981-986. 10.1016/S0090-4295(99)80118-6.
- [8]. Humphrey P, van der Kwast TH, et al: Atypical adenomatous hyperplasia of the prostate:the morphologic criteria for its distinction from well-differentiated carcinoma. HumanPathology 1993, 24(8):819-832
- [9]. Landis SH, Murray T, Bolden S, et al. Cancer statistics, 1999. CA Cancer J Clin.1999;49:8-31, 1
- [10]. DiGiuseppe JA, Sauvageot J, Epstein JI. Increasing incidence of minimal residual cancer in radical prostatectomy specimens. Am J SurgPathol. 1997;21:174-178
- [11]. Epstein JI. Diagnostic criteria of limited adenocarcinoma of the prostate on needle biopsy. Hum Pathol. 1995; 26:223-229.
- [12]. Algaba F, Epstein JI, Aldape HC, et al. Assessment of prostate carcinoma in core needle biopsy: definition of diagnosis of cancer in biopsy minimal criteria for the material. Cancer. 1996; 78:376-381.
- [13]. Thorson P, Humphrey PA. Minimal adenocarcinoma in prostate needle biopsy tissue. Am J ClinPathol. 2000; 114:896- 909.
- [14]. Catalona WJ, Richie JP, Ahmann FR, et al. Comparison of digital rectal examination and serum prostate specific antigen in the early detection of prostate cancer: results of a multicentre clinical trial of 6,630 men. J Urol. 1994;151:1283-1290
- [15]. Epstein JI, Potter SR. The pathological interpretation and significance of prostate needle biopsy findings: implications and current controversies. J Urol. 2001;166:402-4410
- [16]. Beach R, Gown AM, De Peralta-Venturina MN, et al. P504S immunohistochemicaldetection in 405 prostatic specimens including 376 18-gauge needle biopsies. Am J SurgPathol. 2002;26:1588-1596
- [17]. Kumaresan et al.: Diagnostic utility of  $\alpha$ -methylacyl CoA Racemase (P504S) &HMWCK in morphologically difficult prostate cancer Diagnostic Pathology 2010, 5:83Vol. 36 (5): 583-590
- [18]. Zhong Jiang, Discovery and Clinical Application of a Novel Prostate Cancer Marker  $\alpha$  Methylacyl CoA Racemase (P504S) Basal cell cocktail (34betaE12 + p63) improve thedetection of prostate basal cells. 2007 Feb;38(2):332-41
- [19]. Magi Galluzzi C, Luo ,Epstein JI:  $\alpha$ -methyl-CoA Racemase: a variably sensitive immunohistochemical marker for the diagnosis of small prostatic cancer foci on needle biopsy. American Journal Surgical Pathology 2003, 27:1128-1133
- [20]. Jonathan I Epstein: Diagnosis and reporting of limited adenocarcinoma of the prostateon needle Biopsy ,USA Volume 35, Issue 12, Pages 1462-1468, December 2004

Dr.L.Arthi. "Expression of AMACR ( $\alpha$ -Methylacyl CoA racemase) in Prostatic Lesion."  
IOSR Journal of Dental and Medical Sciences (IOSR-JDMS), vol. 18, no. 9, 2019, pp 43-47.