

Ocular Manifestations Revealing Of Behçet's Disease: 84 Cases Report.

Zerrouk Rachid^(1 ;&) ; Khmamouche Mehdi¹; Malek Yassine¹; Chatoui Said¹;
Mouzari Yassine¹; Elasri Fouad¹; Reda Karim¹; Oubaaz Abdelbarre¹

¹: ophthalmology department Mohammed V Military Medical Training Hospital in Rabat; university of medicine and pharmacy rabat; morocco

Corresponding author : Zerrouk rachid

Abstract : Behçet's disease is a chronic, autoimmune, multisystem of unknown etiology, characterized by oral ulcers, genital ulcers, and eye lesions. Ophthalmological manifestations of Behçet's disease are numerous and are often indicative of the disease. Our job is to study these events in a group of patients in whom the ophthalmologic involvement was indicative of Behçet's disease. a retrospective study in the ophthalmology department of The Mohammed V Military Medical Training Hospital in Rabat between January 2012 and december 2018. It involved 84 patients who initially consulted for eye symptoms and in that the diagnosis of Behçet's disease was selected based on the criteria of ISG The initial ocular demonstrations were non-granulomatous anterior uveitis in (15,06%) of which (10,9%) with hypopyon, intermediate uveitis (9.5%), ocular hyalite (12.32%), panuveitis in (41,1%), retinal vasculitis (16.43%), retinal vein occlusion(3.6%) , papillary edema (1.8%). The criteria used for the diagnosis of Behçet's disease were essentially have oral ulceration. genital ulceration and pathergy test. In 10% to 20% of cases, ocular involvement may be opening, remaining isolated for several years. The most frequently revealing clinical aspects of Behçet's disease are the anterior uveitis, and vasculitis panuveites the ethnic and geographic origin of the patient, the young age and some clinical features of ocular lesions should remind ophthalmologists to Behçet's disease to inflammation of one of the ocular structures and encourages him to seek other diagnostic criteria in collaboration with other specialities

Keywords: Behçet's disease, diagnostic criteria, oculars manifestations.

Date of Submission: 26-07-2019

Date of Acceptance: 12-08-2019

I. Introduction

Behçet's disease is a chronic, autoimmune, multisystemic disease of unknown etiology. It was first described by Hulusi Behçet in 1937 as a complex combining three signs: recurrent oral ulcer, genital ulcer and iritis. [1]. Since this first description, several sets of diagnostic criteria have been used until 1990, when the International Study Group (ISG) for Behçet's disease established the diagnostic criteria widely used today. [2, 3,4]. The ISG classifies recurrent oral ulcers as a mandatory criterion as well as two of the following four criteria: recurrent genital ulcers, skin lesions, uveitis and a positive pathergic test.

The ophthalmological manifestations of Behçet's disease are multiple and sometimes reveal the disease. Our work consists in studying these manifestations in a group of patients in whom ophthalmological damage has been a sign of Behçet's disease.

II. Materials And Methods

This is a retrospective study carried out in the ophthalmology department of the Mohamed V Military Training Hospital in Rabat between January 2012 and December 2018. It involved 84 patients who initially consulted for ocular symptoms and were diagnosed with Behçet's disease based on ISG criteria.

The parameters studied were: age, sex, ophthalmological manifestations, bilaterality of the disease, criteria for the diagnosis of Behçet's disease, ophthalmological complications and treatments initiated.

III. Results

84 patients were included in this study (146 eyes); 52 males (61.9%) and 32 females (38.1%). The average age of our patients was 29.4±12.58 with extremes ranging from 17 to 66 years.

The initial ocular manifestations were: non-granulomatous anterior uveitis (22 eyes : 15.06%) of which (16 eyes 10.9%) with hypopyon, intermediate uveitis (14 eyes 9.5%), hyalitis (18 eyes 12.32%), panuveitis (60 eyes 41.1%), retinal vasculitis (24 eyes 16.43%) (Figure 1), retinal venous occlusions (6 eyes 4.1%) and papilledema (2 eyes 1.3%). (Table 1).

Ocular manifestations were bilateral in 54 patients (64%), represented mainly by panuveitis, retinal vasculitis and anterior uveitis.

The criteria used to diagnose Behçet's disease were essentially oral aphthosis, genital aphthosis and pathergic testing. (Table 2).

Once the diagnosis was made, patients were treated with a bolus of Solumedrol; 10mg/Kg/day for 3 days, with an oral relay with Prednisolone: 1mg/Kg/day combined with local treatment with corticosteroids and Tropicamide. In 54 patients, background treatment with Immunosuppressants (Azathioprine) in combination with oral corticosteroids has been initiated. The other patients did not receive any disease-modifying treatment since the ocular damage was purely prior.

The evolution was marked by the disappearance of inflammation in all patients. Ophthalmologic complications during follow-up were dominated by cataract, iridocrystalline synechia (Figure 2), cystoid macular edema (Figure 3) and ocular hypertonia. In three of our patients, the progression was marked by the development of blindness secondary to retinal ischemia and optic neuropathy. (Table 3).

IV. Discussion

Behçet's disease is a widespread disease in the world, but with a predilection for the countries of the ancient "Silk Road", especially the Middle and Far East, East Asia and the countries around the Mediterranean basin. [3, 4,5]. It affects both sexes, with a higher frequency and severity in men and a gender ratio that varies according to the series: 0.98 in Japan, 0.63 in Korea, 1.19 in Iran, 1.03 in Turkey and 1.8 in India[3,4, 6,7]. In our study the gender ratio is 1.62.

The age at which the disease begins is most often between 25 and 30 years of age. An early onset in childhood or late onset after age 60 have been reported[4]. The average age of our patients is 29.4 years, which corresponds to the age reported in the literature: 35.7 years in Japan, 29 years in Korea, 26 years in Iran, 25.6 years in Turkey, 29 years in Greece, 24.5 years in Germany and 24.7 years in the United Kingdom. [4,6].

Behçet's disease is a systemic inflammatory disease, characterized by oral and genital ulcers, inflammatory eye disease, skin lesions, vascular disease and many visceral disorders that can be life-threatening. [2, 3,4, 6].

The eye is the organ most often involved in Behçet's disease. Generally, the initial inflammatory eye process is anterior and unilateral and tends to involve the posterior segment of the eye and to become bilateral later. [3, 4, 7, 8,9].

The frequency of ocular involvement varies from study to study, ranging from 28% to 70% and occurs on average 4 years after the onset of systemic manifestations of the disease, including oral aphthosis. [2, 10, 11, 12,13]. In 10% to 20% of cases, however, this attack can be inaugural and remain isolated for a few years[2, 7,14 ,15].

Isolated anterior uveitis is rare, occurring in about 10% of cases. [7, 11, 14,16]. It is always non-granulomatous, and can be single- or bilateral. The classic aspect is that of anterior uveitis to hypopyon, reflecting a particularly severe inflammation of the anterior chamber, found in 12% to 30% of cases. [3,16]

Posterior uveitis is the most serious disease, which can affect the functional prognosis. It is seen in 32 to 53% of cases. It can occur in different forms: a hyalite of variable intensity; foci of yellowish-white retinitis, haemorrhagic, of variable number and location. [3, 14,17]. Occlusive and oedematous retinal vasculitis is an essential sign of ocular involvement in Behçet's disease, it is found in more than 90% of patients. This occlusive vasculitis can be complicated by ischemia, thus conditioning the visual functional prognosis. It can particularly affect the veins. [3, 16, 17].

Papilledema is a rare event, which may be related to intracranial hypertension secondary to venous sinus thrombophlebitis or inflammatory and/or ischemic optical neuropathy[2, 4, 5].

The diagnosis of Behçet's disease is based only on the presence of identified clinical elements grouped together in the same patient[18].

Different diagnostic criteria have been proposed over the years. The most commonly used in practice are the criteria of the International Study Group for Behçet's disease developed in 1990. [19]. In this classification; oral ulceration is a mandatory diagnostic criterion; it must be recurrent and associated with two of the other criteria: recurrent genital ulcers, eye damage, skin damage and a positive pathergic test.

Recently, new international criteria have been proposed by the International Team For The Revision of The International Criteria. A score of 2 is assigned to ocular manifestations, oral and genital aphthosis and a score of 1 is assigned to skin, neurological and vascular disorders and a positive pathergic test. The diagnosis of Behçet's disease is made when the total score is greater than or equal to 4. [4]. No biological test is specific. HLA typing is generally not useful for diagnosis. However, it may be useful for diagnosis in areas where Behçet's disease is not common. There is a higher prevalence of HLA B5, particularly HLA B 51. In addition, a recent Japanese series has shown an association with the HLA-A26 phenotype, found particularly in HLA-B51

positive patients. This phenotype is believed to increase susceptibility to the disease and has also been associated with poor visual prognosis[2].

Several complications can mark the progression of uveitis associated with Behçet's disease and compromise visual prognosis. They are secondary to inflammatory outbreaks, the evolution of lesions and anti-inflammatory treatment. The most frequent are: macular edema (20 to 75%) which conditions the visual prognosis in the long term, posterior synechia (26%), cataract (39%), optic atrophy and glaucoma (14%)[3,4,20]. Retinal neo-vascularization may occur following ischemic occlusive vasculitis in 3.4 to 8% of cases. [3,4, 20]. Other less frequent complications have been reported: intravitreal hemorrhage, retinal dehiscence, retinal detachment and global phthisis. [2, 4,5].

The aim of treatment of ocular damage associated with Behçet's disease is the effective and rapid control of acute inflammatory attacks, and the reduction of the number and severity of recurrences in order to minimize, at best, the risk of complications and sequelae that may cause blindness. This treatment usually combines corticosteroids, used for their immediate anti-inflammatory action on acute attacks, and immunosuppressants as long-term disease-modifying therapy[12, 14, 20].

Only cases of isolated anterior uveitis are covered by local corticosteroid treatment without associated systemic therapy[14]. The mere presence of cells in the vitreous or purely angiographic vasculitis, even in the absence of another clinical abnormality in the posterior segment, is a formal indication for immunosuppressive therapy. [3, 5,13].

Surgical treatment is recommended, only, in case of ocular complications of Behçet's disease such as cataracts or glaucoma. Cataract surgery must be performed on a calm eye with a remission of at least 3 months. Retinovitreal surgery may be indicated in cases of macular hole, retinal detachment or persistent intravitreal hemorrhage. Laser photocoagulation treatment may be considered for neovascular complications secondary to occlusive vasculitis.

V. Conclusion

Eye damage is the initial manifestation of Behçet's disease in 10% to 20% of cases. The diagnosis must be suspected in view of the patient's ethnic and geographical origin, young age and certain clinical features of eye damage. Collaboration with other specialties in the search for other diagnostic criteria is a very important step in confirming the diagnosis.

Conflicts of interest: the authors declare that they have no conflict of interest

Références

- [1]. Behçet H Uber. rezidivierende aphtose durch ein virus verursachte gesch-wure am mund, am auge und an den genitalien. *Dermatol Wochenschr*1937;105:1152-7. [google scholar](#)
- [2]. Khairallah M, Ben Yahia S, Kahlouna R, Khairallah-Ksia I, Messaoud R. OEil et maladie de Behçet. *J fr ophtalmol* 2012 ; 35 :826—837. [google scholar](#)
- [3]. Zeghidi H, Saadoun D, Bodaghi B. Les manifestations oculaires de la maladie de Behçet. *Rev Med Interne*. 2014;(2) 35:97-102. [google scholar](#)
- [4]. Paovic J, Paovic P, Sredovic V. [Behçet's disease: systemic and ocular manifestations](#). *Biomed Res Int*. 2013;2013:1-7. [google scholar](#)
- [5]. Obenauf CD, Shaw HE, Sydnor CF, Sydnor CF, Klintworth GK. Sarcoidosis and its ophthalmic manifestations. *Am J Ophthalmol* 1978;86(5):648-55. [google scholar](#)
- [6]. Davatchi F., Shahram F, Chams C, Chams H, Nadji A. Behçet's disease. *Acta Medica Iranica*. 2005 ; 43(4) :233-242. [google scholar](#)
- [7]. Sakane T, Takeno M, Suzuki N, Inaba G. Behçet's disease. *N Engl J Med* . 1999;341(17):1284-91. [google scholar](#)
- [8]. Kitaichi N, Miyazaki A, Stanford M. R, Chams H, Iwata D, Ohno S. Ocular features of Behçet's disease: an international collaborative study. *Br J Ophthalmol*. 2007 ;91(12) :1579-1582. [google scholar](#)
- [9]. Dias Ljopis M, Cervera M, Mnezo J. Cyclosporin a treatment of Behçet's disease: a long term study. *Curr Eye Res*. 1990; 9:17-23. [google scholar](#)
- [10]. Chen K, Kawahara Y, Miyakawa S, Nishikawa T. Cutaneous vasculitis in Behçet's disease: A clinical and histopathologic study of 20 patients. *J Am Acad Dermatol* 1997;36 (5 Pt 1):689-96. [google scholar](#)
- [11]. Nussenblatt RB. Uveitis in Behçet's disease. *Int Rev Immunol* 1997;14(1):67-79. [google scholar](#)
- [12]. Okada AA. Behçet's disease: general concepts and recent advances. *Curr Opin Ophthalmol* 2006;17(6):551-6. [google scholar](#)
- [13]. Hatemi G, Silman A, Bang D, Bodaghi B, Chamberlain AM, Gul A, et al. EULAR Recommendations for the management of Behçet disease. *Ann Rheum Dis* 2008;67(12):1656-62. [google scholar](#)
- [14]. Evereklioglu C. Current concepts in the etiology and treatment of Behçet disease. *Surv Ophthalmol* 2005;50:297-350. [google scholar](#)
- [15]. Zierhut M, Saal J, Pleyer U, Kotter I, Durk H, Fierlbeck G. Behçet's disease: epidemiology and eye manifestations in German and Mediterranean patients. *Ger J Ophthalmol*. 1995; 4(4):246-51. [google scholar](#)
- [16]. Tugal-Tutkun I, Onal S, Altan-Yaycioglu R, Huseyin Altunbas H, Urgancioglu M. Uveitis in Behçet's disease: an analysis of 880 patients. *Am J Ophthalmol* 2004;138(3):373-80. [google scholar](#)
- [17]. Khairallah M, Attia S, Ben Yahia S, Jenzeri S, Ghrissi R, Jelliti B, et al. Pattern of uveitis in Behçet's disease in a referral center in Tunisia, North Africa. *Int Ophthalmol* 2009;29:135-41. [google scholar](#)

Ocular Manifestations Revealing Of Behçet's Disease:

- [18]. Hewitt J, Escande JP, Lauret P, Perlemuter L. Criteria for diagnosis of Behçet's syndrome. Bull Soc Fr Dermatol Syphiligr 1969;76:565-8. [google scholar](#)
- [19]. International Study Group for Behçet's disease. Criteria for diagnosis of Behçet's disease. Lancet 1990;335 (8697):1078-80. [google scholar](#)
- [20]. Tugal-Tutkun I. Imaging in the diagnosis and management of Behçet disease. Int Ophthalmol Clin 2012; 52(4):183-90. [google scholar](#)

LEGEND:

Figure 1: Retinal angiography showing retinal vasculitis with macular edema and lower hyalitis.

Figure 2: Photo of the anterior segment showing iridocrystalline synechia.

Figure 3: OCT showing cystoid macular edema before and after treatment.

Table 1: Initial ocular manifestations of Behçet's disease in our series.

Table 2: Criteria for the diagnosis of Behçet's disease in our series

Table 3: Ophthalmological complications in our series.

INITIAL OCULAR MANIFESTATIONS	(% OF EYES)	
	MAN	WOMAN
anterior uveitis	9,59	5,47
intermediate uveitis	5,47	4,1
hyalite	6,8	5,47
panuveitis	27,39	13,69
retinal vasculitis	9,58	6,84
retinal venous occlusion	2,73	1,36
papillary edema	0	1,36

TABLE 1: PREVALENCE OF OCULAR MANIFESTATIONS.

The criteria used to diagnose Behçet's disease	% of patients
Ocular manifestation	100
Mouth aphthosis	100
Genital aphthosis	80,95
Skin lesions	33,33
Pathergic test	90,47
Neurological impairment	0
Vascular damage	0

TABLE 2: CRITERIA FOR THE DIAGNOSIS OF BEHÇET'S DISEASE

Ophthalmological complications	Number of cases / 146 eyes	Percentage (%)
Cataract	22	15,06
Iridocrystalline synechia	40	27,39
Eye Hypertonia	10	6,84
Intravitreal hemorrhage	2	1,36
Macular edema	22	15,06
Blindness	3	2

TABLE 3: OPHTHALMOLOGICAL COMPLICATIONS DURING BEHÇET'S DISEASE

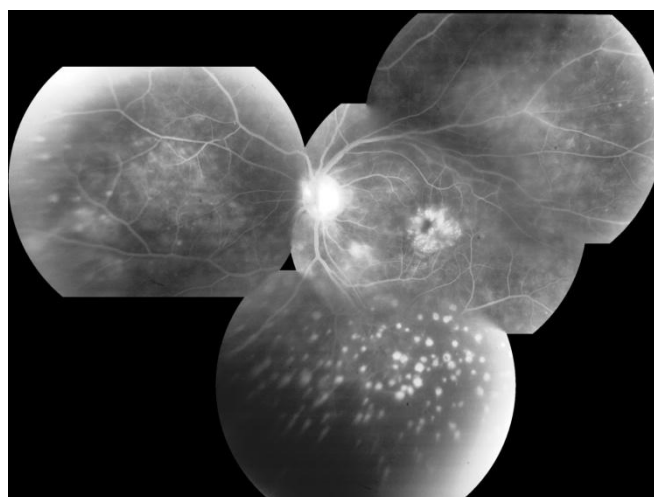


FIGURE 1 : Retinal angiography showing retinal vasculitis with macular edema and lower hyalitis.

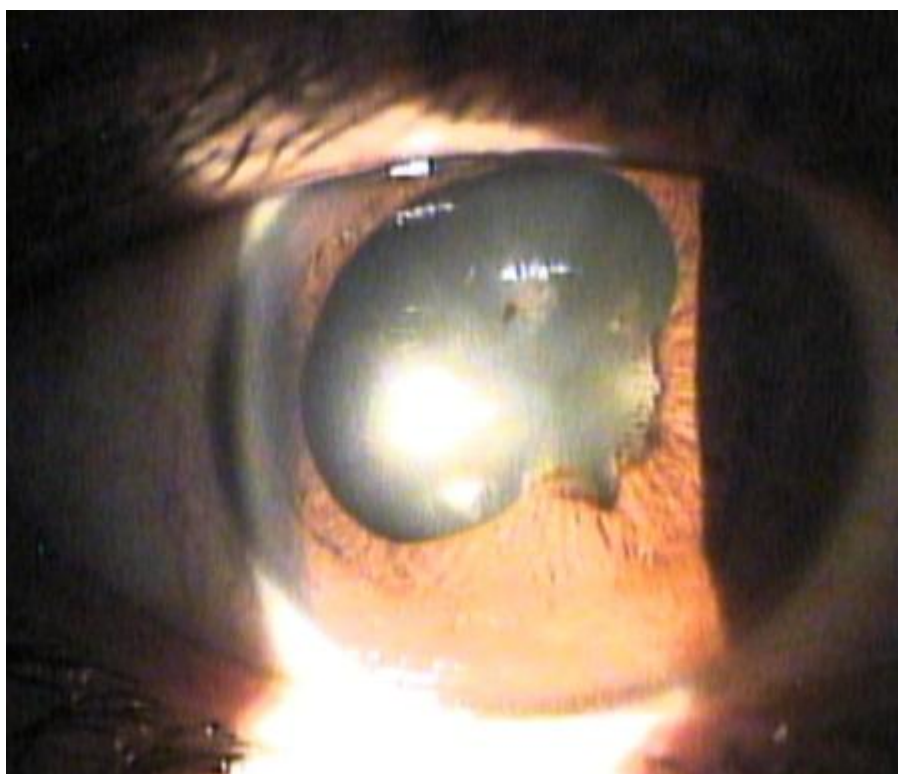


FIGURE2 : Photo of the anterior segment showing iridocrystalline synechia.

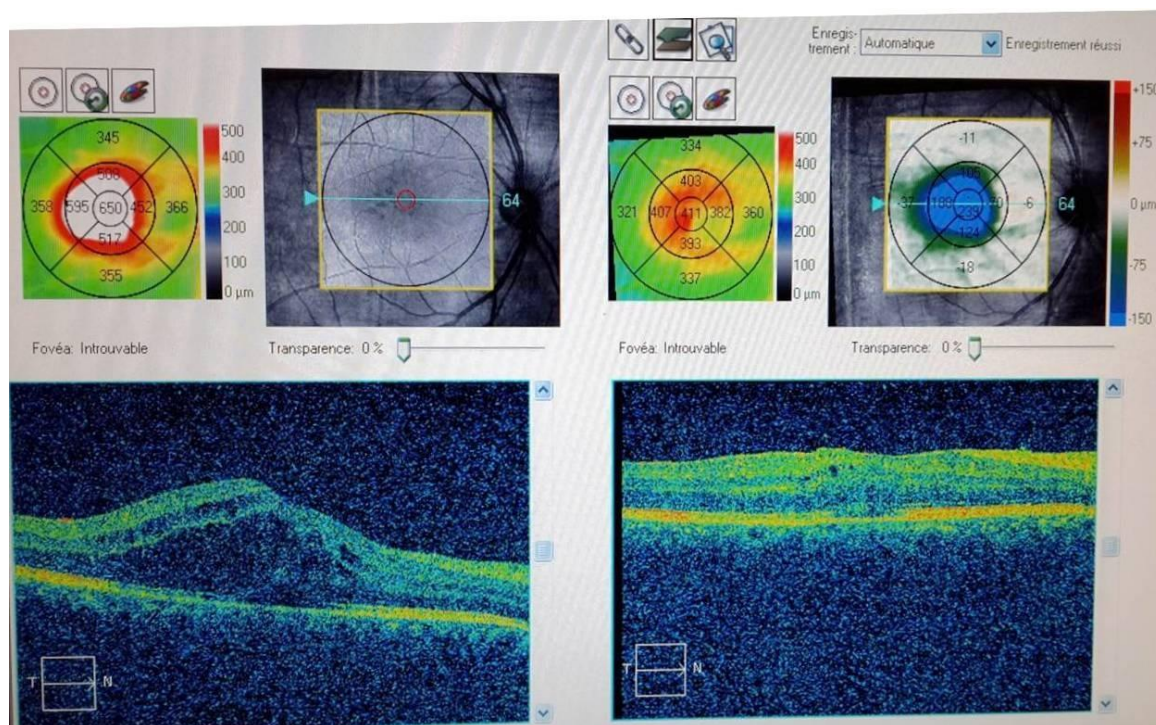


FIGURE3 : OCT showing cystoid macular edema before and after treatment.

Zerrouk rachid. " Ocular Manifestations Revealing Of Behçet's Disease: 84 Cases Report." IOSR Journal of Dental and Medical Sciences (IOSR-JDMS), vol. 18, no. 8, 2019, pp 91-95.