

## Case Report: Fluorosis Presenting As Quadriparesis

Dr. K. Bharath Kumar Reddy<sup>1</sup>, Dr. Ramavath Raghuramulu Naik<sup>2</sup>,  
Dr. Biruduraju Vasavi<sup>3</sup>, Dr. C. Kedarnath Goud<sup>4</sup>.

<sup>1</sup>Postgraduate in Department of General Medicine.

<sup>2</sup>MD, Assistant professor, Department of General Medicine.

<sup>3</sup>Postgraduate in Department of General Medicine.

<sup>4</sup>Postgraduate in Department of General Medicine.

Main Author: Dr. K. Bharath Kumar Reddy.

Corresponding Author: Dr. Ramavath Raghuramulu Naik.

Institute: SVRRGGH, Tirupati.

---

Date of Submission: 17-08-2019

Date of Acceptance: 03-09-2019

---

### I. Introduction

Fluorosis is a term used for chronic intoxication of the body due to excessive fluoride in drinking water(1). Endemic skeletal fluorosis is the state of chronic fluoride intoxication caused by high intake of natural fluoride through drinking water(2). It is endemic in many countries around the world including India. Cases of skeletal fluorosis are reported from many parts of India, like Southern Rajasthan, Andhra Pradesh, Kanpur district of Uttar Pradesh and Punjab(2-4). Fluorosis patients may be asymptomatic or present as serious crippling deformities.

In 8-10 percent cases of skeletal fluorosis, neurological complications occur. The neurological characteristics present in the form of cervical myeloradiculopathy, cervical myelopathy or radiculopathy, dorsal myelopathy, and peripheral neuropathy.

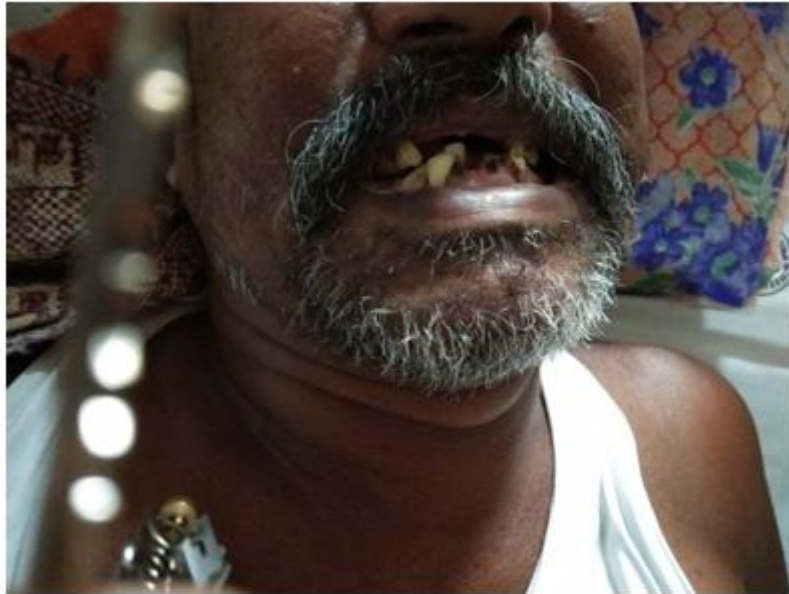### II. Case report

A 54 year old male, who was a resident of Ananthapur district, by occupation blacksmith came with chief complaints of neck pain for the past 18 months which is aggravated on bending the neck, associated with shock-like sensation starting from the base of neck till the lower back and then the patient had weakness of left lower limb for the past 1 year which progressed from distal to proximal muscles, in which the patient initially noticed difficulty in gripping of chappals later by buckling attacks at knee and then by difficulty in squatting. The patient noticed similar difficulty in right lower limb for the past 10 months. The patient noticed weakness of right upper limb for the past 9 months initially in the form of difficulty in holding the tools used for his work later ascended to proximal muscle weakness in the form of difficulty in reaching overhead objects. The patient noticed similar difficulty in the left upper limb for the past 8 months. He also had paraesthesias in the form of tingling and numbness which initially started in feet later ascended to the entire to entire lower limbs and then even in the upper limbs from distal to proximal parts. He also had difficulty in perceiving mosquito bites overall extremities; difficulty in appreciating hot & cold sensations over the extremities. The patient had gait difficulty because of the weakness which progressed from no-stick stage to having support of his attendees on both sides. The patient is not able to walk even with support for the past 10 days. History of flexor spasms were present for the past 1 week. He is also having constipation for the past 1 month. The patient had symptoms of detrusor sphincter dyssynergia for the past 2 months which progressed to complete retention of urine for the past 4 days for which the patient was catheterized after in hospital admission. There is no history suggesting cranial nerve and cerebellar involvement. No history of trauma to head or spine in the present/past. Patient is non-diabetic and non-hypertensive.

On examination, patient is conscious and oriented to time/place/person; higher mental functions were normal. No neurocutaneous markers were present. No external spinal deformity and tenderness. No external markers of tuberculosis were found. There is no pallor, icterus, cyanosis, clubbing, pedal edema, and generalized lymphadenopathy. Small exostosis were present over both shins. The systemic examination of respiratory, cardiovascular and gastrointestinal systems was normal. Peripheral nervous system examination is normal.

#### Dental examination:

Yellowish-brown discoloration of teeth with dental caries and mottling was present



**Motor system:**

There is spasticity of all four limbs. Power is 4-/5 in right upper limb and 4+/5 in left upper limb in the proximal muscles; 2/5 at right wrist and 3/5 at left wrist. The handgrip is 30% on right side and 40% on left side. Power is 2/5 in the lower limb.

**Reflexes:**

Deep tendon reflexes- Pectoral, biceps, triceps, supinator, knee, and ankle reflexes were exaggerated. Wrist and ankle clonus were present bilaterally.

Superficial reflexes-Plantars were bilaterally extensors, and corneal/conjunctival reflexes were present. Rest of the superficial reflexes like anal, bulbocavernosus, and cremasteric reflexes were absent.

**Sensory system:**

Pain, temperature, and touch sensations were impaired in the entire lower limbs, and graded sensory loss is present in both upper limbs till the level of C5. Joint sense, position sense and vibration sense were impaired in both lower limbs and upper limbs. Vibration sense is preserved above the region of upper cervical vertebra.

**Cranial nerve examination:**

Normal

**Gait:**

Cannot be assessed

**Cerebellar:**

No signs of cerebellar involvement

**Cortical sensations:**

Cannot be assessed as primary sensations were impaired.

### III. Investigations

**Blood investigations:**

Basic investigations like complete blood count, serum electrolytes, serum calcium, serum magnesium, serum phosphorous, ESR, Renal function tests, Liver function tests, RBS, FBS, PPBS, and chest x-ray were normal. Serum and urinary concentrations of Fluoride are mildly elevated. PTH levels were in the high normal range. Vitamin B12 levels and Serum copper levels were within the normal range.

**Nerve conduction study:**

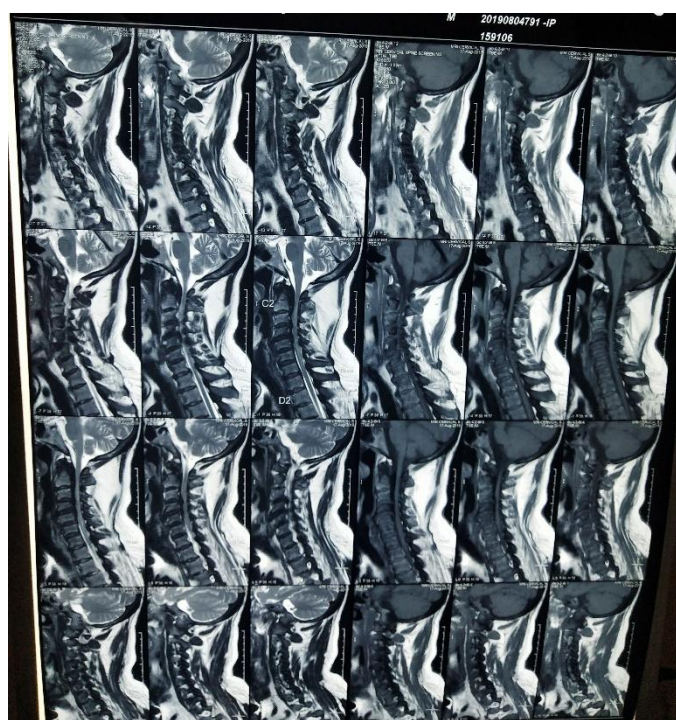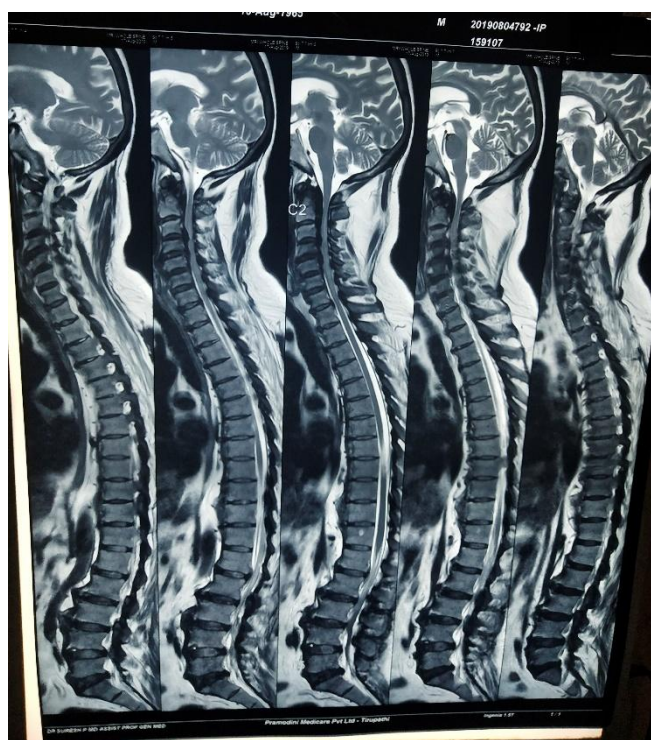Low amplitude in both lower limbs and upper limbs

**Radiological:**

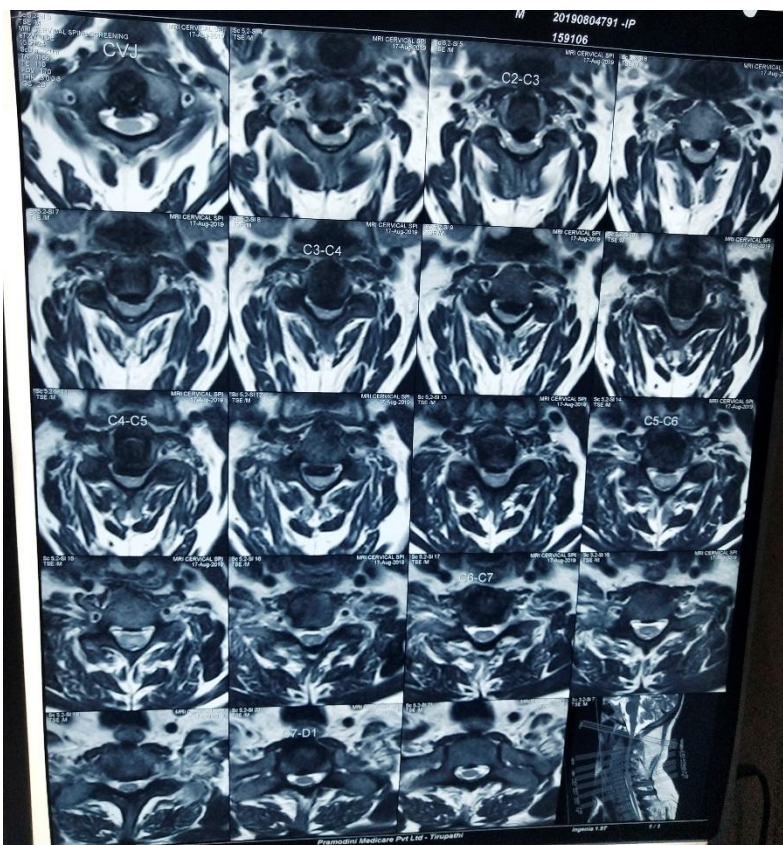
**MRI Cervical spine:**

- Cervical and lumbar spondylotic changes.
- Diffuse osteosclerosis of vertebrae.

-Disc osteophyte complexes with calcification/thickening of posterior longitudinal ligament C1-C2 to C5-C6 levels causing compression of the thecal sac, multilevel central canal stenosis, multifocal cord compression with cord thinning, atrophy and myelomalacia changes.

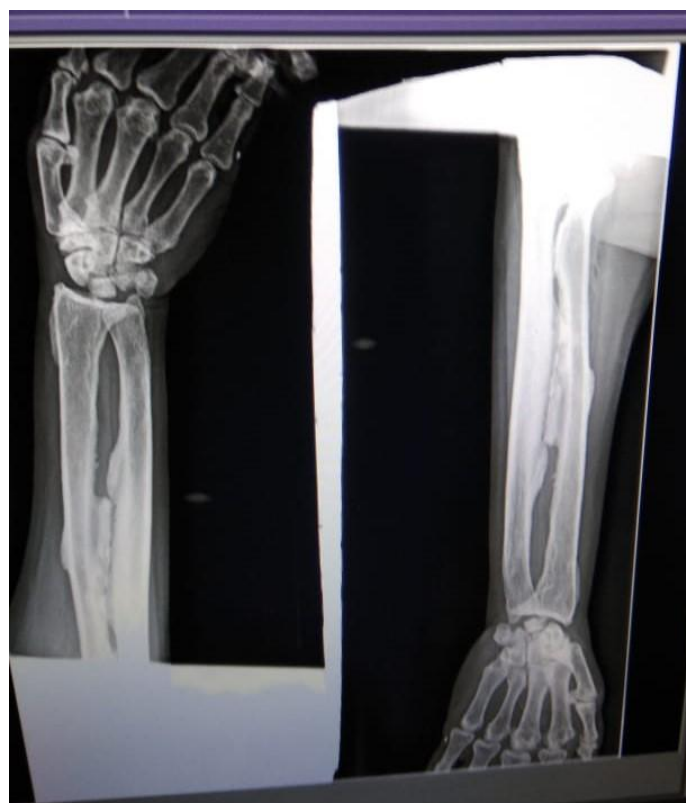





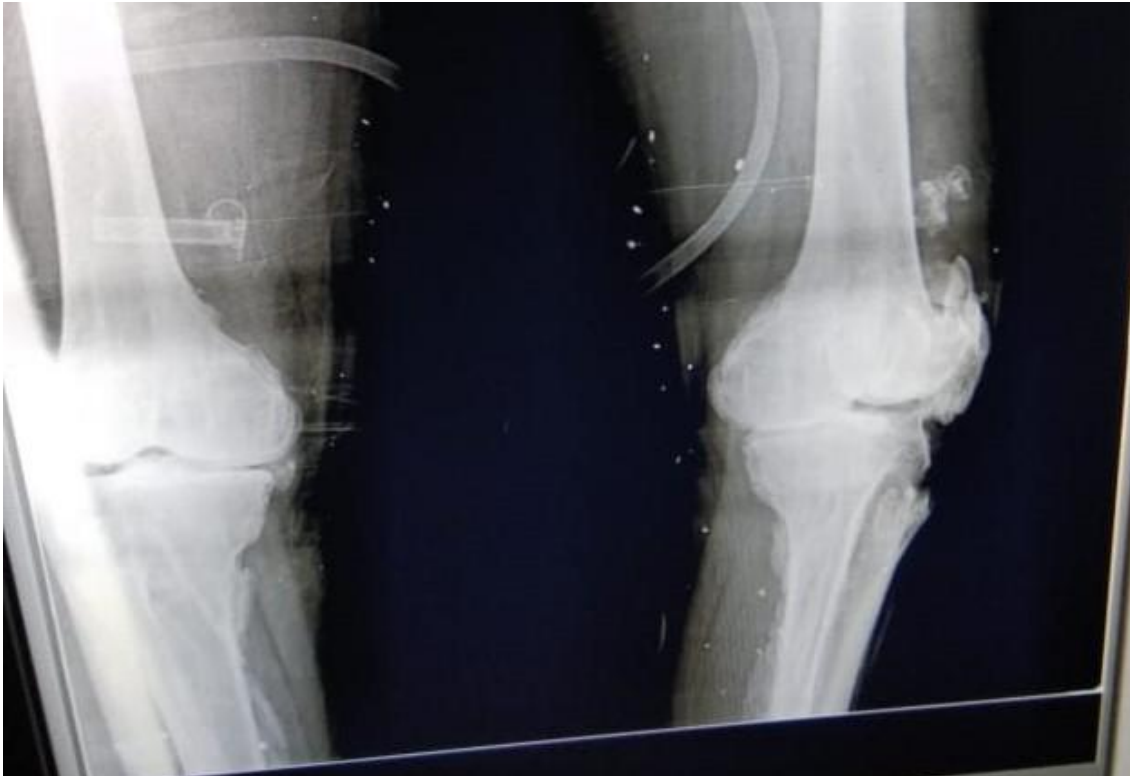**Xray Forearm:**

Ossification of the inter-osseous membrane is present.



**XrayBoth knee joints:**

Osteophyte formation with irregular bone formation.



**IV. Discussion**

Endemic fluorosis is a type of chronic fluoride intoxication caused mostly by ingestion of fluoride-containing water. It is a well-defined clinical entity characterized by changes in the dental system and skeleton.

The two main sources of fluorides are water (including various beverages) and food. Ninety percent of rural water supplies are based on ground water sources, and these, in large parts of the country, do not have optimum levels of fluorides for a tropical country like India. In contrast, all major cities in the country get a good part of their water supply from perennial rivers that have optimum fluoride content. Epidemiological studies have proven that malnutrition aggravates fluoride toxicity. It is well known that malnutrition is widely prevalent in rural areas of our country, and it has become extremely difficult to control it. It is, therefore, obvious that fluorosis has become very prevalent in the country, is rapidly spreading and has become a major public health problem(5).

Fluorosis is endemic in 20 out of 35 states and union territories of the Indian Republic. In Andhra Pradesh, Gujarat and Rajasthan, 70-100% of the districts are affected. Fluoride levels in water in Andhra Pradesh vary from 0.4 mg/l to a very high level of 29 mg/l(6).

Fluorine is one of the trace elements found in the body, and in small quantities, it is beneficial for the growth of enamel. In India, 0.5 - 0.8 ppm of fluorine in drinking water is considered safe. When the fluoride content of water is high, it gets accumulated in the skeletal system and teeth(7).

It is not known how fluorides initiate a wide variety of histological changes in bones and teeth. Most people believe that the fluoride converts the hydroxyapatite crystallites in the bone into more stable fluoroapatite crystallites(8).

**Clinical features:**

Progressive evolution of clinical features correlates with the duration of stay in the endemic fluorosis villages and high intake of fluoride from the drinking water. The bone disease and deformities are more severe and complex in patients with dietary calcium deficiency (intake < 300 mg/d) as compared with those with adequate calcium nutrition (Ca intake > 800 mg/d)(7).

### Dental fluorosis:

Dental fluorosis is an early and sensitive manifestation in children presenting as white chalky opacities or pitting on the enamel. It is seen only if the child has resided in the endemic area during the eruptive period of the teeth, and it has been taken as an index of endemicity in epidemiological surveys(9).

Dental fluorosis, popularly called as “mottled enamel” is one of the earliest, sensitive, and an easily distinguishable sign of fluorosis in children. It has been taken as an index of endemicity in epidemiological surveys. Dental fluorosis is divided into three grades(9):

Gr. 1: White chalky opacities or patches on enamel with or without faint yellow lines.

Gr. 2: Distinct brownish discoloration.

Gr.3: Besides pigmentation, there is pitting of enamel surface, sometimes with chipping of edges.

### Skeletal fluorosis:

Whereas the dental fluorosis is an easily recognizable entity, the skeletal fluorosis evades detection in the early stages. The incidence of skeletal fluorosis varies from 2.5% to 70% of all cases of fluorosis(7).

The skeletal changes were progressive, and classical changes were seen as first in head and neck. In skeletal fluorosis the patient develops progressive neck rigidity and stiffness resulting in the restricted movements of head. The neck rigidity and the head fixity is due to the fusion of vertebral bones in the cervical areas. The cause for the fusion is the progressive deposition of fluoride in the vertebral bone and also in the intervertebral disc. The entire process of neck rigidity and fixity of the skull is progressive, depending upon the amount of fluoride deposited in the bone and disc(10).

The common symptoms are pain in the neck and back associated with rigidity, joint pains, and paraesthesia of the limb. The cases may be mistaken for rheumatoid arthritis, ankylosing spondylitis, and osteoarthritis.

The physical findings include postural defects like kyphosis, limitation of the movements of the spine, and exostosis(7). Presence of exostosis is a common and useful physical sign found in almost all the bones. It can easily be palpated along the anterior border of tibia, over the olecranon, and along the medial border of the scapula. Crippling deformities are seen in patients of 30 - 50 years of age in endemic areas. Though it is generally believed that it takes about 4 - 5 years of exposure to develop skeletal fluorosis, it has been described in children, infants, and neonates. The skeletal fluorosis may develop within 6 months of exposure to high intake of fluoride(4,5). Genu valgum deformity has been reported in endemic areas of Andhra Pradesh, in young individuals with poor nutritional status(11,12).

The neurological complications occur in 3 - 10% of cases of skeletal fluorosis(2). Neurological complications of skeletal fluorosis like myelopathy and radiculopathy are secondary and mechanical in nature due to primary involvement of vertebra and ligaments. Vertebral column shows most prominent changes in the form of osteosclerosis and irregular osteophyte formation resulting into beaklike lipping and a chalky-white ground-glass appearance(13). The neurological features are in the form of cervical myeloradiculopathy, cervical myelopathy or radiculopathy, dorsal myelopathy, and peripheral neuropathy. The cranial nerve involvement and sensory deficits are rare(7).

### Investigations:

#### Biochemical markers:

Plasma calcium, magnesium, and phosphorus remain normal; alkaline phosphatase and fluoride levels are mostly elevated. Serum parathyroid hormone levels are almost always raised as a compensatory mechanism to maintain extracellular ionized calcium.

#### Radiology:

Radiological changes are diagnostic of the condition. The changes are seen most commonly in the vertebral column, pelvis, and forearm bones. The classical features are osteosclerosis, irregular osteophyte formation and calcification of ligaments; in advanced cases, the bones look chalky white. Irregular periosteal bony formation was observed along the muscular, fascial and tendinous attachments. Interosseous membrane calcification of the forearm is the most frequent and easily recognizable feature. This has been taken as a definite radiological index of skeletal fluorosis(2).

### References

- [1]. Who. Guidelines for drinking-water quality, volume 2: Health criteria and other supporting information. Sci Total Environ. 1987 Jan;61:274.
- [2]. Teotia SP, Teotia M. Endemic fluorosis in India: a challenging national health problem. J Assoc Physicians India. 1984 Apr;32(4):347-52.
- [3]. Rajasthan SCD. Endemic fluorosis in southern Rajasthan, India. 2001;10.
- [4]. Proceedings, Workshop on Medical Geology, IGCP-454, 3-4 February 2004, Nagpur, India. Kolkata : Geological Survey of India; 2004.

- [5]. Reddy Dr. The element fluorine and its effects on human health including its neurological manifestations. *Neurol India*. 2017;65(2):238.
- [6]. Fluorideandfluorosis.com [Internet]. [cited 2019 Aug 24]. Available from: <http://ww7.fluorideandfluorosis.com/>
- [7]. Gupta A, Singh T, Agrawal PK, Singh D, Sachan M, Agarwal V. Quadripareisis – A Rare Presentation of Skeletal Fluorosis. 2008;9(3):4.
- [8]. Jolly SS, Singh BM, Mathur OC, Malhotra KC. Epidemiological, Clinical, and Biochemical Study of Endemic Dental and Skeletal Fluorosis in Punjab. *Br Med J*. 1968 Nov 16;4(5628):427–9.
- [9]. Teotia SP. Dental fluorosis. *Natl Med J India*. 1999 Jun;12(3):96–8.
- [10]. 696\_pdf.pdf [Internet]. [cited 2019 Aug 24]. Available from: [http://ijcrr.com/uploads/696\\_pdf.pdf](http://ijcrr.com/uploads/696_pdf.pdf)
- [11]. Pandit CG, Raghavachari TNS, Rao DS, Krishnamurti V. Endemic Fluorosis in South India. A Study of the Factors Involved in the Production of Mottled Enamel in Children and Severe Bone Manifestations in Adults. *Indian J Med Res*. 1940;28:533–58.
- [12]. Jolly SS, Prasad S, Sharma R. Endemic fluorosis in India. *J Assoc Physicians India*. 1970 Apr;18(4):459–71.
- [13]. Singh A, Vazirani SJ, Jolly SS, Bansal BC. Endemic fluorosis with particular reference to dental and systemic intoxication. *Postgrad Med J*. 1962 Mar;38:150–6.

Dr.Birudurajuvasavi. “Case Report:Flourosis Presenting As Quadripareisis.” *IOSR Journal of Dental and Medical Sciences (IOSR-JDMS)*, vol. 18, no. 8, 2019, pp 64-70.