

## Incidence of Gall Bladder and Hepatobiliary anomalies: An institutional study

Shireesh Gupta, Pranav Raja Yadav , Aayushi Kedawat

1 Associate Professor, 2 Junior Resident, 3 Junior Resident

Department of General Surgery

Mahatma Gandhi University of Medical Sciences and Technology RIICO, Sitapura, Jaipur, India

Corresponding Author: Shireesh Gupta,

---

**Abstract:** The presence of any congenital hepatobiliary anomaly or the mere suspicion of its existence demands that we exercise surgical prudence, limit the use of electrocautery and ensure that no structure be divided until a clear picture of the bile ducts and blood vessels is obtained. If necessary, perform intraoperative cholangiogram to further define the biliary system. However, if the case remains unclear or if laparoscopy does not provide enough information, open surgery should be considered although it has many undesirable complications. We conducted a study 200 cases of cholelithiasis operated in our institute to determine the incidence of gallbladder and hepatobiliary anomalies. Patients underwent Ultrasound of abdomen, empty stomach and if needed, underwent triple phase CT or MRCP or both. Subsequently patients underwent open or laparoscopic cholecystectomy.

---

Date of Submission: 06-08-2019

Date of acceptance: 20-08-2019

---

### I. Introduction

Congenital anomalies of gallbladder are not so rare and can be accompanied by other malformations of the biliary or vascular tree. Being difficult to diagnose during routine preoperative studies, these anomalies can provide surgeons with an unusual surprise during laparoscopic surgery. Abnormalities and malposition of the gallbladder are relatively common and since they are encountered frequently in surgery of the biliary tract it is desirable for the surgeon to be familiar with them. A study performed [1] on 10,016 fetal examinations after the

14 week of gestation showed a 0.15% incidence of gallbladder malformations. Many types of anomalies of the gallbladder have been described. These include congenital reduplication of the gallbladder, bilobed gallbladder, anomalous positions of the gallbladder, "hourglass" deformities and congenital absence of the gallbladder.[2]

Anomalies of cystic duct and artery are common. Usually cystic artery arises from right hepatic artery but in around 5 percent of people it arises from proper hepatic artery and in 2.5 percent it arises from common hepatic artery.

Different cystic duct variations are described in the literature based on its length, course, and site of insertion with common hepatic duct (CHD). Some variations which are clinically more important are the following: (i) low insertion of cystic duct, (ii) parallel course of cystic duct with CHD, (iii) anterior or posterior spiral course with medial insertion, (iv) absent or short cystic duct (length < 5 mm), (v) aberrant drainage of cystic duct to right hepatic or left hepatic duct, (vi) aberrant or accessory intrahepatic ducts draining into cystic duct, and (vii) double cystic duct.

Preoperative diagnosis of malformation is only obtained in exceptional cases, and these anomalies often turn out to be unexpected findings during laparoscopic surgery. If the preoperative evaluation does not suggest an anomaly, malformation can constitute high risk factor for injury to the common bile duct or vascular system. Extreme prudence is required in cases of possible congenital malformation and no final action should be carried out before the surgeon has a clear picture of the gallbladder area. Electrocautery should be limited as much as possible, and the possibility of a non-diagnosed congenital malformation should not be neglected.

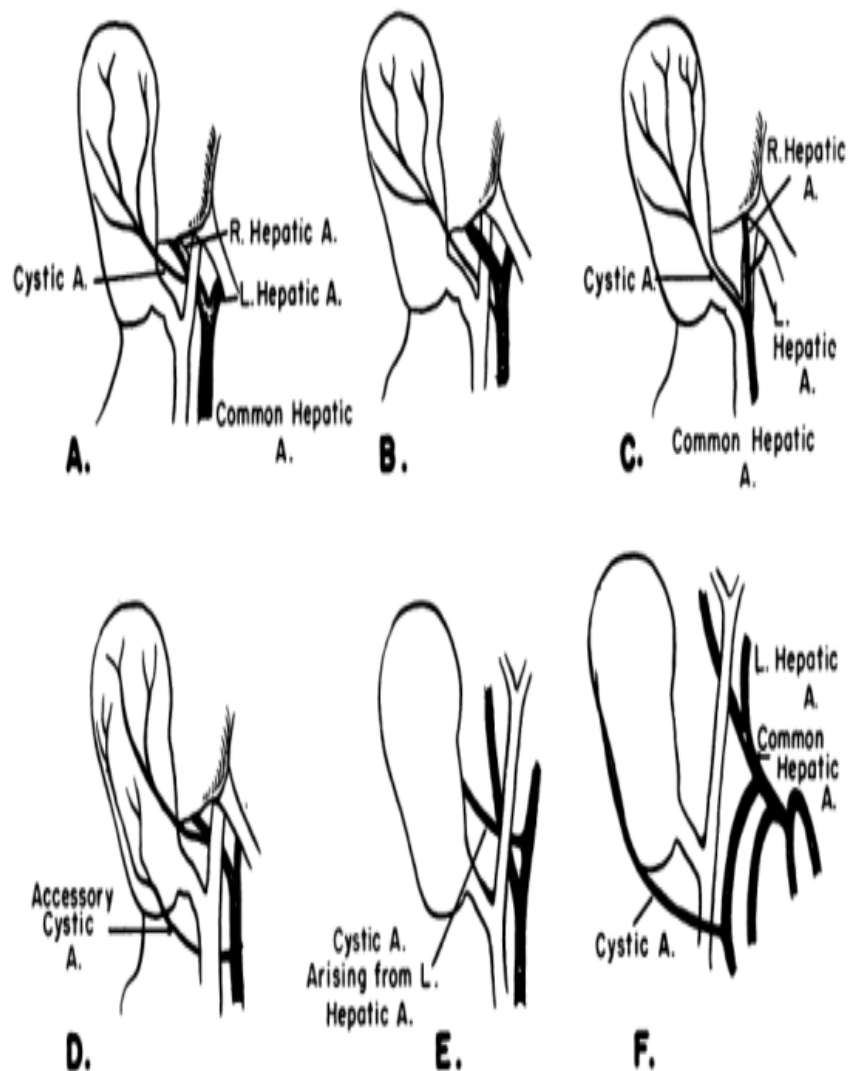


Fig. 5.—A long cystic artery descends from near the porta hepatis. B. Cystic artery originating from common hepatic artery and passes deep to the common hepatic duct. C. Cystic artery arises from common hepatic artery and passes superficial to common hepatic duct. D. Accessory cystic artery arising from common hepatic artery. E. Cystic artery originates from left hepatic artery. F. Cystic artery arising from gastro-duodenal artery and crosses in front of bile duct to reach its destination.

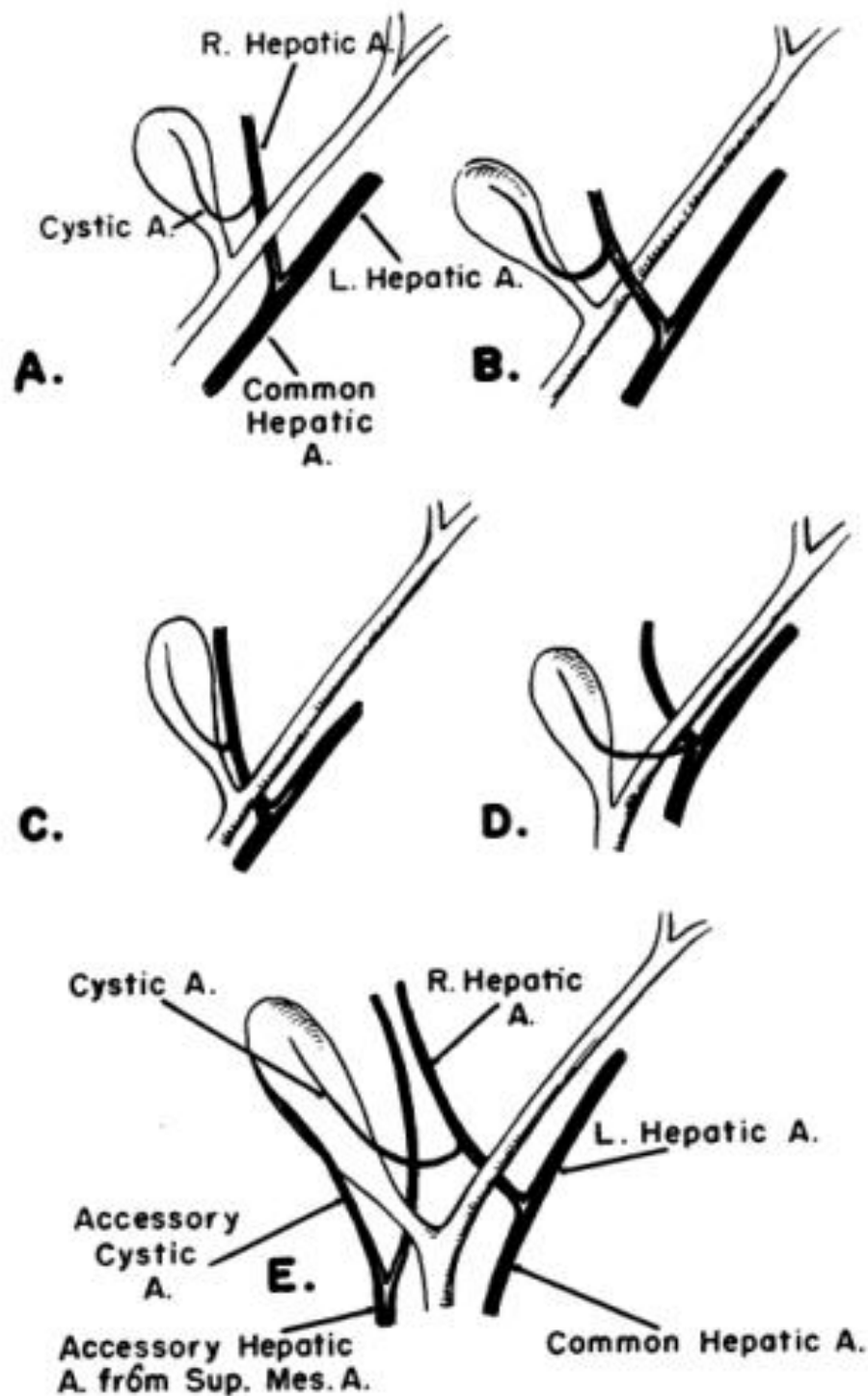


Fig. 3.—Variations observed in present study. A. Normal cystic artery and right hepatic artery. B. Right hepatic artery crosses in front of common hepatic duct. C. The right hepatic parallel to and in the neighborhood of cystic duct. D. Cystic artery crosses superficial to common hepatic duct. E. Accessory right hepatic and cystic arteries.

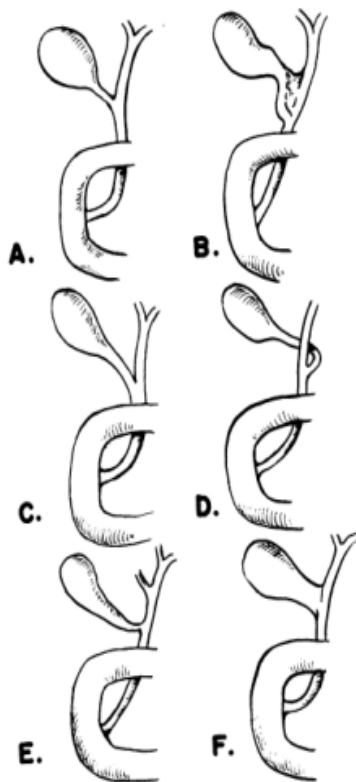


Fig. 1.—Six variations of cystic duct. (After Lee McGregor). A. Normal cystic duct. B. Normal cystic duct with a fibrous band between the cystic duct and common hepatic duct. C. Cystic duct joins the common hepatic duct, just before the latter enters the duodenum. D. Cystic duct joins the common hepatic on its left. E. Accessory right hepatic duct. F. Direct communication of gall bladder with hepatic duct and absence of cystic duct.

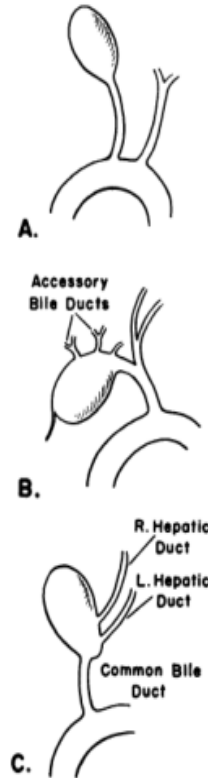


Fig. 2.—Other variations (After Grey Turner). (N.B. Michels terms these configurations "utter nonsense." See discussion, Ed.) A. Cystic duct opens directly into duodenum. B. Accessory hepatic ducts open directly into gall bladder. C. The right and left hepatic ducts open into gall bladder and the bile duct leaves the gall bladder. Absence of common hepatic and cystic ducts.

## II. Methodology

Two hundred cholecystectomies performed by laparoscopy or open method over a period of two years (2017-2019) were analysed. Eighty percent of the patients underwent surgery via laparoscopy while the remaining 20% underwent open surgery. The average age of the group was 49years(ranging from 17 to 83years).The majority were female, representing68% of our patient population, and the remaining 32%were male. The preoperative diagnosis in 96% of the cases was symptomatic biliary lithiasis with history of biliary colics or cholecystitis. In the remaining 4%, the preoperative diagnosis was acute calculus cholecystitis. Whenever required, MRCP was a standard preoperative diagnostic method to visualize hepatobiliary system. MRCP was performed in patients with choledocholithiasis and those having abnormal liver function test especially elevated serum Alkaline Phosphatase. Triple phase CT Scan of abdomen was done whenever investigations suggested gall bladder malignancy. An endoscopic retrograde cholangio pancreatography (ERCP) was added when considered appropriate(8% of the cases), usually in case of choledocholithiasis with choledocolithiasis. Conventional laparoscopic cholecystectomy with four ports was done. Open cholecystectomy was done by a subcostal incision .

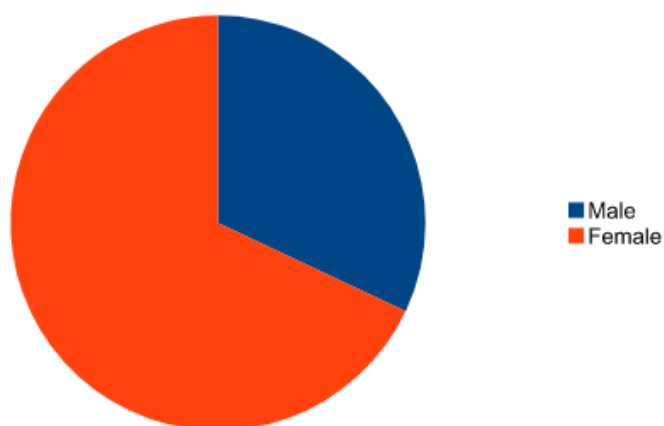
Exclusion criteria; Patients managed conservatively or medically unfit for surgery.

## III. Results

Table 1: Sex Distribution

Total no Of patients	Male	Female
200	64	136

**Chart 1 :Sex Distribution**

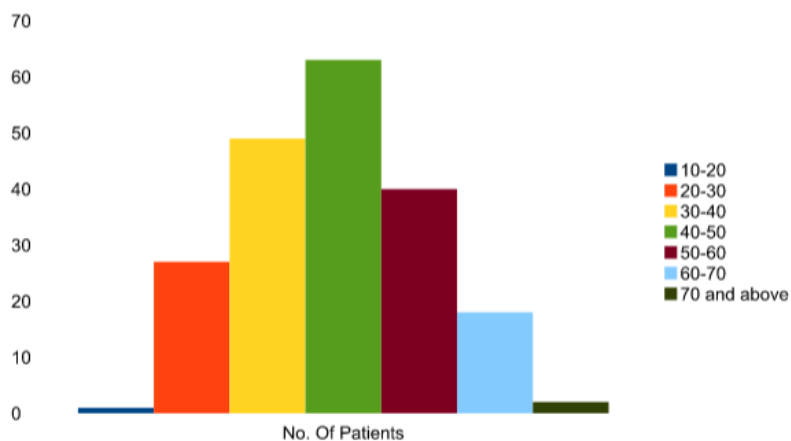


**Table 2 : Age Distribution**

Age	No. Of Patients
10-20	1
20-30	27
30-40	49
40-50	63
50-60	40
60-70	18
70 and above	2

**Chart 2: Age Distribution**

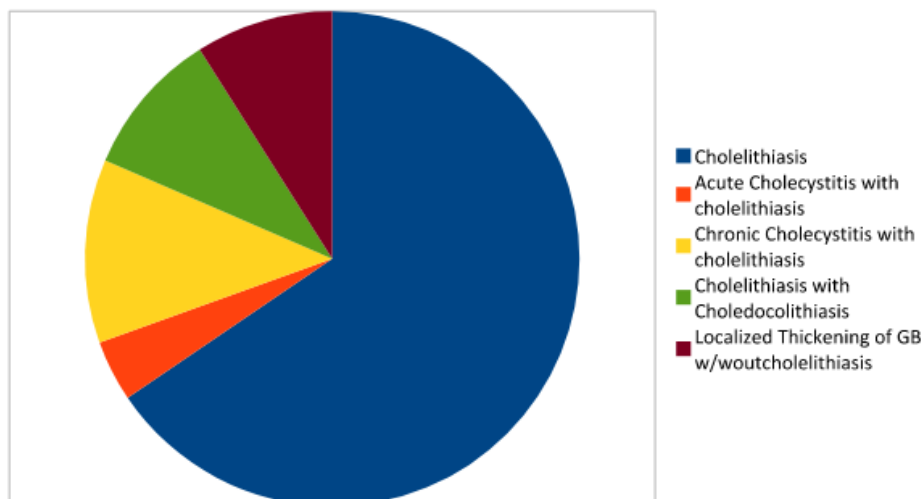
**Chart 2**



**Age Distribution**

**Table 3 : Findings on Ultrasound of Abdomen**

USG findings of the patients	No. Of Patients
Cholelithiasis	131
Acute Cholecystitis with cholelithiasis	8
Chronic Cholecystitis with cholelithiasis	24
Cholelithiasis with Choledocolithiasis	19
Localized Thickening of GB w/w'out cholelithiasis	18

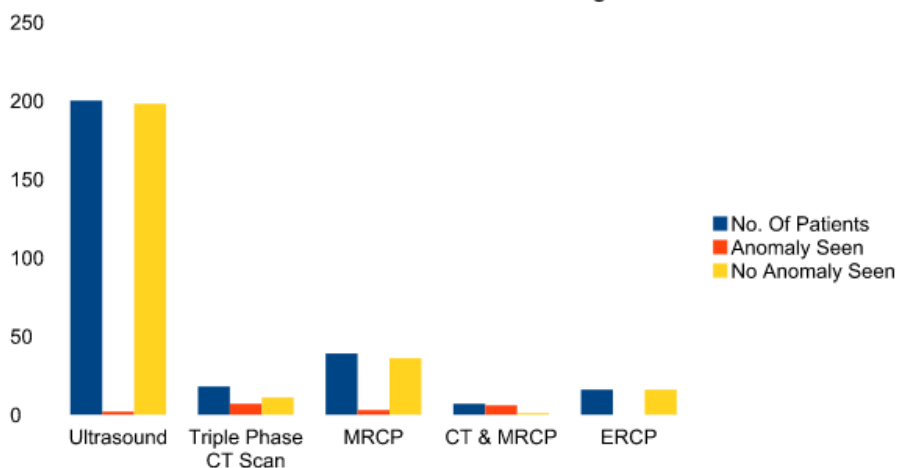


**Findings on Ultrasound Abdomen**

**Table 4 :Anomalies detected on Investigations**

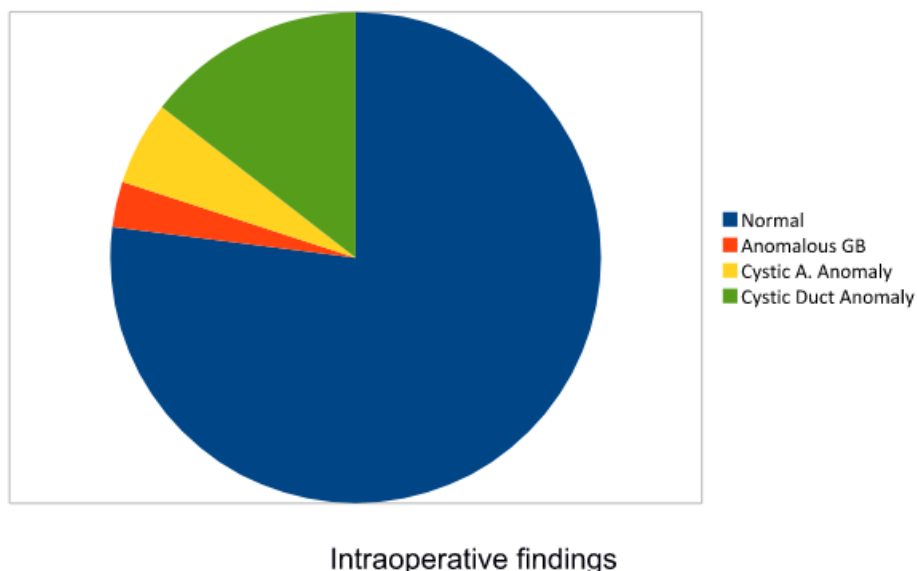
Procedure	No. Of Patients	Anomaly Seen	No Anomaly Seen
Ultrasound	200	2	198
Triple Phase CT Scan	18	7	11
MRCP	39	3	36
CT & MRCP	7	6	1
ERCP	16	0	16

**Anomalies Detected On Investigations**



**Table 5 :Intraoperative Findings**

Normal	154
Anomalous GB	6
Cystic A. Anomaly	11
Cystic Duct Anomaly	29



Most of the congenital malformations were diagnosed during the operative procedure, and very few were suspected from the routine preoperative evaluation (USG whole abdomen, CECT, MRCP or ERCP). Congenital gallbladder malformations were diagnosed in 3% of the cases: one gallbladder and cystic duct agenesis (0.5%) [3]; one left lobule misplacement with insertion of the cystic duct into the left hepatic duct (0.5%) [4]; four gallbladder hyperplasia (congenital vesicle diverticulo) (2.0%). Diagnosis was also made of five cases of insertions of the cystic duct into the right hepatic tract (8.5%); low insertion of cystic duct into CBD in twelve cases (6.0%); absent cystic duct (Mirizzi syndrome) in twelve cases (6.0%); as well as the above mentioned insertion into the left hepatic tract. [5] Finally, eleven anomalies of the cystic artery (5.5%) were identified. Most of these anomalies were discovered intraoperatively. Two patients had to be converted from laparoscopic to an open procedure for anatomic verification. There were no major intraoperative complications among the patients. In all cases, very careful dissection was required of the gallbladder, cystic duct, insertion of cystic duct into CBD, cystic artery and CBD. Particularly complicated was the case of agenesis of the Gallbladder which had a preoperative diagnosis of scleroatrophic gallbladder. In this instance, it was difficult to distinguish between the hepatic duct and presumed gallbladder scleroatrophy. Patients were discharged postoperatively in 24 hours to 48 hours.

#### IV. Discussion

The growing use of laparoscopy for gallbladder disease obliges us to be familiar with different kinds of biliary malformations and to always take them into account whenever we are faced with something unusual. Anatomy that does not appear normal should suggest the possibility of biliary malformation and dissection should proceed with extreme caution. Gallbladder and cystic duct agenesis can be particularly complex, and if sonography shows hypogenesis or gallbladder scleroatrophy, there is a high risk of mistaking the common bile duct for supposed gallbladder scleroatrophy, with the danger of either injuring or cutting it.

Gallbladder hypoplasia may be more frequent despite the fact that there are no specific reports of it in the literature. It may be in the form of a small gallbladder stump directly attached to the common hepatic duct or by means of a very short, atrophied or dilated cystic duct, and be mistaken for the common bile duct. This malformation is difficult to identify during surgery and constitutes a high-risk factor for potential injury to the hepatocholedochal system. As a consequence, it is absolutely necessary to identify it well before cutting or dividing tubular structures. When in doubt, gallbladder extirpation should be done antegrade, which provides better visualization of the anatomical structures. In our case this did not prove necessary, but is a good alternative when the anatomy is unclear. In the presence of confused or poorly defined anatomy, the possibility of biliary tree congenital anomaly must be taken in consideration. Congenital biliary duct malformations may provide a real surprise during laparoscopic surgery. The use of electrocautery should be limited, and no structure should be sectioned until a clear picture of the vascular tree and bile ducts has been obtained. Subsequently, if doubt still remains or if the surgeon's experience in laparoscopic surgery is limited, the operation should be converted to an open procedure before any avoidable complications occur.

### References

- [1]. Bronshtein M, Weiner Z, Abramovici H, Erlik Y, Blumenfeld Z. Prenatal diagnosis of gallbladder anomalies. Report of 17 cases. *Prenat Diagn.* 1993;13(9):851-861.
- [2]. McIlrath DC, Remine WH, Baggenstoss AM. Congenital absence of the gallbladder and cystic duct. *JAMA.* 1962;180:782-784
- [3]. Fujita N, Shirai Y, Ohtani T, Tsukada K, Hirota M, Hatekeyama K. Junction of the cystic duct with the left hepatic duct: report of a case discovered during laparoscopic cholecystectomy. *Surg Laparosc Endosc.* 1996;6(6):445-447.
- [4]. MA Carbajo Caballero, JC Martin del Olmo, JI Blanco Alvarez, R Atienza Sánchez. Gallbladder and cystic duct absence. *Surg Endosc.* 1997; 11:483-484.
- [5]. Ogawa T, Ohwada S, Ikeya T, Shiozaki H, Aiba S, Morishita Y. Left-sided gallbladder with anomalies of the intrahepatic portal vein and anomalous junction of the pancreatobiliary ductal system: a case report. *Hepatogastroenterology.* 1995;42(5):645-649

Shireesh Gupta," Incidence of Gall Bladder and Hepatobiliary anomalies: An institutional study" *IOSR Journal of Dental and Medical Sciences (IOSR-JDMS)*, vol. 18, no. 8, 2019, pp 40-47.