

## Rehabilitation of Severely Worn Dentition using Full Fixed Prosthesis - an Systematic Approach: Case Series

Dr. Shah Shikha<sup>1</sup>, Dr. Patel Bindal<sup>2</sup>, Dr. Sethuraman Rajesh<sup>3</sup>, Dr. Gupta Kavita<sup>4</sup>, Dr. Chhabra Tamanna<sup>5</sup>, Dr. Khaire Neha<sup>6</sup>

<sup>1</sup>(Post Graduate Student, Department of Prosthodontics and Crown and Bridge, K. M. Shah Dental College and Hospital, Vadodara, Gujarat, India)

<sup>2</sup>(Post Graduate Student, Department of Prosthodontics and Crown and Bridge, K. M. Shah Dental College and Hospital, Vadodara, Gujarat, India)

<sup>3</sup>(Professor and Head of Department, Department of Prosthodontics and Crown and Bridge, K. M. Shah Dental College and Hospital, Vadodara, Gujarat, India)

<sup>4</sup>(Professor, Department of Prosthodontics and Crown and Bridge, K. M. Shah Dental College and Hospital, Vadodara, Gujarat, India)

<sup>5</sup>(Professor, Department of Prosthodontics and Crown and Bridge, K. M. Shah Dental College and Hospital, Vadodara, Gujarat, India)

<sup>6</sup>(Post Graduate Student, Department of Prosthodontics and Crown and Bridge, K. M. Shah Dental College and Hospital, Vadodara, Gujarat, India)

Corresponding Author: Dr. Shah Shikha

---

**Abstract:** Restoration of the function and esthetics of the severely worn dentition becomes a challenge to the dentist. Full mouth rehabilitation is done for the modification of the health of the entire mouth, including the teeth, gums and the occlusion. It is requisite for the replacement or restoration of the all teeth in the mouth using a combination of dental services. The phrase full-mouth rehabilitation means different things to different people. Though the full-mouth rehabilitation and its philosophies are often intrigue in nature, but the esthetic and functional accomplishment of rehabilitation is always satisfying. It requires proper diagnosis and detailed treatment planning. In this case series two most commonly used philosophies for full mouth rehabilitation were included and patient's esthetics and functional requirements were fulfilled.

**Keywords:** Tooth wear, Hobo philosophy, Pankey-Mann-Schuyler philosophy, Full mouth rehabilitation.

---

Date of Submission: 26-06-2019

Date of acceptance: 13-07-2019

---

### I. Introduction

The continuing wear of the occlusal surfaces of teeth is a normal process during the lifetime of a patient. However, unwarranted occlusal wear can lead to pulpal pathology, impaired function, occlusal destruction and esthetic deformity.<sup>1</sup> Results of tooth wear can be divided in three conditions attrition, abrasion, and erosion.<sup>2</sup>

So, it is important to identify the factors that contribute to excessive wear and to evaluate alteration of the VDO caused by the worn dentition.<sup>3</sup> In certain cases, the VDO is maintained by alveolar bone growth & tooth eruption. However, the rehabilitation is challenging when the space for restoration is not sufficient especially in esthetic zone. Crown lengthening of the anteriors is necessary. Therefore in such cases not only replacement of the lost tooth structure but also restoring the lost vertical dimensions is important<sup>4</sup>. Dahl et al.<sup>5</sup> in 1975 described the use of a removable cobalt-chromium anterior occlusal device to make interocclusal space for restoration. The movement of teeth involving a combination of orthodontic intrusion of anterior teeth and posterior teeth eruption occurred. And after the long-term observations of this treatment, the vertical relations were practically stable.<sup>7,8</sup> Currently this technique is replaced by using the adhesive resin<sup>9</sup> or an overlay splint<sup>6,10</sup>

Basically this is a set of procedures that are correcting an improper bite position and restoring chipped or worn out teeth also. Various occlusal concepts have been proposed by different authors. The 2 most popular concepts are Pankey Mann Schuyler philosophy and the Hobo twin-stage technique.

After the whole examination and complete understanding of the aetiology, a treatment plan can be formulated. The following case series included one case presentation which demonstrates a restoration of severely worn out dentition without loss of VDO by fixed bridges using Hobo Twin stage technique. Second case presentation which demonstrates a correction of loss VDO by giving removable occlusal splint for 5 weeks and the temporary restoration for 3 months followed by fixed bridges using Pankey Mann Schuyler philosophy.

## II. Case reports

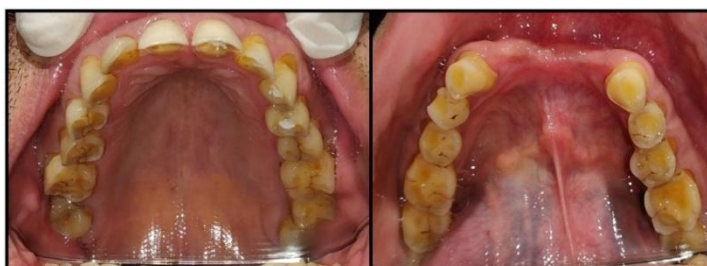### Case 1:

A 65-year-old male reported to the Department of Prosthodontics, Crown and Bridge, K.M.Shah Dental College and Hospital, Vadodara, with a chief complaint of unsightly appearance due to multiple worn-out upper and lower teeth, generalized sensitivity, and difficulty in chewing. Medical history revealed that the patient was apparently healthy without any systemic complications. The patient's dental history revealed that he has a habit of clenching.

### Clinical findings

**Extraoral:** The patient had no gross facial asymmetry, or muscle tenderness. The mandibular movements were within the range of normal motion. The TMJ, the muscles of mastication, and the facial expression were asymptomatic.

**Intraoral:** There was generalized severe attrition of the upper and lower dentition with fair oral hygiene. The maxillary arch was fully dentate and the mandibular arch was having missing 32,31,41,42. No gross abnormalities were noted [Figure 1].



**Fig. 1** Intraoral View: Upper Arch & Lower Arch


### Occlusal:

The patient was having generalized attrition of dentition with no loss of vertical dimension. The patient presented with a bilateral class I molar and canine relationship. No discrepancy was noted between centric relation and maximum intercuspation. The patient's lateral excursions showed bilateral balanced occlusion. Orthopantomogram (OPG) of the patient further confirmed these findings

### Treatment procedure

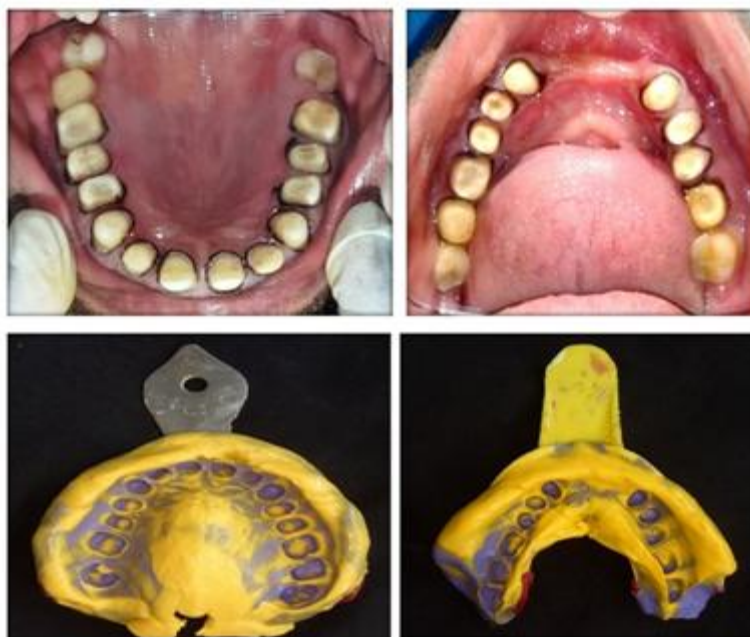The rehabilitation was carried out as follows:

1. Maxillary and mandibular impressions were made in the alginate impression material and diagnostic casts were obtained.
2. For diagnostic mounting, maxillary cast was articulated on HANAU wide-Vue articulator using an earpiece facebow and mandibular cast was articulated in maximum intercuspation.
3. Diagnostic wax-up was done at the existed vertical to see the final outcomes. The articulator was programmed to condition 1 of Hobo's twin-stage procedure wherein the posterior segment wax mockup was done in bilaterally balanced occlusion after removal of the maxillary anterior segment was replaced and the anterior wax up was completed and checked for proper anterior guidance to achieve disocclusion in eccentric movements. The putty index of this diagnostic wax up was made to fabricate provisional restorations [Figure 2].



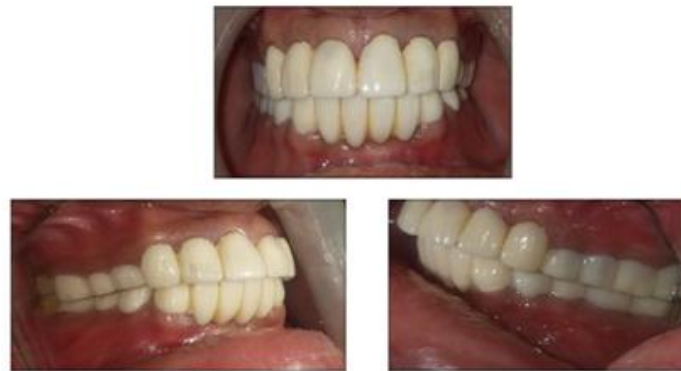**Fig. 2** Diagnostic wax up according to values of condition 1 and 2

4. The teeth were prepared and final full arch impression for maxillary/mandibular teeth was made using polyvinyl siloxane impression material with casts were poured in die stone. [Figures 3]



**Fig. 3** Teeth preparation with Gingival retraction and Final impression

This assembly was mounted on Hanau articulator using the face-bow and centric record and tooth-colored acrylic temporary restorations were fabricated with the help of putty index, which was made from the diagnostic wax up. The provisional restorations were cemented using noneugenol zinc oxide cement and the necessary occlusal adjustments were carried out in the provisional restorations to obtain desired occlusion. [Figure 4].




**Fig. 4 Temporization**

- The articulator was programmed to different conditions of the twin-stage procedure as in Table 1. Fabrication of the cusp angle for this, a standard effective cusp angle of 25° was set to Condition 1 of the twin-stage procedure [Table 1] and the maxillary and/or mandibular anterior segment was removed.

**Table 1: Articulator adjustment values**

Condition	Condylar path		Anterior guide table	
	Sagittal condylar path inclination	Bennett angle	Sagittal inclination	Lateral wing angle
Condition 1	25	15	25	10
Condition 2	40	15	45	20

Then the occlusal morphology of the posterior Metal crown was completed and balanced articulation was obtained [Figure 5].



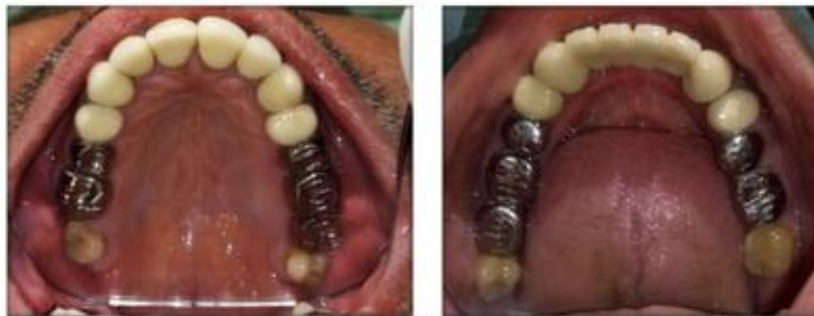**Fig. 5 Fabrication of posterior wax pattern (in protrusive)**

- Fabrication of anterior teeth the anterior segment of the cast was reassembled. After the anterior metal try-in, anterior PFM crown build-ups were completed based on values of Condition 2 of the twin-stage procedure [Table 1] to achieve an incisal guidance of 40°, which produced a standard amount of disocclusion. The anterior teeth produced contact during protrusion and contact on canines during lateral movement [Figure 6].

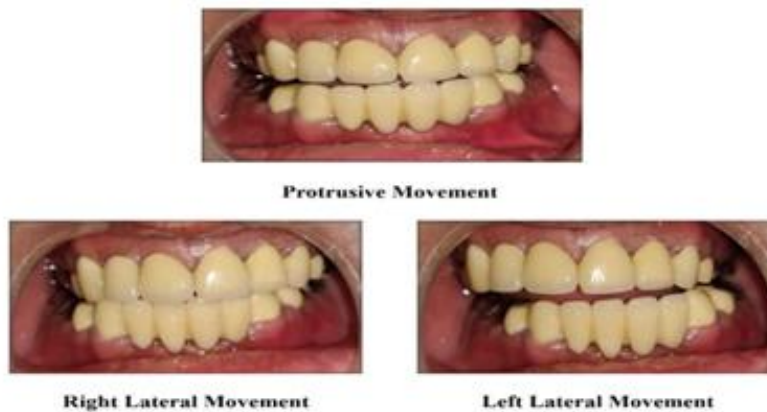

**Fig. 6 Fabrication of Anterior wax pattern**

7. Permanent cementation was done with GIC type I luting cement [Figure 7].



**Fig. 7 Permanent Cementation**

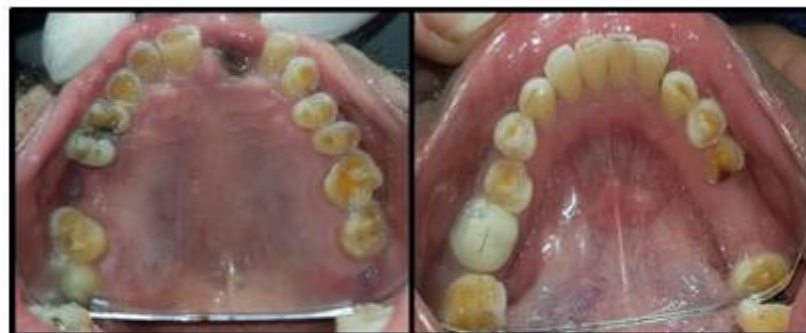

8. Oral hygiene instructions were given. Follow-up was carried out at regular intervals.



**Case 2:**

A 77-year-old male patient was referred for the treatment of his severely worn dentition. His chief complaint was that he could not eat anything because sensitivity and worn out teeth. The patient had no relevant medical history. Intraoral examination revealed a generalized loss of dental substance that was greater in the maxillary and mandibular posterior teeth. The anterior teeth had sharp enamel edges, dentinal craters, and attritional wear due to the loss of posterior support. 16, 21, 36 teeth were missing.[Figure 1] 21 was grossly carious and only root piece was retained.



**Fig. 1 Intraoral View**

The patient did not have temporomandibular disorder history and soreness of the mastication muscles, but the discrepancy between centric occlusion and maximum intercuspal position was found when he was guided to CR with bimanual technique.

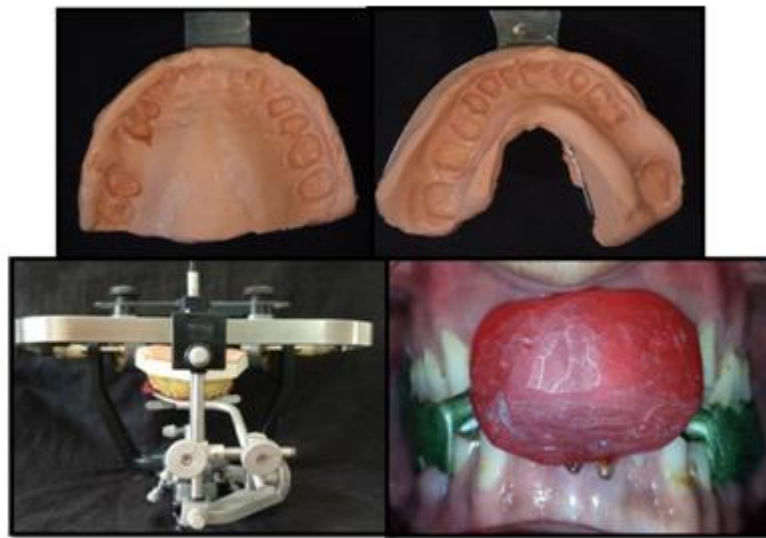
To determine whether VDO had been altered, the following aspects were investigated: Loss of posterior support, mandibular posterior teeth were missing, and the patient did not use the mandibular partial denture. Posterior collapse resulted in excessive wear and fracture of anterior teeth.

Physiologic wear can be compensated by tooth eruption in general, but the accelerated wear may exceed the rate of eruption.

The possible causes of patient's worn dentition that might include posterior interferences, parafunction, eating habit, and dental ignorance were explained to the patient. And the options of treatment plan were restoring mandibular edentulous posterior region with implants or removable partial denture, full mouth rehabilitation with metal ceramic restoration.

The patient was scared of implant surgery, so the option of implant installation was excluded. As there was clinical evaluation of reduced VDO, full mouth rehabilitation with increasing VDO was planned. Only severely worn teeth which were lower anteriors were undergone crown lengthening procedures to obtain a sufficient clinical crown length and endodontic treatment was carried out in necessary teeth.

The patient's casts were mounted on a Hanau wide view semi-adjustable articulator using a face-bow record and an interocclusal record that was made with the aid of a Lucia jig and occlusal registration material [Figure 2]

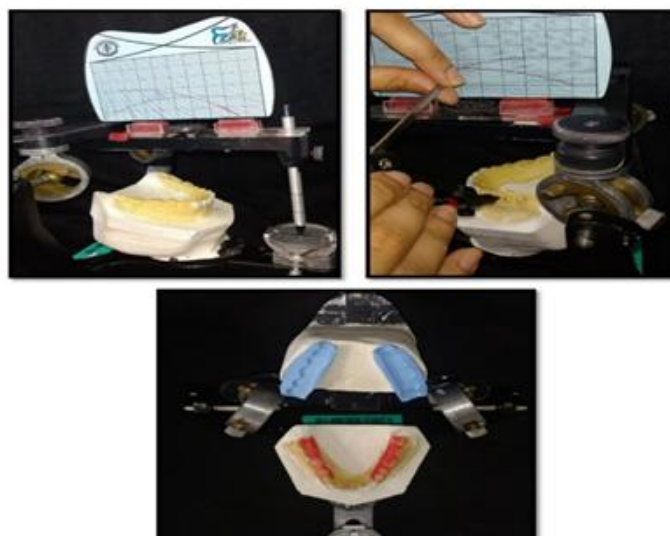


**Fig. 2** Diagnostic Impression, Face bow transfer and Lucia jig interocclusal record

The new VDO was set by 5 mm increase in the incisal guidance pin of the articulator. Because the patient's interocclusal rest space was 2 - 3 mm larger on the premolar area than normal distance, the actual increase were determined 3 mm in the anterior teeth and 1 - 2 mm in the posterior teeth. The splint was designed to offer bilateral contacts of all posterior teeth in centric relation and guides of the anterior teeth in excursive movement. The anterior guidance disoccluded the posterior teeth in all jaw position except centric relation.

The adaptation of patient to the increased VDO was evaluated during 1-month trial period. No muscle tenderness and temporomandibular discomfort was found. The method of increasing VDO with the splint was used to determine desirable VDO of the fixed interim prostheses. After taking CR record using Lucia jig and wax-rim, diagnostic wax-up of anteriors were performed.

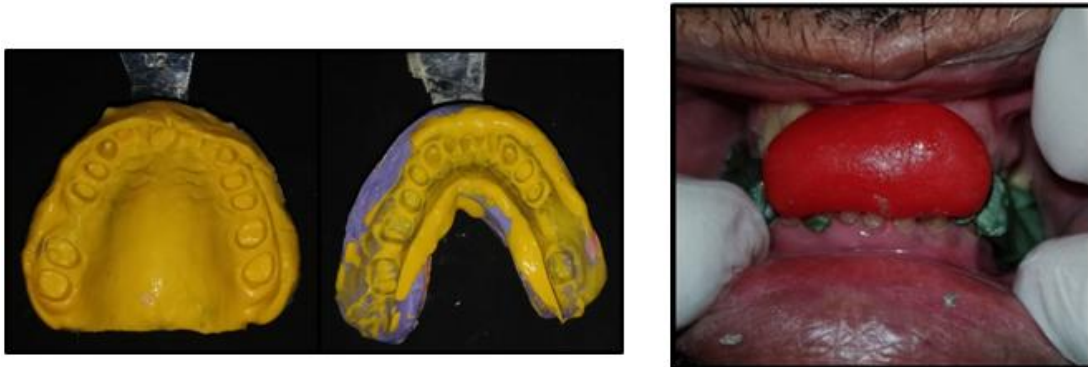Autopolymerizing acrylic resin (ALIKETM; GC America, ALSIP, USA) provisional crowns were fabricated using a vacuum formed matrix and esthetic and phonetics were evaluated.(Drufolen H; DreveDentamid GmbH, Unna, Germany). The provisional fixed restorations were cemented with temporary cement (FREEGENOL TEMPORARY PACK; GC Corp., Tokyo, Japan), and the patient's adaptation was monitored. The posterior occlusal plane was decided using broadrick plane analyzer. [Figure 3].



**Fig. 3** Broadrick plane analyzer

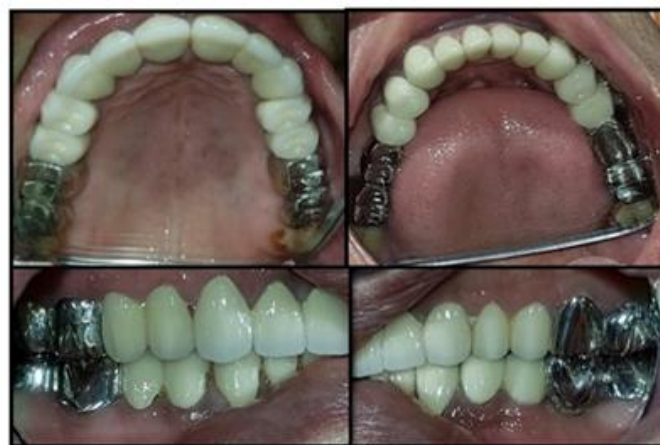According to that plane wax up of posterior teeth is done and evaluated in patients mouth by making of acrylic temporaries.

Final preparation was performed, and definitive impressions were made with polyvinylsiloxane impression material (Extrude; Kerr Corp., Romulus, Germany). Bite registration was taken using provisional crown and occlusal registration material (StoneBite; DreveDentamid GmbH, Unna, Germany) by half and half. [Figure 4]



**Fig.4 Final Impression & Bite registration**

CAD-CAM heat cure temporaries were fabricated and cemented. [Figure 5]

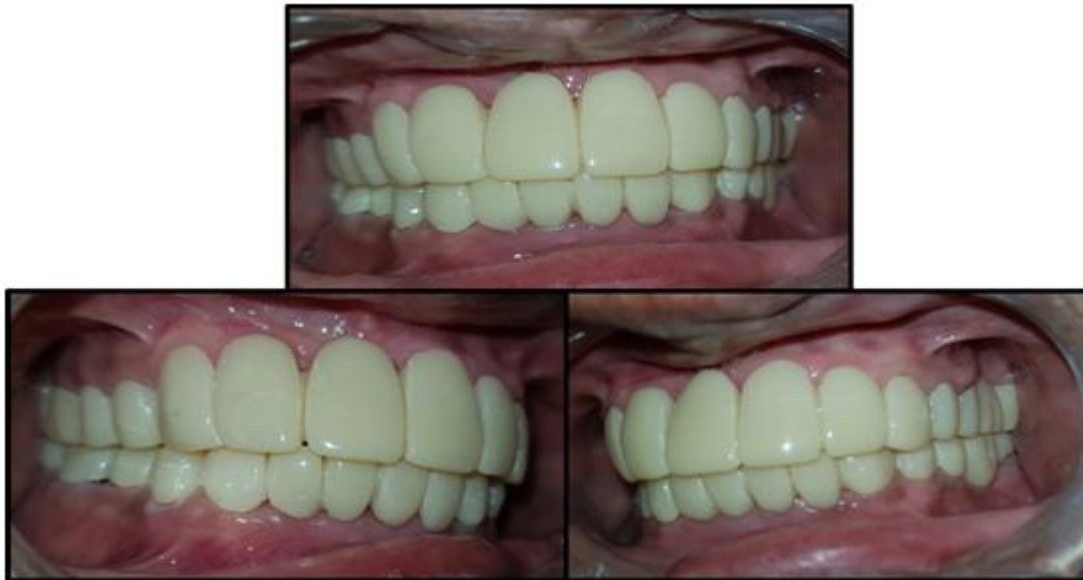

**Fig. 5 Provisionalization**

For 3 months, interim restorations were adjusted, and used as a guide for the definitive oral rehabilitation. During this period Muscle tenderness, discomfort of TMJ, mastication, range of the mandibular movements, swallowing, and speech, were evaluated. Improvement in function and esthetics confirmed the patient's tolerance to the new mandibular position with the restored VDO.

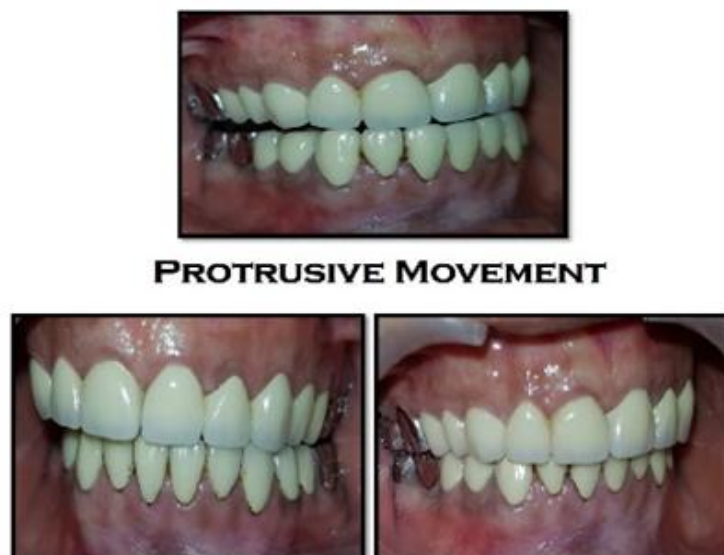

The anterior guidance and posterior disclusion on excursive movement were established. Adjusted occlusion was transferred to customized anterior guide table, which was made with acrylic resin (PATTERN RESIN; GC Corp, Tokyo, Japan) Porcelain fused to metal restorations were made using customized anterior guide table and cemented with resin modified GIC (FujiCEM; GC America, Alsip, USA).[Figure 6]



**Fig. 6 Final Cementation**

The prostheses were designed using mutually protected occlusion. The anterior teeth protected the posterior teeth from excursive force and wear, and posterior teeth supported the bite force. [Figure 7] Oral hygiene instruction and regular check-up were administered.



**Fig. 7 Protrusive and Lateral Excursive Movement**

### III. Discussion

Turner et al<sup>1</sup> in 1984 classified the treatment of a severely worn dentition by the amount of the loss of VDO and available space to restore. Till date his classification and conventional treatment, which includes raising VDO with multiple crown-lengthening procedures, have been widely used. Tooth wear is multifactorial condition and clinical controlled trials of prosthodontic approaches are limited in quantity and quality<sup>11</sup>. Because of the unclear guidelines, the use of adhesive strategy is increasing, which is more conservative and reversible,<sup>9,11,12</sup> In this second case composite resin restoration could not be used because the remaining tooth structures were too small to have sufficient retention of composite. Therefore, the conventional treatment that includes a trial splint, temporary restoration, careful observing, and final prosthesis, was selected.

In previous literature, the wearing time of overlay splint is between 3 weeks and 5 months, and provisional prostheses is 2 - 6 months.<sup>1,6,9,10,13</sup> In this case- 2, the patient was carefully monitored for 1 month to evaluate the removable splints.<sup>14</sup> Also the patient's adaptation to the provisional restoration was monitored for 3 months.<sup>15</sup>

Determination of VDO was done by patient's physiologic factor like interocclusal rest space and phonetics. If the increase of VDO was planned arbitrarily without proper evaluation, many complications would occur and whole treatment period might be become longer. There are mainly two philosophies of full mouth rehabilitation one is Pankey mann schuyler technique and second is Hobo's philosophy Twin stage technique. In the case one Hobo twin-stage technique was chosen and in the second condition where Pankey mann schuyler technique were chosen because It is well organized procedure that progresses smoothly with less wear and tear on the patient operator and technique.

According to Hobo technique, the incorporation of posterior disocclusion avoids harmful lateral forces. So in the twin-stage procedure, as cusp angle was the main determinant of occlusion; no need to record condylar path. This procedure is much simpler than the standard gnathological procedure, yet it follows gnathological principles. Hobo and Takayama studied the influence of condylar path, incisal path and the cusp angle was the most reliable determinant of occlusion. The Twin- stage procedure helps in achieving a standard disocclusion in eccentric and protrusive movements. There are certain contraindications of hobo technique like abnormal curve of spee and Wilson, abnormally rotated teeth and inclined teeth.

According to the Pankey mann schuyler technique, anterior teeth are usually restored first so as to achieve functional and esthetically viable anterior guidance. Anterior guidance plays a very significant role in rehabilitation of full mouth following centric relation. Anterior guidance forms the anterior control to provide posterior disclusion. It prevents posterior teeth from lateral or protrusive stresses. The facebow transfer is an essential to relate the anterior guidance with the opening and closing axis. It is required to reproduce the arc of closure from the patient to the articulator.

For replacing posterior teeth, Pankey and Mann introduced an instrument for occlusal plane analysis; in this case we used broad rick flag analyzer. This broad rick analyzer helps in establishment of the tooth morphology that compensates with the curve of spee when posterior restorations are designed. The patient had severely worn anteriors and wear facets on the canine. Hence group function occlusion was chosen to avoid functional overload on canines among all occlusal schemes Group function refers to the distribution of lateral forces to a group of teeth rather than assigning all forces to one particular tooth.

The provisional restorations plays a crucial role in the successful treatment of the full mouth rehabilitation patient. The provisional restorations should be esthetic and also fulfil the functions so that the effect can be followed in the temporary before making the final restoration.

Both the technique has its own advantages and disadvantages, so diagnosis and treatment planning is most important part of full mouth rehabilitation.

### IV. Conclusion

The restoration of form, function and esthetics in mutilated dentition is a demanding procedure and should be carried out only when absolutely indicated. Proper diagnosis and multidisciplinary treatment planning with adequate knowledge and judgement are paramount for success. The treatment should aim at restoring the occlusion to enhance mastication and improve the esthetic appearance. The present cases discussed the full mouth rehabilitation with both Pankey mann schuyler and Hobo twin-stage philosophy of occlusal rehabilitation.

### References

- [1]. Turner KA, Missirlian DM. Restoration of the extremely worn dentition. *J Prosthet Dent* 1984;52:467-74.
- [2]. Smith BG. Toothwear: aetiology and diagnosis. *Dent Update* 1989;16:204-12.
- [3]. Prasad S, Kuracina J, Monaco EA Jr. Altering occlusal vertical dimension provisionally with base metal onlays: a clinical report. *J Prosthet Dent* 2008;100:338-42.
- [4]. Dawson PE. *Functional Occlusion - From TMJ to smile design*. 1st ed. New York; Elsevier Inc.; 2008. p. 430-52.
- [5]. Dahl BL, Krogstad O, Karlens K. An alternative treatment in cases with advanced localized attrition. *J Oral Rehabil* 1975;2:20914.

*Rehabilitation of Severely worn dentition using full fixed prosthesis - An Systematic approach: Case*

- [6]. Jahangiri L, Jang S. Onlay partial denture technique for assessment of adequate occlusal vertical dimension: a clinical report. *J Prosthet Dent* 2002;87:1-4.
- [7]. Dahl BL, Krogstad O. Long-term observations of an increased occlusal face height obtained by a combined orthodontic/prosthetic approach. *J Oral Rehabil* 1985;12:173-6.
- [8]. Dahl BL. The face height in adult dentate humans. A discussion of physiological and prosthodontic principles illustrated through a case report. *J Oral Rehabil* 1995;22:565-9.
- [9]. Hemmings KW, Darbar UR, Vaughan S. Tooth wear treated with direct composite restorations at an increased vertical dimension: results at 30 months. *J Prosthet Dent* 2000;83:287-93.
- [10]. Sato S, Hotta TH, Pedrazzi V. Removable occlusal overlay splint in the management of tooth wear: a clinical report. *J Prosthet Dent* 2000;83:392-5.
- [11]. Johansson A, Johansson AK, Omar R, Carlsson GE. Rehabilitation of the worn dentition. *J Oral Rehabil* 2008;35:548-66.
- [12]. Darbar UR, Hemmings KW. Treatment of localized anterior toothwear with composite restorations at an increased occlusal vertical dimension. *Dent Update* 1997;24:72-5.
- [13]. Brown KE. Reconstruction considerations for severe dental attrition. *J Prosthet Dent* 1980;44:384-8.
- [14]. Ganddini MR, Al-Mardini M, Graser GN, Almog D. Maxillary and mandibular overlay removable partial dentures for the restoration of worn teeth. *J Prosthet Dent* 2004;91:210-4.
- [15]. Yunus N, Abdullah H, Hanapiah F. The use of implants in the occlusal rehabilitation of a partially edentulous patient: a clinical report. *J Prosthet Dent* 2001;85:540-3.

Dr. Shah Shikha".Rehabilitation of Severely Worn Dentition using Full Fixed Prosthesis - an Systematic Approach: Case Series." *IOSR Journal of Dental and Medical Sciences (IOSR-JDMS)*, vol. 18, no. 7, 2019, pp 01-10.

Dr. Shah Shikha. "Rehabilitation of Severely worn dentition using full fixed prosthesis - An Systematic approach: Case Series." *IOSR Journal of Dental and Medical Sciences (IOSR-JDMS)*, vol. 18, no. 7, 2019, pp 11-15