

## Dentigerous CYST of Ectopically Positioned Maxillary Canine Associated with Multiple Impacted Teeth –A Case Report with a Follow Up of Two Years

Dr. K. Subalakshmi, MDS., OMFS, Dr. M.R.K. Rajaselvam MS., ENT,  
Dr. J. Jayakumar, DLO., MD PG, Dr. R. Loganayagi, MDS.

1. Senior Assistant professor, Department of Dental Surgery, Govt Tiruvannamalai Medical College and Hospital

2. Assistant Professor, Department of ENT, Govt Tiruvannamalai Medical College and Hospital

3. PG Department of Forensic Medicine, Madras Medical College, Chennai

4. Senior Resident, Department of Dental Surgery, Govt Tiruvannamalai Medical College and Hospital.

Corresponding Author: Dr. M.R.K. Rajaselvam

**Abstract:** The most common developmental odontogenic cyst of oral cavity is dentigerous cyst, otherwise it is called as follicular cyst. In 1853 Pagets was first one to introduce a term dentigerous cyst. It is nothing but fluid collection between unerupted tooth and follicular space. Usually it is an incidental finding. Sometimes it may be large and pain full, most of the time it is asymptomatic. Very rare in deciduous dentition, common in permanent dentition. Common finding in mandible about 70%, and 30% occurs in maxilla. Commonly involved impacted teeth are third molar, canine, 2<sup>nd</sup> premolar. The present case report is about a girl child patient aged 11 years with facial asymmetry. Clinical and radiological examination shows impacted maxillary right central, lateral incisor and ectopically positioned maxillary canine near the maxillary sinus associated with the dentigerous cyst. Surgical enucleation was carried out and follow up of the patient for two years was carried out to assess the remodelling of maxillary bone.

**Keywords:** Dentigerous cyst, Impacted canine, Maxillary sinus, ectopic tooth.

Date of Submission: 15-07-2019

Date of acceptance: 30-07-2019

### I. Introduction

Dentigerous cyst is the most common benign odontogenic lesion in mandible<sup>3</sup>. Its occurrence in maxillary sinus is very rare in nature. It is most common in ectopically placed maxillary third molar impaction in maxillary sinus and rare in ectopic canine impaction and impaction of central incisors<sup>4</sup>. Commonly it was asymptomatic unless otherwise secondarily infected and due to buccal cortex expansion and destruction of adjacent tissues. Symptoms arises due to secondary infections such as purulent rhinitis, facial pain, external nasal deformity, epiphora etc. Clinically missing impacted tooth, ectopic eruption of non dentoalveolar region is very rare<sup>1</sup>. Some of the differential diagnosis are, Unicystic ameloblastoma, Gorlin cyst, Ameloblastic fibro odontoma, Odontogenic keratocyst. Ameloblastic fibro odontoma is very rarely present in maxillary sinus.

### II. Case Report

A 11 year old female child reported to the Department of Dental Surgery, Government Tiruvannamalai Medical College and Hospital with the complaints of swelling in the right side of face. History revealed a slowly growing swelling for the past three months and attained to the present size of 4x4cm. The swelling is diffuse, firm in consistency, painless on palpation with obliteration of nasolabial fold was noted. Intraorally, unerupted maxillary right central, lateral incisor, mobile primary canine and first molar with obliterated buccal sulcus was seen. On aspiration of the swelling, a straw colour fluid was present. There was no previous history of trauma.

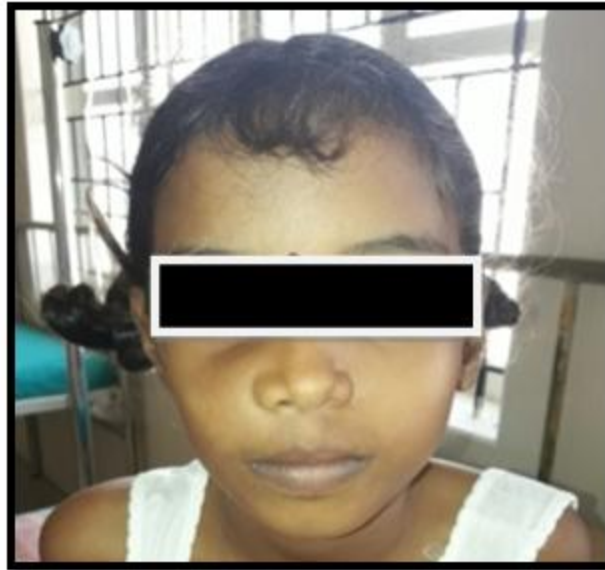Patient was advised for OPG and CT facial bone with 3D reconstruction. OPG revealed malpositioned right central, lateral incisor and ectopically positioned maxillary canine near the maxillary sinus. CT facial bone shows well defined unilocular radiolucent lesion with thin labial sclerotic border extending to maxillary sinus was observed. It was found to be associated with maxillary permanent central, lateral incisor and canine. Buccal cortical expansion was present.

We planned for enucleation of cyst under General anesthesia with all routine blood investigation. Creviceular incision was made from 21 to 16 region and releasing incision was made anteriorly. Mucoperiosteum flap reflected and cystic wall was identified. Extraction of deciduous canine, first and second molars, first premolar was done along with the enucleation of cyst with its impacted canine and incisors. Adequate irrigation

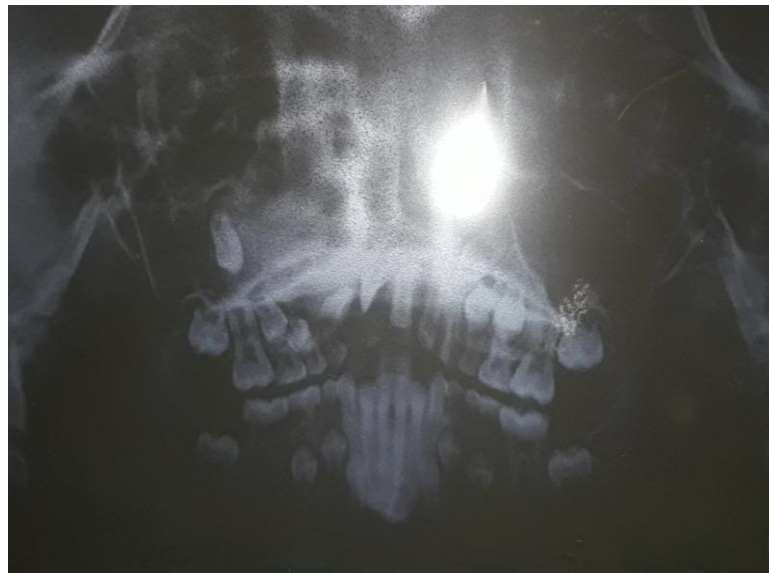was made, haemostasis achieved and primary closure was made with 3-0 vicryl. Specimens were sent for histopathological examination.

Histological examination showed a thin fibrous cystic wall lined by a 2 to 3 layer thick nonkeratinized stratified squamous epithelium and the connective tissue showed a slight inflammatory cell infiltrate confirming the diagnosis of dentigerous cyst.

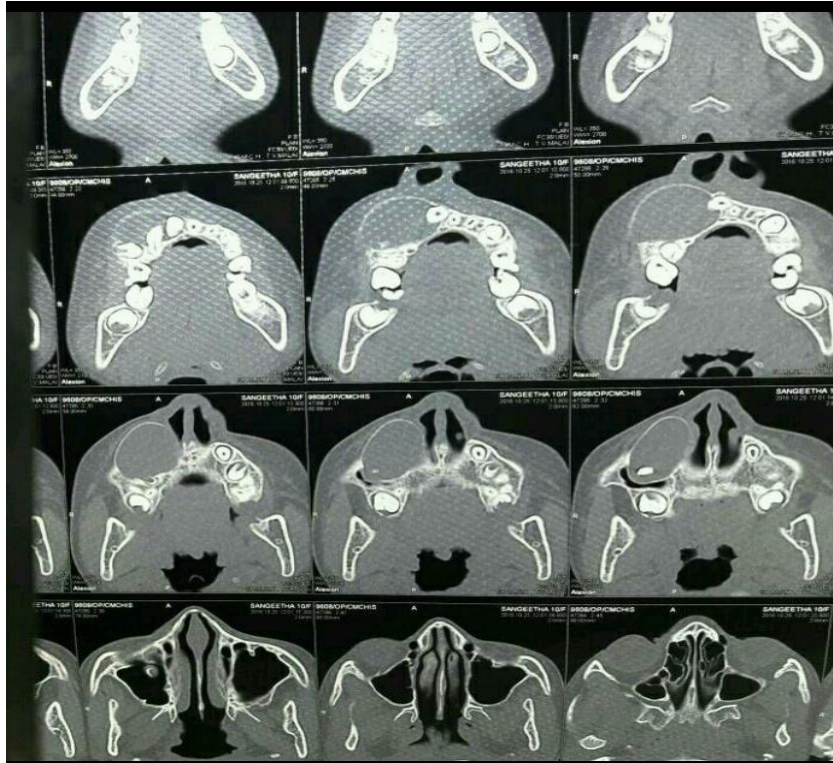Post operative healing was found to be uneventful. We have followed the patient with good prognosis for two years . CT facial bone was taken at a duration of 6 months, one year and second year post operative period. Bone remodelling was observed in relation to maxillary sinus and there is no evidence of recurrence, buccal cortical bone expansion. Patient has been rehabilitated with a removable partial denture and the facial profile found to be improved. Since the patient was in active growth period, bone healing was good and remodelling also favourable.



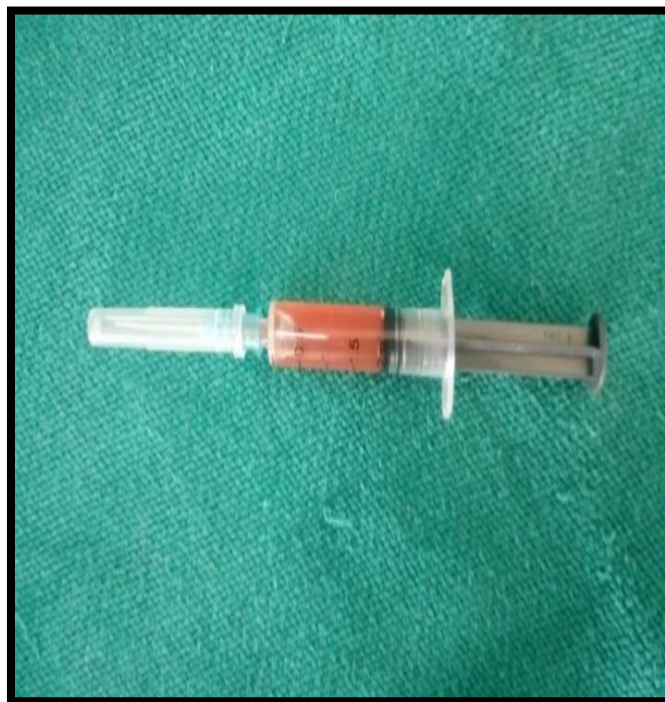**Figure 1:** Extraoral photograph of the patient



**Figure 2;** Preoperative OPG showing impacted permanent incisors, ectopically erupted canine

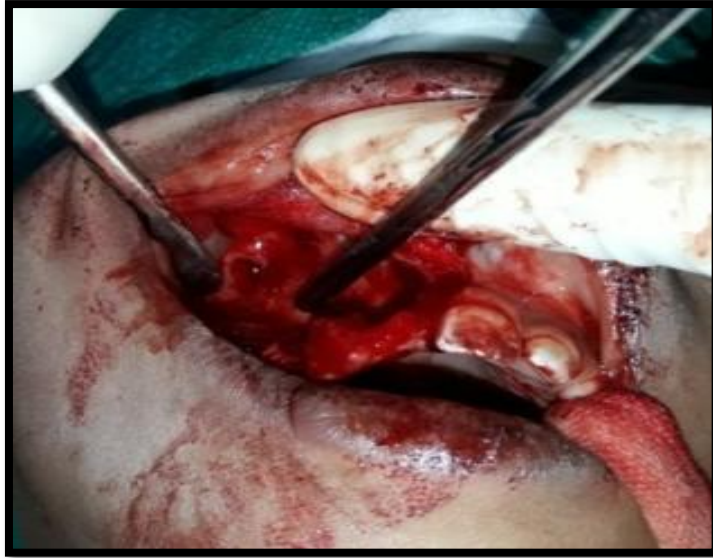

**Figure 3;** Preoperative CT scan revealing buccal cortical bone expansion with the impacted ectopically placed canine in maxillary sinus.

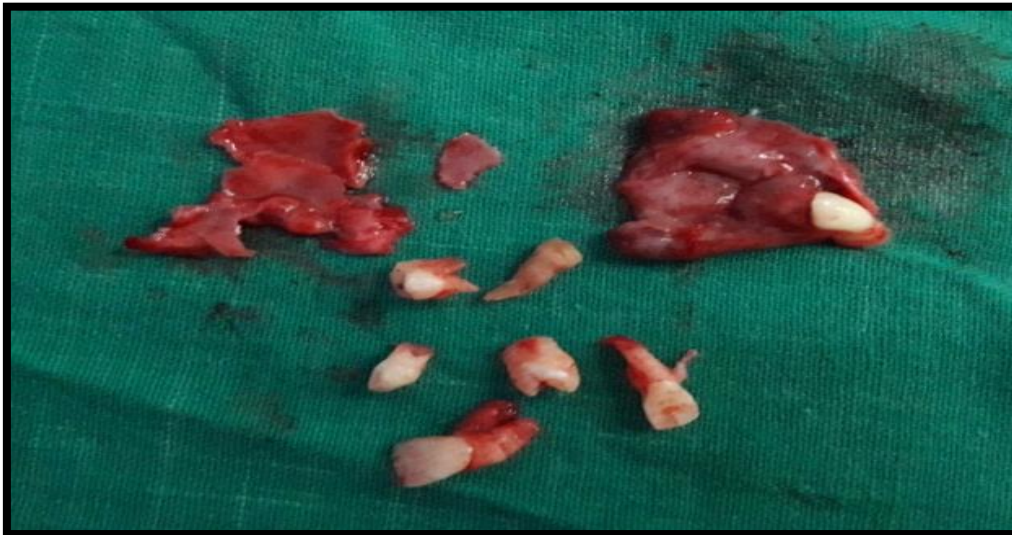

**Figure 4;** Photograph of aspirated straw colour cystic fluid

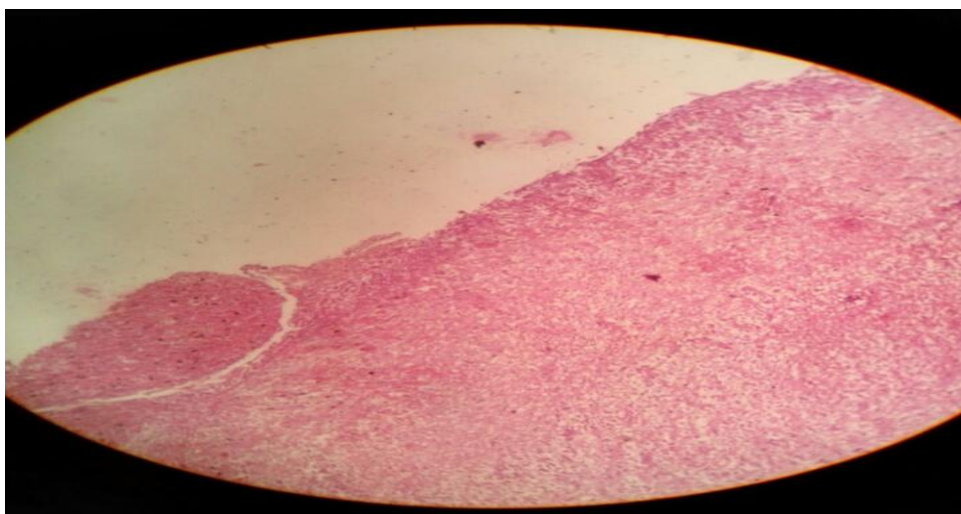




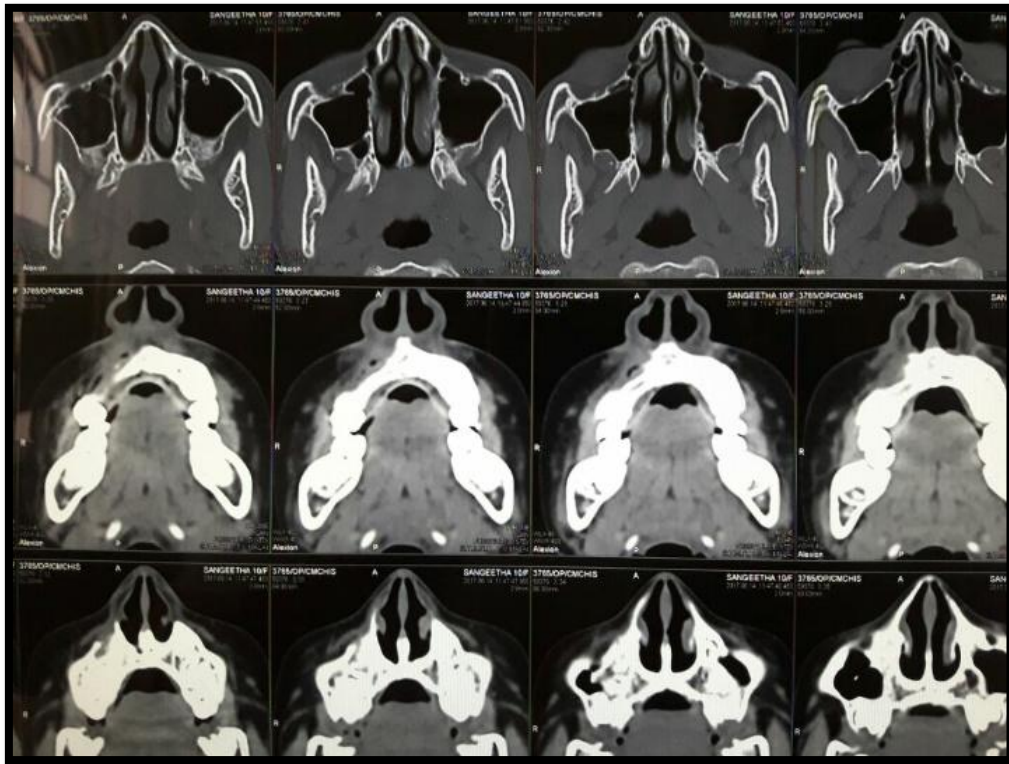
**Figure 5;** Peroperative photograph after cyst enucleation



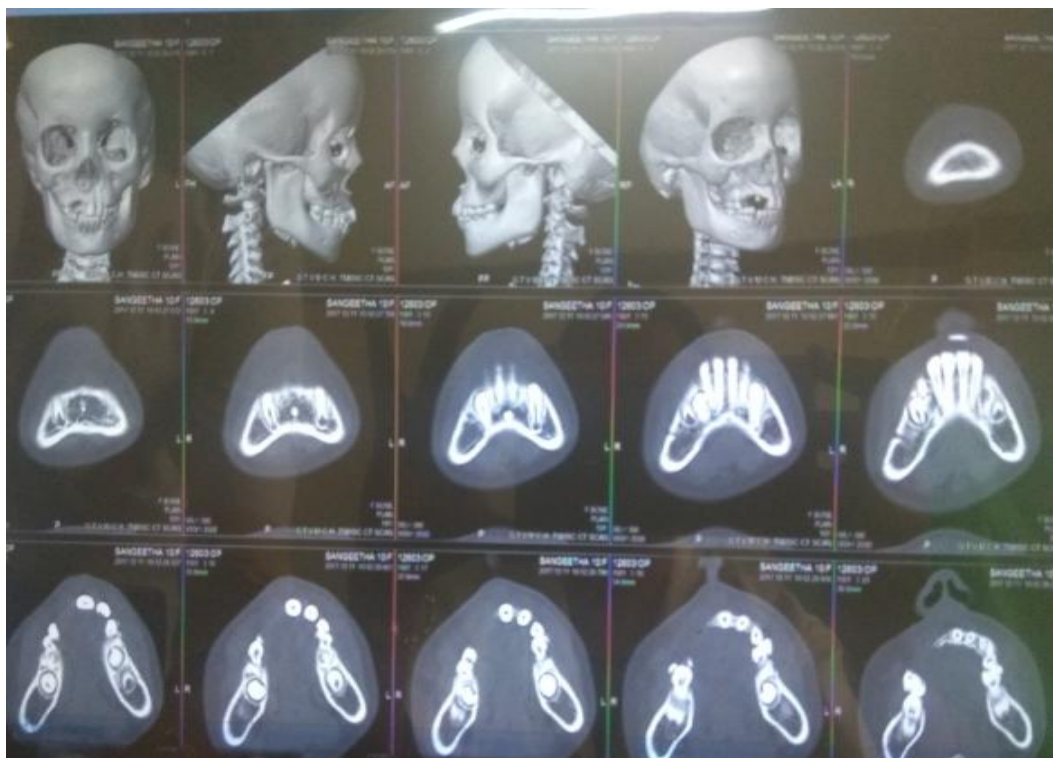
**Figure 6;** Photograph of cystic lining with its extracted teeth



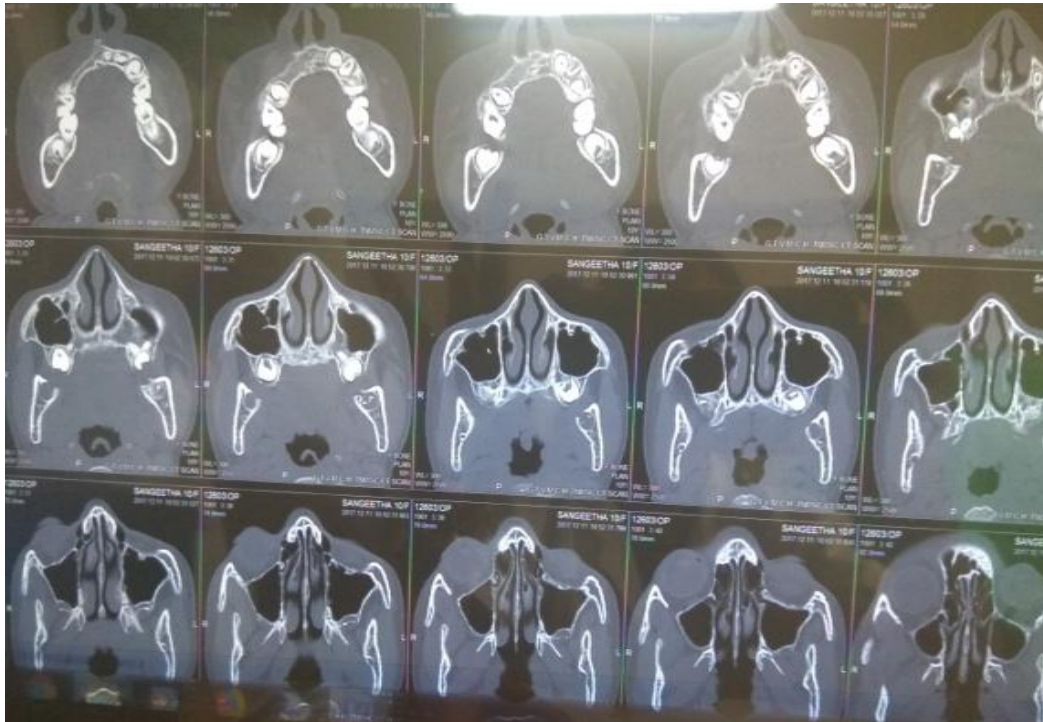
**Figure 7;** Histopathological section of the lesion



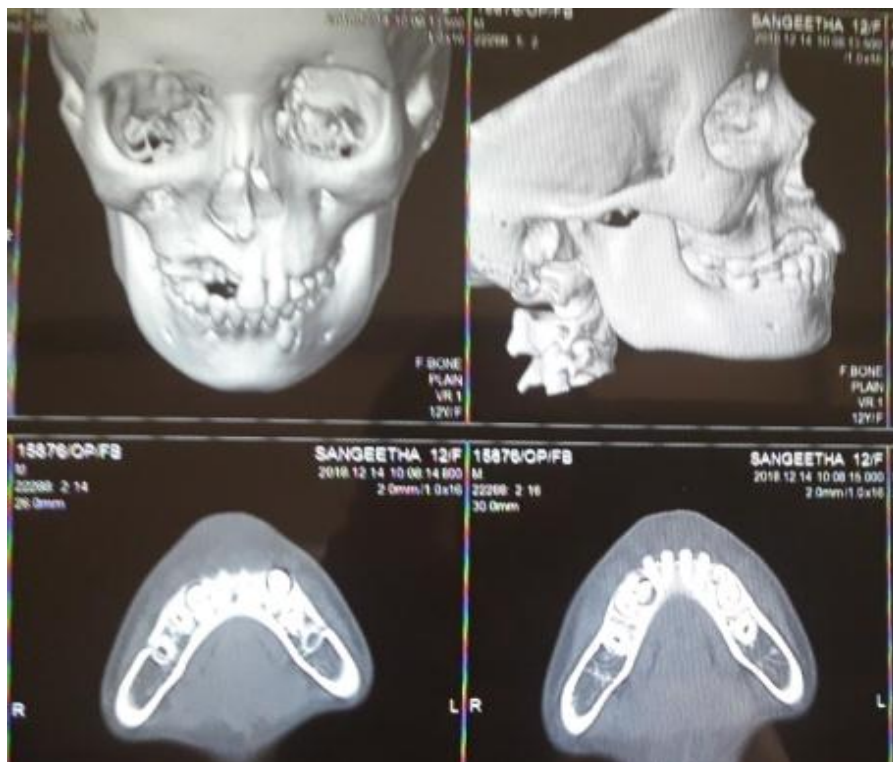
**Figure 8;** Postoperative CT after 6 months

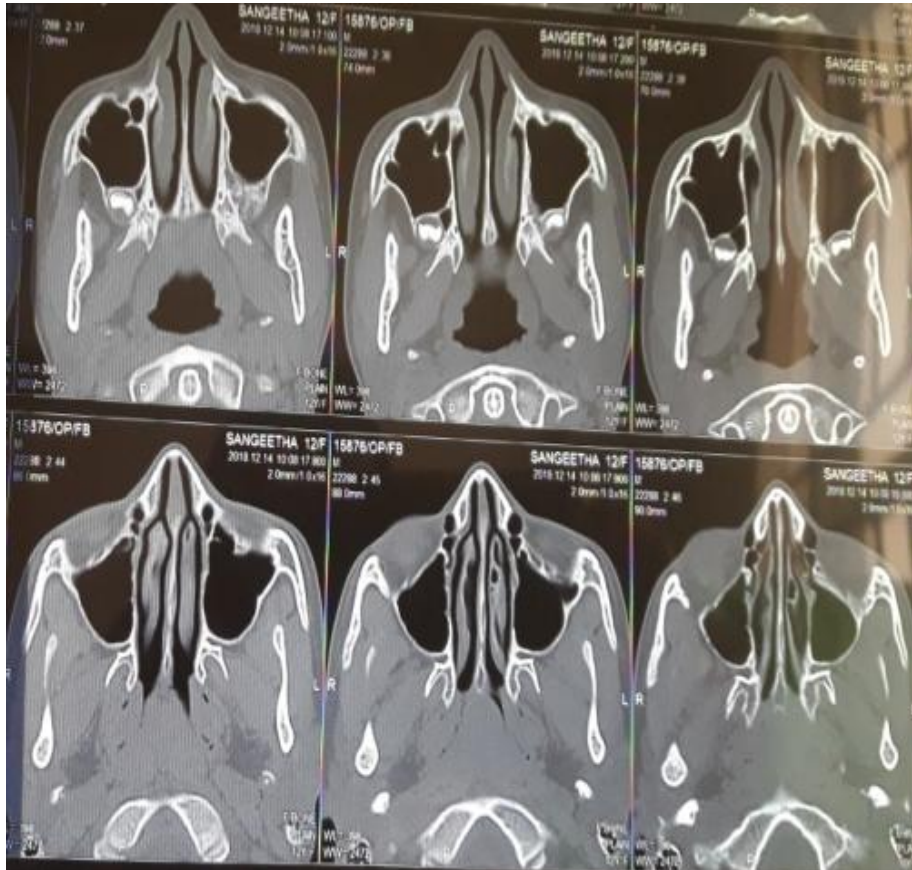




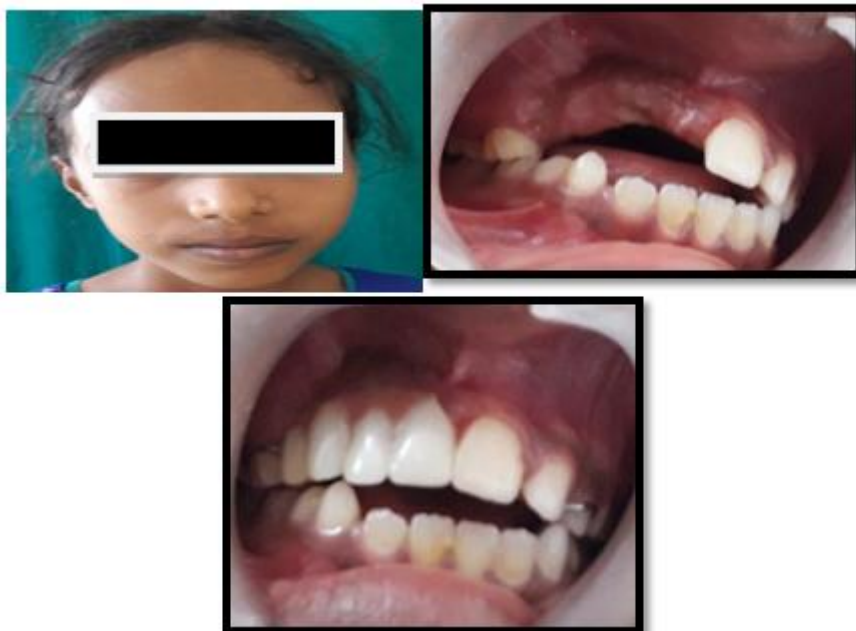

**Figure 9;** Postoperative CT after one year





**Figure 9;** Post operative CT after 2 years showing good remodelling of maxillary bone



**Figure 10;** Extraoral and intraoral postoperative view with partial denture replacement

### III. Discussion

Ectopic eruption is usually seen in oral cavity, although they are seen rarely in different regions of jaws such as coronoid process, mandibular condyle, Nasal septum, palate, and maxillary sinus. The etiology of ectopic eruption of tooth is unknown.

Many theories have been proposed for dentigerous cyst which are infection, trauma, genetic factor, developmental anomalies, iatrogenic activity, idiopathic etiology and pathologic conditions. It is stated that the dentigerous cyst develops around the crown of an unerupted tooth by accumulation of fluid which may be due to the pressure exerted by an erupting tooth on an impacted follicle<sup>5</sup>. This obstructs the venous outflow and thereby induces rapid transudation of serum across the capillary wall. In another theory, Bloch<sup>6</sup> suggested that the origin of the dentigerous cyst is from the overlying necrotic deciduous tooth. The resultant periapical inflammation will spread to involve the follicle of the unerupted permanent successor: an inflammatory exudate ensues and results in dentigerous cyst formation. Most of the authors<sup>7,8</sup> have reported the presence of carious or discolored deciduous teeth in relation to the development of dentigerous cysts, which correlate with our case report.

The radio opaque image of ectopic teeth are clearly diagnosed radiographically. CT imaging is gold standard for to designate the definite localization. Odontogenic keratocyst, radicular cyst, pindborg's tumor, adenomatoid odontogenic tumor, ameloblastoma, calcifying odontogenic cyst, and ameloblastic fibroma may present same radiographic property. Therefore histopathological investigation is necessary for final diagnosis.

Histologically, dentigerous cysts are lined by a layer of non keratinized stratified squamous epithelium, with a surrounding wall of thin connective tissue containing odontogenic epithelial rest.

The epithelial cells lining the lumen of the dentigerous cyst possesses an unusual ability to undergo metaplastic transition<sup>9</sup>. The standard treatment for a dentigerous cyst of maxilla is enucleation and extraction of the associated tooth via a Caldwell-Luc procedure under local or general anesthesia. In large cysts, an initial marsupialisation to diminish the size of osseous defect, followed by enucleation and tooth extraction has been followed. The major disadvantage of Marsupialization is recurrence. Endoscopic approach for management of dentigerous cyst of maxilla is also described in the literature. This method is associated with lesser operative as well as postoperative morbidity.

### IV. Conclusion

Though dentigerous cysts are common in mandibular jaw, in the present rare case maxillary jaw was involved affecting impacted incisors and ectopically placed canine tooth. Early diagnosis and management favours healing and our follow up of two years shows good remodelling of alveolar bone, which might be probably due to young growing period of the patient. A dentigerous cyst associated with an anterior tooth will result in failure of eruption of the tooth and therefore lead to esthetic and orthodontic problems which might have an impact on the psychology of the child. Hence esthetic management was done in our case with a removable partial denture which satisfies our patient.

### References

- [1]. Beriat GK, Beriat NC, yalcinkaya. Ectopic molar tooth in maxillary sinus. a case report.
- [2]. Mahesh KR, Umashankar DN, Nandakumar H, Radhika BM, sudhakar. Inflammatory variant of dentigerous cyst in maxillary sinus. A case report. *Int J Oral Maxillofac pathol.*2010;1:17-9.
- [3]. M.Isa Kara, Saim Yanik, Ahmed Altan. Large dentigerous cyst in the maxillary sinus leading to Diplopia and Nasal obstruction.
- [4]. Yadavalli Guruprasad, Dinesh Singh chauh, Umashankar Kura. Infected dentigerous cyst of maxillary sinus arising from an ectopic third molar.
- [5]. Main DM. The enlargement of epithelial jaw cyst. *Odontol Revy* 1970;21:21-9
- [6]. Bloch JK. Dentigerous cyst. *Dent Cosm* 1978;70: 707-11
- [7]. Mourshed F. A roentgenographic study of dentigerous cyst II: Role of roentgenograms in detecting dentigerous cyst in the early stages. *Oral Surg* 1964;18: 54-61
- [8]. Daley TD, Wysock GP; The small dentigerous cyst. the diagnostic dilemma. *Oral Surg Oral Med Oral Pathol Oral Radiol* 1995;79:77-81
- [9]. Sloomweg DJ. Carcinoma arising from reduced enamel epithelium. *J Oral Pathol* 1987;16:479-82.

Dr. K. Subalakshmi. "B Scan of Orbit with Its Clinico-Surgical Correlation." *IOSR Journal of Dental and Medical Sciences (IOSR-JDMS)*, vol. 18, no. 7, 2019, pp 32-39.