

## Prospective Study on Unreamed Interlocking Nail for Open Tibial Fractures

Dr.P.Anil Babu M.S.(Ortho.)<sup>1</sup>, Dr. K.Sudhakar M.S.(Ortho.)<sup>2</sup>, Dr Simon Neal <sup>3</sup>,  
Dr D.Venkateswara Rao M.S.(Ortho.)<sup>4</sup>, Dr C.Syam Kumar M.S.(Ortho.)<sup>5</sup>,  
Dr.A.Srinivasa Rao M.S.(Ortho.)<sup>6</sup>

<sup>1</sup>Associate Professor of Orthopaedics, Siddhartha Medical College, Vijayawada.A.P(First Author)

<sup>2</sup>Assistant Professor of Orthopaedics, Siddhartha Medical College, Vijayawada.A.P.

<sup>3</sup>Post Graduate in M.S(Ortho.) Siddhartha Medical College, Vijayawada

<sup>4</sup>M.Ch.(Ortho.) Professor of Orthopaedics, Siddhartha Medical College, Vijayawada

<sup>5</sup> Professor of Orthopaedics, Siddhartha Medical College, Vijayawada

<sup>6</sup>M.Ch.(Ortho.) Associate Professor of Orthopaedics, Siddhartha Medical College, Vijayawada

Corresponding Author: Dr.K.Sudhakar M.S.(Ortho.)

---

**Abstract:** The tibial shaft is one of the most common sites of open fractures. The specific methods of skeletal stabilization and soft tissue treatment of open fractures continue to be topics of debate in the orthopaedic traumatology. The aim of the study is to evaluate the results of the unreamed intramedullary nailing in the open fractures of the tibia. Unreamed nailing in open fractures can avoid known complications of reamed nailing in an open fracture.

---

Date of Submission: 06-05-2019

Date of acceptance: 20-05-2019

---

### I. Introduction

The open fractures of tibia contribute to majority of open fractures. Due to mechanisation and high velocity road traffic accidents, these fractures are now encountered in almost all age groups. There are multiple treatment options for fractures of tibia, but there are few options for open fractures<sup>1</sup>.

The soft tissue cover and the fracture union are not guaranteed and they are the same for every open fracture. They are more prone for infections and issues in union. External fixation has got its own limitations when extensive soft tissue damage is encountered, where the pin placement may further jeopardise either soft tissue cover or stability of the construct, even when pin placement is possible on intact skin, the fracture is at disadvantage by stability and compression at the fracture site.

Intramedullary nail fixation is gaining popularity as the option along with or without primary soft tissue cover<sup>2</sup>. There are multiple contributing factors that result in a poor prognosis in the final soft tissue cover achieved and the union of the fracture<sup>3</sup>. The essential components of the treatment are (1) intravenous antibiotics at first evaluation (2) Acute surgical Debridement and whenever required further; (3) Rigid skeletal stabilization as early as possible (4) Appropriate soft-tissue coverage depending on viability, and (5) Gap dependant bone grafting. While taking the essential components into consideration, the debatable options available are stabilization, such as external fixation (EF), intramedullary nailing (IMN), plating, or Ender nailing, is appropriate for immediate stabilization in open tibial fractures. Whether reamed or unreamed nailing is appropriate in the use of IMN? What kind of soft-tissue injury grade is the limit in immediate IMN? When should soft-tissue cover be performed? When is appropriate conversion to IMN from EF? The usual infections expected are, A superficial wound infection, located entirely above fascia with erythema and tenderness that requires antibiotic therapy and exploration of wound. A deep infection involving bone is defined as infection involving tissue below the muscular fascia<sup>4</sup>. The three measures of final outcome were deep infection, nonunion, and healing time to union.

Despite modern advances in fracture care, deep (implant-related) infection remains a problem in the treatment of tibia fractures. There is some evidence that antibiotic coated implants are beneficial in the prevention of this sometimes devastating complication. Treatment indications for this included acute, Gustilo grade II-III, open tibia fractures or closed tibia fractures with long-term external fixation prior to intramedullary nailing and complex tibia fracture revision cases with a mean of three prior surgical interventions. Outcome can be greatly affected deep infection and nonunion<sup>5</sup>.

Controversy exists regarding the clinical outcomes of reamed vs unreamed intramedullary nailing in the treatment of closed tibial fractures. Primary outcomes were nonunion, delayed union, malunion, secondary

procedure, failure of implants, compartment syndrome, infection, and knee pain<sup>6</sup>. Evidence comparing reamed with unreamed intramedullary nailing for closed tibial fractures indicates that reamed intramedullary nailing may lead to significantly lower risks of nonunion, screw failure<sup>7</sup>.

Intramedullary nailing is commonly used for treating fractures of the tibial shaft. These fractures are one of the most common long bone fractures in adults. Randomised and quasi-randomised controlled clinical studies were done evaluating different methods and types of intramedullary nailing for treating tibial shaft fractures in adults. Primary outcomes were health-related quality of life, patient-reported function and reoperation for treatment failure or complications<sup>8</sup>.

However, debates remain between reamed and nonreamed intramedullary nailing. The advocates of reaming regard that it can increase the stability of fractures and reamed bone debris can contribute to the fractures as bone graft. Williams *et al.* report that a high rate of union (98%) is achieved with reamed intramedullary nailing. Wiss and Stetson regard that reamed intramedullary nailing is a safe and effective method of treatment for tibial nonunions of previously closed fractures and prior open fractures. The objectors propose that reaming will destroy the blood vessels, increase pressure within the medullary cavity and stimulate the formation of vascular thrombosis. Pfister considers that nonreamed nailing is favoured especially in German-speaking countries due to slightly simple operation procedure, but it remains the method of first choice for treatment of a hypertrophic non-union of the shaft of the long bones. Reamed intra medullary nailing has observed to produce better outcomes in terms of fracture union on closed fractures. Krettek recommends nonreamed interlocking nailing for closed tibial fractures with severe soft tissue injury because of low infection and low nonunion rate.

## II. Materials And Methods

An observational, descriptive study is designed for evaluating the fracture union and soft tissue healing in 60 open fractures of tibia at Dept. of Orthopaedics, SMC, Vijayawada. The inclusion criterion are (a) the patients who presented with open fractures of the tibia within the first 48 hours of being injured, (b) more than 15 years of age (c) diaphyseal fractures of tibia (d) open fractures with no loss of soft tissue were included in the study. Exclusion criterion are the patients with (a) fractures of the tibia within the proximal fourth of the tibia or within four centimeters of the ankle joint (b) Associated vascular injuries (c) loss of bone or (d) multiple fractures (e) segmental fractures.

The patients are sufficiently stabilized in the emergency department. Care full clinical examination and skeletal survey are done to identify any concomitant injuries. The general measures taken in the emergency department include iv fluids, adequate analgesia, tetanus prophylaxis and injection Cefazolin 1 gm, injection Amikacin 500 mg, thorough wound lavage with normal saline and sterile dressings are applied.

After a routine pre operative workup, the patient is subjected to pre anaesthetic check up, and taken up for an unreamed tibial intramedullary nailing by using image intensifier guidance. An 8-mm diameter nail was used predominantly and 9mm in wider medullary canals. Before the fracture fixation the open wound is lavaged several times till all the blood clots are evacuated and loosely hanging soft tissue is excised. The wound margins are freshened till fresh bleeding is encountered. Both proximal and distal interlocking were done by using two screws for each and in dynamic mode for transverse and short oblique fractures. The wound was closed in layers to cover the bone, wherever possible. The intravenous antibiotics were continued for seven days. Physiotherapy was instituted from the third postoperative day, depending on the type of fracture, the requirement for plastic surgery and the presence of other injuries.

The patients with the isolated type I, II and IIIA fractures that did not require plastic surgeries, were mobilized with appropriate walking aids, as soon as the pain permitted. Mobilization was started with a non-weight bearing crutch support walking, followed by a toe touch crutch support walking and progressive weight bearing, depending upon the callus formation. The patients with split skin grafts or skin flaps were mobilized as soon as the states of the soft tissues permitted.

The patients were followed up at monthly intervals for 3 months or till callus formation is observed. In every follow up, the patients were assessed both clinically and radiologically for infections and the union and the range of motion at the knee and the ankle.

The mean Injury Severity Score (ISS) of the 60 patients was 11 (range, 9–27). The 60 open tibial fractures were classified according to the criteria of Gustilo *et al.*: type I, 26 fractures; type II, 12 fractures; type IIIA, 8 fractures; type IIIB, 14 fractures.

The closure of the wound was done by primary closure, secondary closure with a lateral skin release, secondary closure with a split thickness skin grafting. The soft-tissue managements in the present series were as follows: primary suture (n = 38) delayed primary suture (n = 10) secondary split-thickness skin grafting (STSG) (n = 12) The primary sutures were performed in many cases of types I and II. The soft-tissue management in type IIIA consisted of primary sutures or delayed primary sutures, and that in type IIIB consisted of local or free flaps.

### **III. Results**

The average time to union was 17.0 weeks in the grade I cases, it was 18 weeks in the grade II cases, it was 23 weeks in the grade III A cases, it was 28 weeks in the grade III B cases and it was 32 weeks in the grade III C cases. No case had any implant failure (nail / screw breakage), or deep vein thrombosis. There was a marginal flap necrosis in 3 cases, but all of them were managed by debridement and re-suturing.

The wound related issues are seen more with type III fractures. And type II fractures where skin margins could not be approximated. However these cases required re exploration of the soft tissue wound and secondary closure with a gap of 7 -10 days. Bony union was defined as follows: clinically, there was no pain or tenderness, and the patient walked without aids; radiographically, solid bridging callus had connected the fracture fragment on both anteroposterior view and lateral view.

### **IV. Discussion**

Sargeant et al., suggested that cortical necrosis is less likely to occur with a loosely fitted intramedullary nail than a snugly fitted reamed nail. Reaming of the open fractures has been found to spread the contamination from the open wounds along the medullary canal and to strip the small fragments of bone from the soft tissue attachments.

Because the mechanical strength of the nail is proportional to its diameter, these 8-mm diameter nails are relatively weak, particularly in the bending mode. The nails at the site of the locking holes are also more prone to breaks, because the stresses are concentrated at the screw hole junctions and at the sites of the empty holes which are not filled by bolts. The minimal endosteal contact of these unreamed nails further concentrates the stresses at the screw hole junctions, which could be responsible for the nail failure or screw breakage.

Hahn et al., advocated a cautious approach for such fractures by filling all the screw holes with bolts, to reduce the concentration of the stress distally. In our series, both the proximal and the distal interlocking holes were interlocked with two screws in the proximal and distal fragments and there were no case of any nail or screw breakage.

In our series, Anterior Knee Pain was observed. Court-Brown et al., reported a 36% incidence of anterior knee pain and they advocated the techniques of using a more proximal and a lateral entry point, hyper flexing the knee during the nail insertion and extending the knee during the screw insertion to lessen the irritation of the overlying tendons.

We recorded restricted motions at the knees and restricted motions at ankles . Joshi et al., reported knee stiffness in a similar study. This incidence can further be reduced with an early institution of knee and ankle mobilization with the use of quadriceps drill exercises.

In the presence of significant trauma to the local tissues, any operative intervention such as a plate or a screw fixation can further devitalize the already compromised tissues. Therefore, it is extremely important to avoid such operative interventions for preventing sepsis and for promoting the healing of the tibial fractures.

Our results show that the aggressive management of the severe open fractures among the tibial fractures is effective. We accept that this approach is radical and that it has been claimed that an immediate soft tissue coverage is not safe. However, the analysis of our results showed good union rates and low rates of infections, thus supporting the concept that a delay is not necessary if the healthy soft tissues can be imported reliably into the zone of the injury.

Overall, these results show that in the grade I and II open tibial fractures, a primary unreamed intramedullary nailing can be safely done, with minimal complications and excellent functional results. For the grade III open fractures of the tibia, the modern techniques of management, combined with the skills of experienced orthopaedic and plastic surgeons, can consistently restore excellent limb functions in a very high proportion of patients. In some of the most severely injured limbs, a salvage is possible and a useful functional limb can be obtained, as was shown in our study.

It is important to analyze such cases of compound injuries when they come to us in emergency. Such cases should be taken up only if the centre has both orthopaedic and plastic surgeons' skills available and then a fairly good outcome can be expected.

### **V. Conclusions**

We conclude that unreamed intramedullary nailing in cases of open fractures of the tibia, with an early soft tissue coverage, results in faster soft tissue and bony healing, an easier soft tissue coverage, a better biomechanical stability and early rehabilitations and infection rates as compared to other methods. Reamed intramedullary nailing has, however, a lower incidence of implant failure than unreamed nailing.

Musculoskeletal complications place a cost burden on total healthcare expenditure. Better understanding of the epidemiology and pathogenesis is essential because this can lead to prevention rather than treatment strategies.

There were no statistically significant delay is seen in open fractures though there are chances of nonunion, deep infection, implant failure, compartment syndrome. Sargeant et al., suggested that cortical necrosis is less likely to occur with a loosely fitted intramedullary nail than a snugly fitted reamed nail. Reaming of the open fractures has been found to spread the contamination from the open wounds along the medullary canal and to strip the small fragments of bone from the soft tissue attachments.

As smaller diameter of 8-mm diameter nail was used for cases in our series, because of the narrow medullary canals of the relatively small-built Indian patients as compared to those of their western counterparts. Because the mechanical strength of the nail is proportional to its diameter, these 8-mm diameter nails are relatively weak, particularly in the bending mode. The nails at the site of the locking holes are also more prone to breaks, because the stresses are concentrated at the screw hole junctions and at the sites of the empty holes which are not filled by bolts. The minimal endosteal contact of these unreamed nails further concentrates the stresses at the screw hole junctions, which could be responsible for the nail failure or screw breakage. It was easier for us to do soft tissue procedures, as there were no external fixator frames around the injured legs.

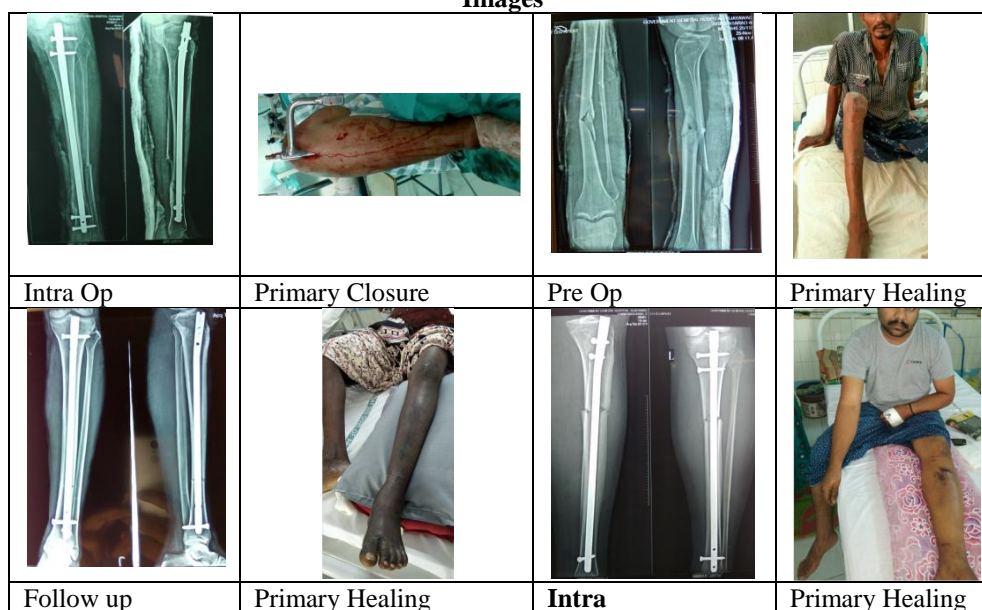
**Table 1: Incidence and fracture union**

Type of open #	No.:
Gustillo Type I	26
Gustillo Type II	12
Gustillo Type IIIA	8
Gustillo Type IIIB	14

**Table 2: Soft tissue cover**

Type of closure	No.:
Primary	38
Secondary	10
Split skin	12

**Images**



**References**

- [1]. Atul Agrawal, Vijendra Devisingh Chauhan, Rajesh K. Maheshwari, Anil Kumar Juyal. Primary Nailing in the Open Fractures of the Tibia-Is it worth? Journal of Clinical and Diagnostic Research. 2013 June, Vol-7(6): 1125-1130 DOI:10.7860/JCDR/2013/5504.3081
- [2]. Tielinen L, Lindahl JE, Tukiainen EJ. Acute unreamed intramedullary nailing and soft tissue reconstruction with muscle flaps for the treatment of severe open tibial shaft fractures. Injury. 2007 Aug;38(8):906-12. Epub 2007 Jun 15.
- [3]. Ostermann PA, Knopp W, Josten C, Muhr G. Unreamed intramedullary nail or external fixator in complicated tibial fracture? A comparative analysis. Chirurg. 1993 Nov;64(11):913-7.
- [4]. Kazuhiko Yokoyama, Moritoshi Itoman, Masataka Uchino, Kensuke Fukushima, Hiroshi Nitta, and Yoshiaki Kojima Immediate versus delayed intramedullary nailing for open fractures of the tibial shaft: A multivariate analysis of factors affecting deep infection and fracture healing. Indian J Orthop. 2008 Oct-Dec; 42(4): 410-419. doi: 10.4103/0019-5413.43385
- [5]. Metsemakers WJ, Reul M, Nijs S. The use of gentamicin-coated nails in complex open tibia fracture and revision cases: A retrospective analysis of a single centre case series and review of the literature. Injury. 2015 Dec;46(12):2433-7. doi:10.1016/j.injury.2015.09.028. Epub 2015 Oct 8.

- [6]. Duan X , Al-Qwbani M, Zeng Y, Zhang W, Xiang Z. Intramedullary nailing for tibial shaft fractures in adults.Cochrane Database Syst Rev. 2012 Jan 18;1:CD008241. doi: 10.1002/14651858.CD008241.pub2.
- [7]. Xia L, Zhou J, Zhang Y, Mei G, Jin D. A meta-analysis of reamed versus unreamed intramedullary nailing for the treatment of closed tibial fractures. Orthopedics. 2014 Apr;37(4):e332-8. doi: 10.3928/01477447-20140401-52.
- [8]. Chun-xiao Li, Hong-jing Zhao, Wan-qiu Zhao, Yong-qing Xu II System evaluation on reamed and non-reamed intramedullary nailing in the treatment of closed tibial fracture 1744 - Acta Cirúrgica Brasileira - Vol. 28 (10) 2013

Dr.P.Anil Babu M.S.(Ortho.). “Prospective Study on Unreamed Interlocking Nail for Open Tibial Fractures.” IOSR Journal of Dental and Medical Sciences (IOSR-JDMS), vol. 18, no. 5, 2019, pp 18-22.