

Role of foam sclerotherapy in management of varicose veins

Sumegha Rana¹, Ansul Kumar², Mini Sinha³

¹(Senior Resident, Department of CTVS, RIMS, Ranchi, India)

²(Assistant Professor and Head, Department of CTVS, RIMS, Ranchi, India)

³(Senior Resident, Department of CTVS, RIMS, Ranchi, India)

Corresponding Author: Sumegha Rana

Abstract: Varicose veins affect up to 25% of women and 15% of men in the western world³ and incidence is apparently low in India.⁴ Male preponderance was observed with male to female ratio 14:1 in Indian scenario.⁵ Sclerotherapy is a medical procedure used to eliminate varicose veins and spider veins which involves an injection of a solution (generally a salt solution) directly into the vein. The most commonly used is sodium tetradecyl sulphate. The solution irritates the lining of the blood vessel, causing it to swell and stick together, and the blood to clot.¹⁰ In this study various outcomes of injection sclerotherapy were studied and analyzed among patients coming to RIMS, Ranchi which is a tertiary care centre in Jharkhand. A total of 40 cases who underwent foam sclerotherapy were studied out of which, all had obliteration of Varicose Veins. The secondary outcomes were symptomatic improvement, ulcer healing, recurrence, and adverse events. Adverse effects were pain (85%), pruritis (40%), swelling (17.5%) and thrombophlebitis (15%). Complete obliteration was achieved after one injection in all cases. Thrombosis and neurologic events were not seen. Hence, Foam Sclerotherapy appears to be a safe and effective outpatient therapy for the treatment of Varicose Veins and hence can be used routinely.

Date of Submission: 03-05-2019

Date of acceptance: 17-05-2019

I. Introduction

The venous system of the lower limb can be divided anatomically into the superficial venous system, which is located within the superficial tissues and the deep venous system, beneath the deep fascia of the leg, accompanying the arterial tree.¹ Perforators are those which connect the superficial and deep venous system either directly to main veins or indirectly through the muscular and soleal venous plexus.² Chronic venous insufficiency (CVI) is a common and under-recognized problem, affecting greater than 20% of the general population.³ Varicose veins (VVs), the most common manifestation of CVI, affect up to 25% of women and 15% of men in the western world³ and incidence is apparently low in India.⁴ Male preponderance was observed with male to female ratio 14:1 in Indian scenario.⁵ While Varicose Veins have traditionally been regarded as simply a cosmetic problem, more commonly they produce symptoms of heaviness, fatigue, pain, swelling, restlessness, burning, and itching.^{6,7} Varicose Veins are associated with a number of complications including spontaneous varix rupture with hemorrhage, superficial thrombophlebitis, deep vein thrombosis (DVT), and venous ulceration.⁶ Venous ulcerations are particularly troublesome for the patients since many may take more than 9 months to heal, with 66% lasting more than 5 years.⁷

A valuable treatment for primary varicose veins should be minimally invasive and capable of being used on primary and recurrent varicose veins so that it can be repeated as required. There should be few significant complications and the treatment should have good efficacy in abolishing venous reflux in saphenous trunks, perforating veins and varices.⁸ The treatment should be accomplished at little cost and be capable of achieving both functional and cosmetic improvement with little time away from the patient's usual occupation.⁹ Sclerotherapy is a medical procedure used to eliminate varicose veins and spider veins. Sclerotherapy involves an injection of a solution (generally a salt solution) directly into the vein. The most commonly used is sodium tetradecyl sulphate.¹ The solution irritates the lining of the blood vessel, causing it to swell and stick together, and the blood to clot.¹⁰ The procedure commences with the patient standing and the sites of venous cannulation are selected. With the patient supine, the major venous trunks and superficial varicosities to be treated are then all cannulated. Once all injection sites are cannulated the foam can be prepared. The most widely used method is that of Tessari, which utilises two syringes connected using a three-way tap. A 1:3 or 1:4 ratio mixture of sclerosant and air is drawn into one syringe, and is then oscillated vigorously between the two syringes about 10 or 20 times. The foam produced in this way is stable for about 2 minutes so it should be injected as soon as it has been made.¹ Elastic bandages are wrapped around the leg after injection and worn continuously for 3 to 5 days to produce apposition of the inflamed vein walls and prevent thrombus formation. After the bandages are removed,

elastic compression stockings should be worn for a minimum of 2 weeks. Complications from sclerotherapy include allergic reaction, local hyperpigmentation, thrombophlebitis, DVT, and possible skin necrosis.¹¹ This study aims to see various effects of injection sclerotherapy.

II. Material And Methods

This cross sectional descriptive study was carried out on patients of Department of CTVS at Rajendra Institute of Medical Sciences, Ranchi from December 2018 to March 2019. A total 40 patients were included in this study.

Study Design: Cross sectional descriptive study

Study Location: This was a tertiary care teaching hospital based study done in Department of CTVS, at Rajendra Institute of Medical Sciences, Ranchi, Jharkhand.

Study Duration: December 2018 to March 2019.

Sample size: 40 patients.

Data Collection – A pretested semi structured questionnaire was used to collect the relevant data and other observations. Patient satisfaction after completion of the procedure was asked at the time of discharge. A Likert score scale was used to rate his satisfaction regarding the treatment received was taken with a maximum score of five, starting from one.

Data analysis – Data thus collected was entered on excel template using MS Excel and analysis was done using SPSS version 22.0. Measure of central tendency like mean, mode etc and appropriate statistical tests like Chi square, ANOVA, Logistic Regression analysis were done to interpret the results.

Inclusion criteria:

Willing Patients of Varicose veins with perforator incompetence having-

1. Below knee perforator incompetence
2. Competent Saphenofemoral and saphenopopliteal junction

Exclusion criteria:

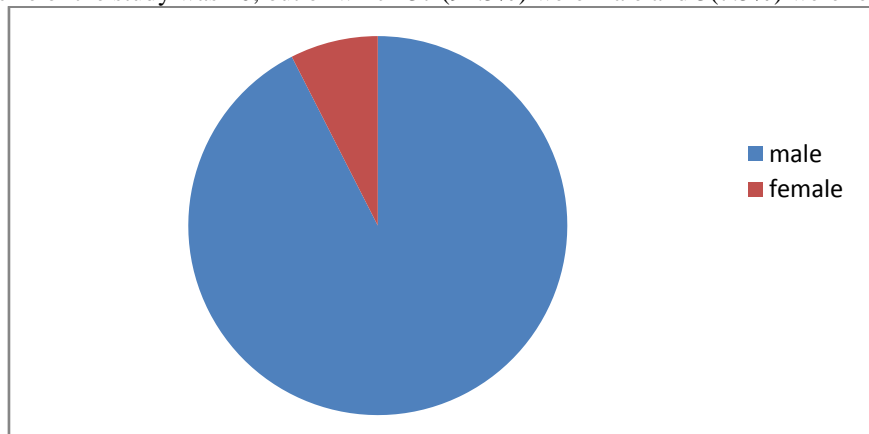
1. Patients with SFJ and SPJ Incompetence.
2. Patients with associated DVT.
3. Above knee Perforator Incompetence.
4. Varicose veins with ulcer.

Procedure methodology

As the patients came with varicose veins to the OPD, they were explained about the study and if they were willing to be part of the study, a well-designed questionnaire was used to collect the details of the patients which included name, registration number, socio-demographic characteristics such as age, gender, nationality, religion and occupation. Complaint with duration was asked and detailed history and general examination was done with routine investigations and Colour Doppler of lower limbs were done to know the cause of varicosity. After the procedure, patients were prescribed called for follow up after 3 weeks and their phone numbers were also taken. Patients were encouraged to report any complications following the procedure while being enquired from the department on phone.

III. Result

The sample size of the study was 40, out of which 37 (92.5%) were male and 3 (7.5%) were female patients.



Thus majority of cases were males with male:female ratio of 37:3.

Primary effect – Obliteration of varicosity occurred in all patients.

Secondary effects -

1. Symptomatic improvement – Symptoms such as heaviness of limb, itching etc were relieved in all cases of varicose veins post injection of foam.
2. Recurrence – Recurrence was seen in 2(5%) of the cases.
3. Adverse events-
 - (a) Pain - 85% of patients had pain post injection sclerotherapy which was the most common side effect seen.
 - (b) Pruritis – It was noticed in 40% of the cases.
 - (c) Swelling - 17.5% of the patients had swelling after injection sclerotherapy
 - (d) Thrombophlebitis – Superficial thrombophlebitis was noted among 15% of patients which eventually subsided after conservative management.
 - (e) Skin ulceration – This complication was seen in one patient(2.5%)whose ulcer however healed subsequently.

IV. Discussion

This hospital based study showed the incidence of the disease about twelve times higher in males than their female counterpart. The male:female ratio was 37:3 which is much higher than the western world. In a study done among north Indian population, 46.7% of females and 27.8% of males were found to be having varicose veins whereas 49.3% of females and 18.9% of males were having venous symptoms.¹² In another study, the prevalence was 10% among men and 29% among women aged 15 and over; it rose with age in each sex.¹³ The incidence among females in another series was much low 7.14% as compared to the western counterpart⁵ similar to our study. Majority of males 127(74.7%) were found in another Indian study,¹⁴ similar to our result.

This study shows the effectiveness of foam sclerotherapy in cases of varicose veins due to perforator incompetence. All patients had complete obliteration of varicosity in single injection. In a study 99% of patients achieved complete (65%) or near complete(34%) obliteration of their varicose veins after the initial injection.¹⁵ In our study, pain was the commonest complication(85%) followed by pruritis(40%), swelling (17.5%), superficial thrombophlebitis (15%) and skin ulceration (2.5%). Complications such as Deep vein thrombosis (DVT) and neurological complications were not seen. These results are comparable to those achieved with surgical or other interventional endovascular procedures.¹⁶⁻²¹

Our study has limitations too. Sample size was small and thus results cannot be generalized on the basis of this study. A larger sample size is required to generalize the findings. Further, this study was not a randomized trial but included a consecutive cohort of patients in a closed practice who underwent foam sclerotherapy at department of cardiothoracic and vascular surgery, Rajendra Institute of Medical Sciences, Ranchi during a defined period of time. Still, as we performed the injection sclerotherapy procedure with great precision and correct technique, we did not see major complications like DVT or neurological deficits, making it a safe procedure.

V. Conclusion

Foam Sclerotherapy appears to be a safe and effective outpatient therapy for the treatment of Varicose Veins and hence can be used routinely.

References

- [1]. Williams Norman S., O'Connell P. Ronan, Mc Caskie Andrew W., Bailey and Loves Short Practice of Surgery, 2018; 27; 969-982.
- [2]. Kishore R., Sankar T. Bavani, et al, A Prospective Study in Comparison of Ambulatory Phlebectomy and Duplex Guided Foam Sclerotherapy in the Management of Varicosities with Isolated Perforator Incompetence, Indian J Surg. 2016 Oct; 78(5): 356–363.
- [3]. Callam MJ., Epidemiology of varicose veins. *Br J Surg* 1994;81: 167–173.
- [4]. Deodhar SD. Varicose veins. *Indian J Med Sci.* 1963;19:431.
- [5]. Shankar KH. Clinical study of varicose veins of lower limbs. *Int Surg J* 2017;4:633-6.
- [6]. Bartholomew JR, King T, Avisesh S, Vidimos AT. Varicose veins: newer, better treatments available. *Cleve Clin J Med* 2005; 72: 312–328.
- [7]. Bergan JJ, Schmid-Schonbein GW, Smith PDC, Nicolaidis AN, Boisseau MR, Eklof B. Mechanism of disease: chronic venous disease. *N Engl J Med* 2006; 355: 488–498.
- [8]. Guex JJ, Allaert FA, Gillet JL, Chleir F (2005) Immediate and midterm complications of sclerotherapy: report of a prospective multicenter registry of 1,173 sclerotherapy sessions. *Dermatol Surg* 31: 123-128.
- [9]. Castro e Silva M, Cabral AL, Barros Jr N, Castro AA, ME Santos (2005) Diagnostic and treatment of venous disease Chronic: standards of guidance clinical the Brazilian Society of Angiology and Vascular Surgery (SBACV). *J Vasc Br* 4: S185-S194.
- [10]. Gamal WM and Mohamed AS, Color Duplex Ultrasound-Guided Foam Sclerotherapy: An Approach in the Management of Patients with Superficial Varicosities of Lower Extremity, *J Vasc Med Surg* 4: 263.
- [11]. Brunnicardi F, Charles, Andersen Dana K., Billiar Timothy R., Dunn David L., Schwartz's Principles of Surgery, 10; 2015;929
- [12]. Agarwal V et al. Prevalence and risk factors of varicose veins, skin trophic changes, and venous symptoms among northern Indian population *International Journal of Research in Medical Sciences.* 2016 May;4(5):1678-1682

- [13]. Abramson J.H. et al, The epidemiology of varicose veins, A survey in western Jerusalem; *Journal of Epidemiology and Community Health*, 1981, 35, 213-217
- [14]. Joseph N et al, A multicenter review of epidemiology and management of varicose veins for national guidance, *Ann Med Surg (Lond)*. 2016 Jun; 8: 21–27.
- [15]. Nael Raha, Rathbun Suman, Effectiveness of foam sclerotherapy for the treatment of varicose veins *Vascular Medicine*, 2009; 15(1) 27–32
- [16]. O’Hare JL, Parkin D, Vandebroek CP, Earnshaw JJ. Mid term results of ultrasound guided foam sclerotherapy for complicated and uncomplicated varicose veins. *Eur J Vasc Endovasc Surg* 2008; 36: 109–113.
- [17]. Myers KA, Jolley D, Clough A, Kirwan J. Outcome of ultrasound-guided sclerotherapy for varicose veins: medium term results assessed by ultrasound surveillance. *Eur J Vasc Endovasc Surg* 2007; 33: 116–121.
- [18]. Jia X, Mowatt G, Burr JM, Cassar K, Cook J, Fraser C. Systematic review of foam sclerotherapy for varicose veins. *Br J Surg* 2007; 94: 925–936.
- [19]. Darke SG, Baker SJA. Ultrasound-guided foam sclerotherapy for the treatment of varicose veins. *Br J Surg* 2006; 93: 969–974.
- [20]. Barrett JM, Allen B, Ockelford A, Goldman MP. Microfoam ultrasound-guided sclerotherapy of varicose veins in 100 legs. *Dermatol Surg* 2004; 30: 6–12.
- [21]. Frullini A, Cavezzi A. Sclerosing foam in the treatment of varicose veins and telangiectases: history and analysis of safety and complications. *Dermatol Surg* 2002; 28: 11–15.

Sumegha Rana. “Role of foam sclerotherapy in management of varicose veins”. *IOSR Journal of Dental and Medical Sciences (IOSR-JDMS)*, vol. 18, no. 5, 2019, pp 09-12.