

MTA Apexification: Case Series

Dr. Shruti Shetty¹, Dr. Jyothi B², Dr. Sandeep Sidral, Dr. Priti Somvanshi

¹(Department Of Pediatric And Preventive Dentistry, SMBT Dental College, India)

²(Reader, Department Of Pediatric And Preventive Dentistry, SMBT Dental College, India)

*Corresponding author: Shruti Shetty1

Abstract: The treatment of choice for necrotic teeth with immature root is apexification, which is induction of apical closure to produce more favorable conditions for conventional root canal filling. The most commonly advocated medicament is calcium hydroxide although recently considerable interest has been expressed in the use of mineral trioxide aggregate (MTA). MTA offers the option of a two -visit apexification procedure so that the fragile tooth can be restored immediately. This article describes the cases treated using MTA.

Date of Submission: 02-05-2019

Date of acceptance: 16-05-2019

I. Introduction

Management of immature root with a necrotic pulp and apical periodontitis is a challenging task. The infected root canal space cannot be completely disinfected with the standard treatment protocol. Obturation of the root canal in open apex is difficult because of lack of apical barrier for containing the root filling material. Also, long term drawbacks of obturation of root canal in immature teeth are no increase in radicular dentin thickness and as there is no achievement of crown root ratio so there are increased chances of root fracture. Treatment of choice in such cases is the apexification procedure, which establishes an apical barrier.¹ Calcium hydroxide has been widely used for the induction of apical barrier. However, it requires 5–20 months to form the hard tissue barrier.² Also, the use of calcium hydroxide decreases the resistance of the dentin to fracture.³ In recent times, mineral trioxide aggregate (MTA) has gained popularity for the apexification procedure. MTA was first described in dental scientific literature in 1993⁴ and was given approval for endodontic use by the US Food and Drug Administration in 1998. Upto 2002, only grey MTA was available and then white MTA was introduced. Both formulae contain 75% Portland cement, 20% bismuth oxide and 5% gypsum by weight. The purpose of this procedure is to limit bacterial infection and creation of mineralized apical tissues in immature tooth. The inadequacy of calcium hydroxide apexification due to its long time span and re-infection because of temporary seal led to the use of MTA.³ MTA produces apical hard tissue formation with significantly greater consistency than calcium hydroxide. In the following case series we are discussing apexification procedure done using MTA.

II. Case report

Case 1:

A 10 year old female patient reported with a chief complain of fractured tooth in upper front region of jaw. History revealed patient had suffered trauma due to fall 1 month back. Medical history was non contributory. Clinical examination revealed Ellis class II fracture with 11 and 21. The tooth did not demonstrate any abnormal mobility or sensitivity to percussion. Both cold and electric sensibility tests failed to elicit any response with 21 whereas 11 responded normally. Periapical radiograph showed break in lamina dura and wide open apex in relation to tooth 21. The final diagnosis was pulpal necrosis with chronic apical periodontitis in relation to tooth 21. After discussing different treatment options with the patient's parents, we opted to go for MTA apexification. Written consent was obtained from the guardian of the patient. The tooth 21 was accessed and working length was established radiographically. Root canal was chemo-mechanically debrided with circumferential filing in conjunction with copious amount of 0.5% sodium hypochlorite irrigation. A volume of 3 ml of 17% ethylene diamine tetraacetic acid (EDTA) solution was used for smear layer removal followed by a final rinse with NaOCl. Calcium hydroxide medicament paste was placed in the root canal, and access cavity was restored with Temp Paste. One week later, tooth was again accessed, and copious amount of normal saline was used to remove any remnants of the calcium hydroxide medicament. Canal was thoroughly dried with absorbent paper points. White MTA Angelus (Angelus, Londrina, PR, Brazil) was mixed according to manufacturer's instructions and using hand pluggers, gently condensed to form 4 mm of apical plug. After placing a moist cotton pellet, the access cavity was restored with Temp Paste. Next day, root canal was

obtured using thermoplastic obturation technique and the tooth 21 and 11 were restored with composite restoration.(fig 1)

Case 2:

A 8 year old male patient reported with a chief complain of fractured tooth in upper front region of jaw. History revealed patient had suffered trauma due to fall 15 days back. Medical history was non contributory. Clinical examination revealed Ellis class II fracture with 21. The tooth did not demonstrate any abnormal mobility or sensitivity to percussion. Both cold and electric sensibility tests failed to elicit any response with 21. Periapical radiograph showed diffused radiolucency and blunderbuss canal with tooth 21. The final diagnosis was ellis class II fracture and chronic apical periodontitis with tooth 21. After discussing different treatment options with the patient's parents, we opted to go for MTA apexification. Written consent was obtained from the guardian of the patient. The tooth 21 was accessed and working length was established radiographically. Chemo-mechanical preparation was done similar to previous case. Calcium hydroxide medicament paste was placed in the root canal, and access cavity was restored with Temp Paste. One week later, tooth was again accessed, and copious amount of normal saline was used to remove any remnants of the calcium hydroxide medicament. Canal was thoroughly dried with absorbent paper points. White MTA Angelus (Angelus, Londrina, PR, Brazil) was mixed according to manufacturer's instructions and using hand pluggers, gently condensed to form 4 mm of apical plug. After placing a moist cotton pellet, the access cavity was restored with Temp Paste. Next day, root canal was obtured using thermoplastic obturation technique and the tooth 21 was restored with composite restoration.(fig 2)

Case 3:

A 8 year old male patient reported with a chief complain of decayed tooth in lower left back region of jaw since 6 months. History revealed patient had spontaneous pain in lower left back region of jaw 2 months back which subsided on medication. Medical history was non contributory. Clinical examination revealed hypoplastic tooth 36. The tooth did not demonstrate any abnormal mobility or sensitivity to percussion. Both cold and electric sensibility tests failed to elicit any response with tooth 36. Periapical radiograph showed radiolucency on the mesial aspect of the crown involving, enamel, more than half of dentin,approaching pulp. Interradicular widening of lamina dura is seen. The final diagnosis was pulp necrosis and periapical infection with tooth 36. After discussing different treatment options with the patient's parents, the treatment planned was MTA apexification. Written consent was obtained from the guardian of the patient. The tooth 36 was accessed and working length was established radiographically. Chemo-mechanical preparation was done similar to previous two cases. Calcium hydroxide medicament paste was placed in the root canal, and access cavity was restored with Temp Paste. One week later, tooth was again accessed, and copious amount of normal saline was used to remove any remnants of the calcium hydroxide medicament. Canal was thoroughly dried with absorbent paper points. White MTA Angelus (Angelus, Londrina, PR, Brazil) was mixed according to manufacturer's instructions and using hand pluggers, gently condensed to form 4 mm of apical plug. After placing a moist cotton pellet, the access cavity was restored with Temp Paste. Next day, root canal was obtured using thermoplastic obturation technique and the tooth 36 was restored with miracle mix restoration followed by stainless steel crown.(fig 3)

III. Discussion

In an immature tooth with open apex, the treatment options range from apexification, apexogenesis to revascularisation,depending upon the vitality of the tooth and the regenerative potential. Apexification is defined as a method to induce a calcified barrier in a root with an open apex in teeth with necrotic pulp. This barrier is mandatory to allow the compaction of the root filling material. Therefore due to nonvital pulp and availability of adequet crown root ratio, apexification was planned in all the cases. Calcium hydroxide has been considered as an efficient material for this purpose.⁵ This chemical has several disadvantages such as difficulty of the patient's recall management and delay in the treatment.⁶ Furthermore, after dressing with calcium hydroxide for extended periods there is a risk of tooth fracture.³ MTA is a promising alternative to calcium hydroxide. The advantages of this material are (i) reduction in treatment time, (ii) immediate restoration of the tooth, (iii) no adverse effect on the mechanical properties of root dentin. In a prospective study, MTA apexification showed a high prevalence of healing and apical closure.⁷ Regeneration of periodontal ligament occurred around the apices of teeth and it was also associated with minimal inflammatory response. Harbert documented the long term success of using a tri calcium phosphate plug as an apical barrier for one step apexification. In other studies, immature teeth with open apices were obtured using an apical barrier with dentin and Ca(OH)₂ plugs or dentin chips and hydroxyapatite.⁸ Torabinejad reported the ingredients in MTA as tri calcium silicate, tricalcium aluminate, tricalcium oxide and silicate oxide with some other mineral oxides that were responsible for the chemical and physical properties of aggregate.⁹ The powder consists of fine hydrophilic particles that set in the presence of

moisture. The hydration of the powder results in a colloidal gel with a pH of 12.5 that will set in approximately 3 hours. MTA has a compressive strength equal to intermediate restorative material and Super - EBA but less than that of amalgam. It is commercially available as ProRoot MTA, and has been advocated for use in the immediate obturation of open root apex. MTA has the ability to induce cementum like hard tissue barrier when used adjacent to the periradicular tissues. MTA is a promising material as a result of its superior sealing property, its ability to set in the presence of blood and its biocompatibility to tissues. Moisture contamination at the apex of tooth before barrier formation is often a problem with other materials used in apexification. As a result of its hydrophilic property, the presence of moisture does not affect its sealing ability. Therefore it was used for apexification in all the cases. Despite its good physical and biologic properties, extended setting time has been a main disadvantage. Calcium chloride was used with intention to stimulate hardening process of MTA. Studies have shown that not only the sealing ability but its physicochemical property was improved by addition of CaCl_2 .

For chemomechanical preparation, Chelating agents such as ethylenediaminetetraacetic acid (EDTA), citric acid and tetracycline are used for removal of the inorganic portion of the smear layer.¹⁰ NaOCl is an adjunct solution for removal of the remaining organic components. Irrigation with 17% EDTA for one minute followed by a final rinse with NaOCl is the most commonly recommended method to remove the smear layer.¹¹ Longer exposures can cause excessive removal of both peritubular and intratubular dentin.¹² EDTA has little or no antibacterial effect.¹³ Therefore we used the combination of EDTA and sodium hypochlorite .in the above mentioned cases

Intracanal medicaments have been used to disinfect root canals between appointments and reduce interappointment pain. Calcium hydroxide is the most commonly used dressing for treatment of the vital pulp. It also plays a major role as an inter-visit dressing in the disinfection of the root canal system. Ca(OH)_2 is a substance that inhibits microbial growth in canals.¹⁴ The antibacterial effect of Ca(OH)_2 is due to its alkaline pH. It also dissolves necrotic tissue remnants and bacteria and their byproducts.¹⁵ It can be placed as a dry powder, a powder mixed with a liquid such as water, saline, local anesthetic or glycerin, or a proprietary paste supplied in a syringe. Calcium hydroxide was therefore used in our cases as intracanal medication. Also because of the wide canals, thermoplastic obturation technique was used as it does not cause excessive compaction forces on the thin dentinal walls of an immature tooth and to reduce the formation of voids, to obtain a proper seal.

IV. Conclusion

MTA has numerous applications in endodontic therapy which range from apexification to pulpotomy. The main advantages of this material as an apical barrier include development of proper apical seal and excellent biocompatibility. Single visit apexification with a novel biocompatible material like MTA is a new boon in effective management of teeth with open apex .This innovative procedure is predictable and less time consuming one.

References

- [1]. Purra AR, Ahangar FA, Chadgal S, Farooq R. Mineral trioxide aggregate apexification: A novel approach. *J Conserv Dent* 2016;19:377-80.
- [2]. Sheehy EC, Roberts GJ. Use of calcium hydroxide for apical barrier formation and healing in non-vital immature permanent teeth: A review. *Br Dent J* 1997;183:241-6.
- [3]. Andreasen JO, Farik B, Munksgaard EC. Long-term calcium hydroxide as a root canal dressing may increase risk of root fracture. *Dent Traumatol* 2002;18:134-7
- [4]. Lee SJ, Monset M, Torabinejad M. Sealing ability of a mineral trioxide aggregate for repair of lateral root perforations. *J. Endod* 1993; 19 : 541-4.
- [5]. Chosack A, Sela J, Cleaton-Jones P. A histological and quantitative histomorphometric study of apexification of nonvital permanent incisors of vervet monkeys after repeated root filling with a calcium hydroxide paste. *Endod Dent Traumatol* 1997;13:211-7.
- [6]. Dominguez Reyes A, Muñoz Muñoz L, Aznar Martín T. Study of calcium hydroxide apexification in 26 young permanent incisors. *Dent Traumatol* 2005;21:141-5.
- [7]. Simon S, Rilliard F, Berdal A, Machtout P. The use of mineral trioxide aggregate in one-visit apexification treatment: A prospective study. *Int Endod J* 2007;40:186-97
- [8]. Brandell DW, Torabinejad M, Bakland L K. Demineralised dentin, hydroxyapatite and dentin chips as apical plugs. *Endod Dent Traumatol* 1986;2:210-4
- [9]. Torabinejad M, Chivian N. Clinical applications of mineral trioxide aggregate. *J Endod* 1999;25:197-205.
- [10]. Torabinejad M, Handysides R, Khademi A, Bakland LK. Clinical implications of the smear layer in endodontics: A review. *Oral Surg Oral Med Oral Pathol Oral Radiol Endod* 2002;94:658-66
- [11]. Johnson WT, Noblett WC. *Cleaning and Shaping in: Endodontics: Principles and Practice*. 4th ed. Saunders, Philadelphia, PA, 2009
- [12]. Calt S, Serper A. Smear layer removal by EGTA. *J Endod* 2000;26:459-61
- [13]. Torabinejad M, Shabahang S, Kettering J, Aprecio R. Effect of MTAD on E Faecalis: an in vitro investigation. *J Endod* 2003;29:400-3.
- [14]. Law A, Messer H. An evidence-based analysis of the antibacterial effectiveness of intracanal medicaments. *J Endod* 2004;30:689-94

- [15]. Yang SF, Rivera EM, Baumgardner KR, Walton RE, Stanford C. Anaerobic tissue-dissolving abilities of calcium hydroxide and sodium hypochlorite. J Endod 1995;21:613-6

Fig 1:

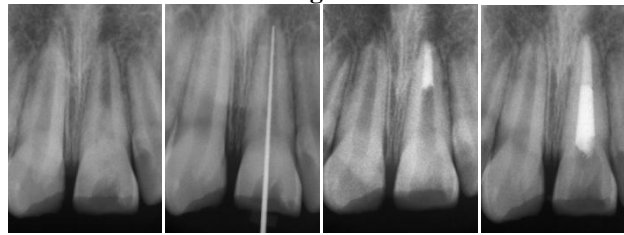


Fig 2:

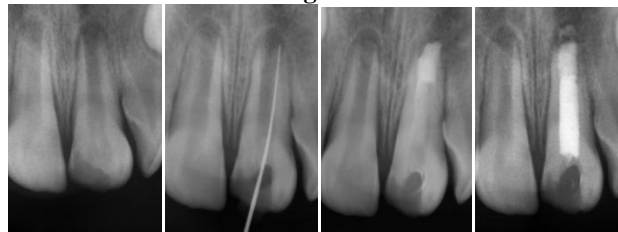
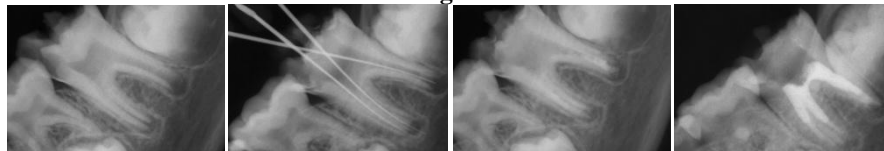


Fig 3:



Shruti Shetty1 “MTA Apexification: Case Series.” IOSR Journal of Dental and Medical Sciences (IOSR-JDMS), vol. 18, no. 5, 2019, pp 84-87.