

Splenectomy in the management of non-cirrhotic portal hypertension: A Case Report

Arshad Ahmad Ansari¹, Vidyand Tripathi², Abhik Sil³, Raghvendra Sharma⁴,
James Oscar Marak⁵, Resen Rajan S Methikkalam⁶, G S Moirangthem⁷.

^{1,2,3,4,5,6,7}(Department of general surgery, Regional Institute of Medical Sciences/Manipur University, India)

Corresponding Author: Arshad Ahmad Ansari

Abstract: Non-cirrhotic portal hypertension (NCPH) is a condition first described by Guido BANTI in 1898 as a condition associating portal hypertension with splenomegaly and anaemia in healthy liver. The aim of our work is to evaluate the place of splenectomy in management of non-cirrhotic portal hypertension. The diagnosis of NCPH was based on portal hypertension, presence of esophageal varices with splenomegaly in a healthy liver. The evaluation after splenectomy was based on normalization of clinical and radiological signs with biochemical markers. Here we are presenting a case of a 38 year old female diagnosed to have NCPH which was managed by splenectomy.

Date of Submission: 26-04-2019

Date of acceptance: 11-05-2019

I. Introduction

Non-cirrhotic or idiopathic portal hypertension or hepatoportal sclerosis, also called BANTI syndrome is a rare condition characterized by the presence of an increase in portal pressure secondary to sclerosis of the wall of small intrahepatic branches of portal vein, with non-cirrhotic liver¹. The pathophysiological mechanism causing idiopathic non-cirrhotic portal hypertension (INCPH) remains largely unknown. Patients with INCPH usually present with sign and symptoms of portal hypertension such as splenomegaly, thrombocytopenia and variceal bleeding^{2,3,4}. Variceal bleeding is the most common clinical feature. Unlike cirrhotic patients, prognosis of variceal bleeding in INCPH is usually good due to preserved liver function. In those patients without variceal bleeding at diagnosis over 75% had varices at the initial endoscopy^{2,5}. The aim of our work is to evaluate the place of splenectomy in the management of NCPH. Here we present a case of a 38 year old female diagnosed to have NCPH which was managed by splenectomy.

II. Case Report

A 38 year old female presented with history of 2 episodes of hematemesis with vague pain in left upper quadrant of abdomen on and off since last 2 months. There was no history of chronic alcoholism or viral hepatitis or diabetes mellitus or chronic use of NSAIDs. There was a past history of similar type of illness 2 years back for which the patient was admitted in health centre and was managed conservatively.

On examination, the patient was malnourished and pale and there were multiple areas of purpura over the skin of abdomen and limbs. On examination of abdomen, spleen was palpable up to umbilicus, around 15cm below left costal margin in the mid-clavicular line. On digital rectal examination, finger stain black tarry stool was found. On haematological examination, the patient was found to have pancytopenia (anaemia, leukopenia, thrombocytopenia) and liver function test was showing normal levels of liver enzymes. Ultrasonography of abdomen was suggestive of portal hypertension (splenomegaly, minimal ascites and collateral circulations), but liver echo-texture was normal and thrombosis of hepatic veins or of the portal veins were not found. On upper GI-endoscopy, grade-ii esophageal varices were found.

The patient was initially managed conservatively with beta-blocker, transfusion of packed red blood cells and platelet concentrate; after which, patient underwent splenectomy along with band ligation of esophageal varices. Post-operative period was uneventful and maintenance treatment with beta-blocker was continued for 6 weeks. At 2nd week post-operatively, all the hematological parameters (pancytopenia) came to normal.

The patient was followed-up after 6 week post-operatively and there was no fresh episode of hematemesis or melena and repeat upper GI- endoscopy was normal.

Figure 1: USG Scan Image showing splenomegaly

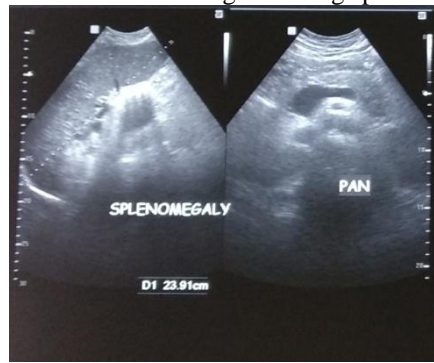

Figure 2: Intraoperative picture showing massive splenomegaly

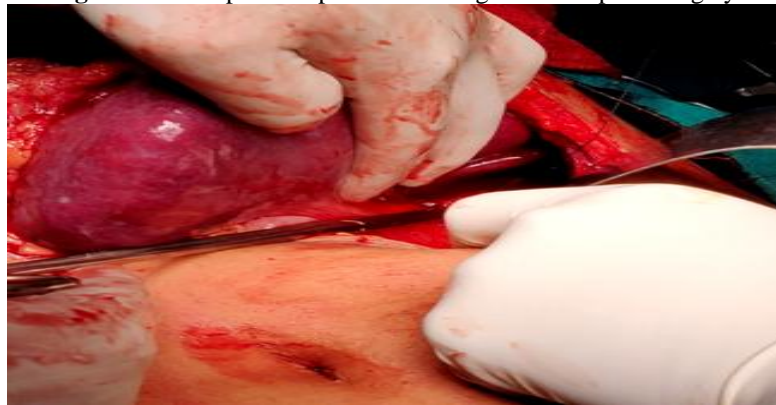


Figure 3: Intraoperative picture showing massive splenomegaly

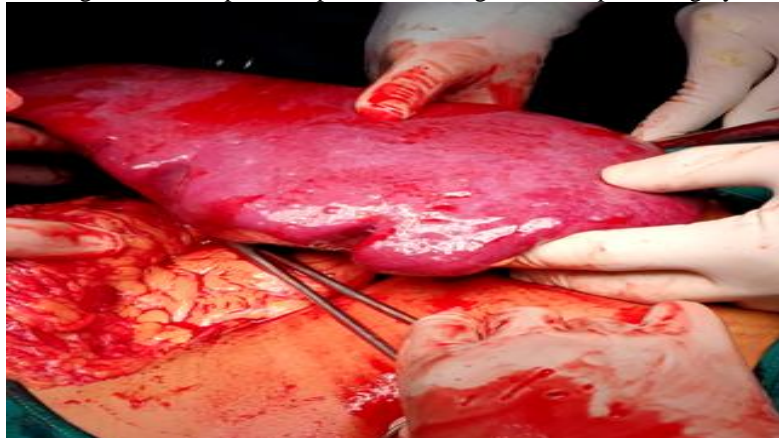


Table 1: pre-operative liver enzymes

Liver enzymes	Values (IU)
Serum AST (SGOT)	39
Serum ALT (SGPT)	26
Serum ALP	244
Serum GGT	38

Table 2: comparison between pre-operative and post-operative hematological parameters

Hematological parameters	Pre-operative	Post-operative
Hemoglobin (gm%)	4.5	11.4
RBC count (x10 ⁹ /micro liter)	1.5	4.63
Total Count (x10 ³ /micro liter)	0.9	9.78
Platelet count (x10 ³ /micro liter)	105	467

III. Discussion

Non-cirrhotic portal hypertension is a rare entity that is documented from all over the world, but it is far more common in developing countries with less favorable socio-economic level, such as India, whose the frequency of the disease is estimated at about 30% of portal hypertension⁶. It mainly affects young adults between the 3rd and 4th decade⁷. Non-cirrhotic portal hypertension is characterized by the presence of portal hypertension on a healthy liver with gastro-oesophageal varices and splenomegaly, often with hypersplenism⁸. Doppler ultrasound is useful for identifying thrombosis of the intrahepatic branches of the portal vein⁹. Although most series in the literature describe the interest of endoscopic treatment of gastro-oesophageal varices and portal hypertension¹⁰⁻¹¹, few series develop the management of hypersplenism and splenomegaly in Non-cirrhotic portal hypertension¹².

Band ligation of esophageal varices along with beta-blocker is often indicated to treat and prevent hemorrhage of esophageal varices as in case of cirrhotic-related portal hypertension¹³⁻¹⁴. Splenectomy alone can be justified in the management of this syndrome. It helps treat splenomegaly and correct hypersplenism and therefore reduce portal blood flow. But it can lead to thrombosis of the splenic vein which again can be prevented by a possible shunt¹⁵. In a study by Rajesh et al, among 55 patients operated for non-cirrhotic portal hypertension, 2 patients underwent splenectomy alone and in 7 patients splenectomy was done along with endoscopic treatment of esophageal varices. In 2 patients out of 9 patients, the course was marked by a recurrence of variceal hemorrhage¹⁶. In our study, our patient underwent splenectomy without any spleno-renal shunt with band ligation of esophageal varices with maintenance treatment with beta-blocker and the result was satisfactory.

IV. Conclusion

Splenectomy along with the ligation of oesophageal varices without any spleno-renal diversion may be sufficient to manage non-cirrhotic portal hypertension and especially its consequences like pancytopenia.

References

- [1]. Banti G. Splenomegalie mit leberzihhose beitrage zur Pathologischen. Anat Allgemeine Pathol. 1889;24:21–33
- [2]. Schouten JN, Garcia- Pagan JC, Valla DC, Janssen HL. Idiopathic noncirrhotic portal hypertension. Hepatology. 2011 Sep 2;54(3):1071-81.
- [3]. Siramolpiwat S, Seijo S, Miquel R, Berzigotti A, Garcia- Criado A, Darnell A, Turon F, Hernandez- Gea V, Bosch J, Garcia- Pagán JC. Idiopathic portal hypertension: Natural history and long- term outcome. Hepatology. 2014 Jun;59(6):2276-85.
- [4]. Austin A, Campbell E, Lane P, Elias E. Nodular regenerative hyperplasia of the liver and coeliac disease: potential role of IgA anticardiolipin antibody. Gut. 2004 Jul 1;53(7):1032-4.
- [5]. Khanna R, Sarin SK. Non-cirrhotic portal hypertension–Diagnosis and management. Journal of hepatology. 2014 Feb 1;60(2):421-41.
- [6]. Krasinskas AM, Eghtesad B, Kamath PS, Demetris AJ, Abraham SC. Liver transplantation for severe intrahepatic noncirrhotic portal hypertension. Liver transplantation. 2005 Jun 1;11(6):627-34.
- [7]. Cazals-Hatem D, Hillaire S, Rudler M, Plessier A, Paradis V, Condat B, Francoz C, Denninger MH, Durand F, Bedossa P, Valla DC. Obliterative portal venopathy: portal hypertension is not always present at diagnosis. Journal of hepatology. 2011 Mar 1;54(3):455-61.
- [8]. Siramolpiwat S, Seijo S, Miquel R, Berzigotti A, Garcia- Criado A, Darnell A, Turon F, Hernandez- Gea V, Bosch J, Garcia- Pagán JC. Idiopathic portal hypertension: Natural history and long- term outcome. Hepatology. 2014 Jun;59(6):2276-85.
- [9]. Saito K, Nakanuma Y, Takegoshi K, Ohta G, Obata Y, Okuda K, Kameda H. Non-specific immunological abnormalities and association of autoimmune diseases in idiopathic portal hypertension. A study by questionnaire. Hepato-gastroenterology. 1993 Apr;40(2):163-6.
- [10]. Sarin S, Agarwal S. Extrahepatic portal vein obstruction. Semin Liver Dis. 2002 Feb;22(1):43–58.
- [11]. Sarin SK, Kumar A. Gastric varices: profile, classification, and management. American Journal of Gastroenterology. 1989 Oct 1;84(10).
- [12]. Bashour FN, Teran JC, Mullen KD. Prevalence of peripheral blood cytopenias (hypersplenism) in patients with nonalcoholic chronic liver disease. The American journal of gastroenterology. 2000 Oct 1;95(10):2936-9.
- [13]. Pereboom IT, de Boer MT, Haagsma EB, Hendriks HG, Lisman T, Porte RJ. Platelet transfusion during liver transplantation is associated with increased postoperative mortality due to acute lung injury. Anesthesia & Analgesia. 2009 Apr 1;108(4):1083-91.
- [14]. Sankey EA, Crow J, Mallett SV, Alcock RJ, More L, Burroughs AK, Rolles K. Pulmonary platelet aggregates: possible cause of sudden perioperative death in adults undergoing liver transplantation. Journal of clinical pathology. 1993 Mar 1;46(3):222-7.
- [15]. Jørgensen B, Fischer E, Ingeberg S, Hollænder N, Ring-Larsen H, Henriksen JH. Decreased blood platelet volume and count in patients with liver disease. Scandinavian journal of gastroenterology. 1984 Jun 1;19(4):492-6.
- [16]. Mendenhall C, Sherman J, Chedid A. intermittent idiopathic portal hypertension: a case report. Gastroenterology. 1974 Jul;67(1):142-8.

Arshad Ahmad Ansari" Splenectomy in the management of non-cirrhotic portal hypertension: A Case Report" IOSR Journal of Dental and Medical Sciences (IOSR-JDMS), vol. 18, no. 5, 2019, pp 01-03.