

## Periapical Surgery of Left Lateral Incisor Using MTA Angelus as a Root End Filling Material-A Case Report

Dr.Panna Mangat<sup>1</sup>, Dr.Anil.K.Tomer<sup>2</sup>, Dr.Afnan Ajaz Raina<sup>3</sup>, Dr.Faizan Bin Ayub<sup>4</sup>,Dr.Megna Bhatt<sup>5</sup>,Dr.Ayush Tyagi<sup>6</sup>,Dr.Shivendra Ahlawat<sup>7</sup>

(Professor Department of Conservative Dentistry & Endodontics D.J. College of Dental Sciences and Research, Modinagar, Ghaziabad, Uttar Pradesh, India )<sup>1</sup>

Professor and Head, Department of Conservative Dentistry & Endodontics D.J. College of Dental Sciences and Research, Modinagar, Ghaziabad, Uttar Pradesh, India )<sup>2</sup>

(Post Graduate Student, Department of Conservative Dentistry & Endodontics D.J. College of Dental Sciences and Research, Modinagar, Ghaziabad, Uttar Pradesh, India)<sup>3,5,6,7</sup>

(Post Graduate Student, Department of Orthodontics & Dentofacial Orthopedics,D.J. College of Dental Sciences and Research, Modinagar, Ghaziabad, Uttar Pradesh, India)<sup>4</sup>

Corresponding Author: Dr.Panna Mangat

**Abstract;** The purpose of a root-end filling is to establish a seal between the root canal space and the periradicular tissues. As root-end filling materials come into contact with periradicular tissues, knowledge of the tissue response is crucial. Almost every available dental restorative material has been suggested as the root-end material of choice at a certain point in the past. This case report represents an endodontic surgery of a maxillary left lateral incisor in which MTA Angelus was used as a root end filling material which resulted in complete healing of the lesion at 1 year with absence of clinical symptoms and radiographic evidence and regeneration of the periapical tissues.

**Keywords;** Apicoectomy,Retrograde filling material,MTA Angelus,Cone beam computed tomography

Date of Submission: 26-04-2019

Date of acceptance: 11-05-2019

### I. Introduction

Surgical root canal therapy is often indicated when nonsurgical retreatment has failed or cannot be performed. Surgical root canal therapy usually involves resecting a portion of the root apex and preparing and filling a cavity in the root-end. The term apicoectomy refers to a stage of the operation only. The principal objective is to seal the canal system at the apical foramen from the periradicular tissues. To do this, it is necessary to resect the apical part of the root to gain access to the root canal, hence the term. The aim of resection is to present the surface of the root so that the apical limit of the canal can be visually examined and to provide access for retrograde cavity preparation. Approximately 3 mm of root is removed which includes almost all lateral canals. Root end resection must be an adjunct measure to orthograde root treatment for two reasons. Firstly, there is very little chance of being able to seal all the lateral communications between the canal and the periodontal ligament with a retrograde root-filling technique.

Secondly, the area of root-filling material exposed will be greater and the long-term success affected, because all root-filling materials are, to some extent, irritant to the tissues.<sup>1,2</sup>

Retrograde filling materials such as amalgam, gutta percha, zinc-oxide eugenol cements (IRM, Super-EBA), Glass ionomer cements, composite resins, compomers, diaket, Ceramicrete, Bioaggregate, etc. are commonly used in endodontic surgical procedures.

All of these materials have been shown to be compatible with tissue cicatrisation and the reconstitution of periradicular alveolar bone, but none of them is able to induce cementum formation and full periodontal ligament repair. Mineral trioxide aggregate (MTA), a calcium silicate-based material developed by the modification of Portland cement, has been introduced to address this problem and has shown good biocompatibility and sealing properties. This material permits a full regenerative healing and can be considered as the material of choice in endodontic surgery. In addition, the sealing properties of MTA are not affected by moisture during treatment.<sup>3</sup>

The steps for carrying out this procedure are:

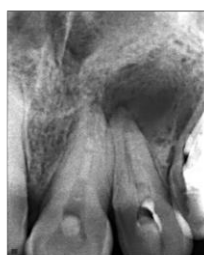1. Pre-operative care.
2. Anaesthesia and haemostasis.
3. Soft-tissue management.
4. Hard-tissue management.

5. Curettage of area.
6. Resection of root.
7. Retrograde cavity preparation.
8. Retrograde filling.
9. Replacement of flap and suturing.
10. Post-operative care.<sup>4</sup>

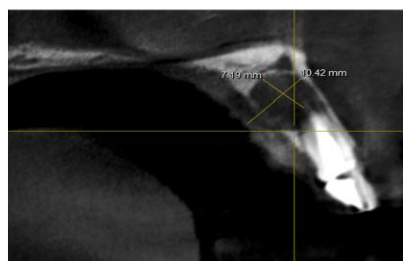
## II. Case Report

A 28 year old female patient reported to the Department Of Conservative Dentistry & Endodontics with a chief complaint of pain in the upper left front tooth region. On clinical examination, the teeth responded positive to percussion and radiological examination revealed periapical radiolucency. A preoperative cone beam computed tomographic examination of the patient was done to identify the accurate location and measurement of the lesion. (Fig.1,2)

### Periapical surgery of maxillary left lateral incisor



Preoperative radiograph



Preoperative Cbct

#### Surgical Procedure

Prophylactic administration of oral antimicrobials were prescribed to prevent systematic disease and also to prevent postoperative infection. The patient was anesthetized with 2% Lignocaine with 1:80,000 adrenaline. Surgical procedures like flap design and elevation was done. Relieving incisions were made on sound bone i.e, a sulcular and mucogingival incisions were made with Surgical Blade (SM-64 and SM-67), Flap elevation was done using Elevator (DISC SHAPED ELEVATOR OR DISSECTOR). An assessment of the length of the root and its axis was done radiographically to remove bone from the desired site. Osteotomy was performed by using no-4 and 6 round carbide bur with Impact Micro-motor handpiece and curette (DISK SHAPED CURETTE-1.5mm) was used for periradicular curettage. The apicoectomy was simulated by cutting the apical 2 mm of the roots with a diamond fissure bur size 1.0 mm using sterile saline for cooling. The root-end cavities were prepared to a depth of 3 mm with a tungsten carbide fissure bur with a diameter of 0.8 mm, parallel to the canal, leaving a 3 mm deep root-end cavity free of gutta percha. Sterile saline in a syringe was used for cooling.

Prepared root end cavity was dried with irrigator/drier and filled with material such as Mineral Trioxide Aggregate Angelus, followed by placement of a bone graft to induce bone regeneration. Adaptation of filling material was confirmed by using radiograph. A careful debridement of the bony crypt was made to ensure that haemostatic agents, root-end filling material and debris are removed.

Radiographic verification of the quality of the root end filling is appropriate before wound closure. The soft tissue flap was then re-apposed with sutures as optimum healing is being achieved with primary closure. After suturing, the tissues were compressed with damp gauze for 3–5 minutes. The patient was then asked to follow post operative instructions such as to apply cold compresses with an ice pack for the first 4–6 hours after surgery, followed by mouth rinses to maintain a good oral hygiene. The patient was also prescribed antimicrobials for 5 days. Sutures were then removed after 4-7 days post-operatively (providing the wound was stable), i.e when reattachment of the periodontal fibres at the gingival margin had taken place. In addition, the healing progress was checked and recorded properly. After whole procedure, the patients were then recalled at 6 months-9 months-1 year to assess the clinical and radiographic signs of healing by use of Cone Beam Computed Tomography (FIG.3,4,5)

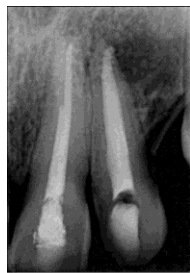

FIG.3 -6 Months follow up

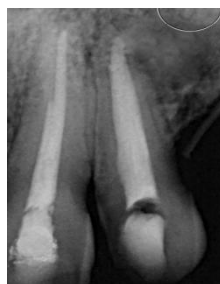

Fig.4-9 months follow up

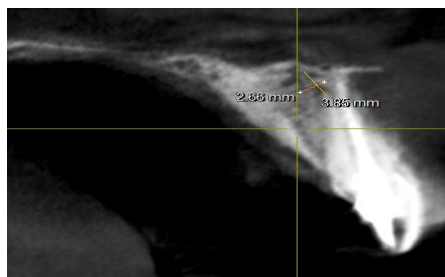


Fig.5-12months follow up

### III. Discussion

**MTA-Angelus Reparative Cement** is an endodontic reparative cement, containing mineral trioxide aggregate (MTA). It is indicated for the treatment of lateral and furcation perforations, apexification, internal resorption, pulpotomy, pulp capping, and apexogenesis. Calcium ions are released that promote the formation of a dentin bridge when used for pulp capping and promote biological healing and the formation of root cement in cases of root perforations. **MTA-Angelus** is designed to be used under moist conditions, as it absorbs water and forms a gel, and then solidifies. **MTA-Angelus** has an initial setting time of 10 minutes and a final setting time of 15 minutes. The powder is packaged in a re-sealable vial with liquid (distilled water) in a dropper bottle. Unused powder may be kept for future use. Each kit contains five, 1 g vials of powder with a measuring scoop and a 3 mL bottle of liquid. **MTA-Angelus** is available with white powder or a new light gray color.<sup>5,6</sup>

MTA-Angelus presents a similar composition to Pro-Root, according to the manufacturer. Duarte et al. have demonstrated that both materials release calcium and provide alkaline environment. Besides, when used in direct pulp capping or pulpotomy both materials were biocompatible and effective to produce complete pulp healing. Menezes et al. also showed that the tissue reactions were identical for Pro-Root and MTA-Angelus. Various studies reported that MTA presented excellent apical sealing, and demonstrated its superiority in comparison to other commonly used materials. MTA-Angelus marginal adaptation was better than the other tested materials. However, MTA contains bismuth oxide, which is a factor that must be taken into consideration when using this cement as a root-end filling material. Bismuth oxide is added to MTA for radiopacity, but in the long term it can cause changes in the cement, resulting in increased porosity and decreased mechanical resistance.<sup>7</sup>

In addition a new imaging technique i.e, Cone-beam computed tomography (CBCT) was used to assess the measurement of lesions at regular intervals. It is a new medical imaging technique that generates 3-D images at a lower cost and absorbed dose compared with conventional computed tomography (CT). This imaging technique is based on a cone-shaped X-ray beam centred on a 2-D detector that performs one rotation around the object, producing a series of 2-D images. These images are reconstructed in 3-D using a modification of the original cone beam algorithm developer. CBCT imaging is a useful tool for diagnosing periapical lesions. CBCT

images can be used to differentiate between apical granulomas and apical cysts by measuring the lesion's density. CBCT is a reliable pre-surgical tool for assessing a tooth's proximity to adjacent vital structures, allowing for accurate measurement of the size and extent of a lesion and the anatomy of the area (Alshehri, 2010). At 6 months of follow up, the radiographic evaluation showed blending of the graft with the surrounding bone which indicated osseous ingrowth in the hydroxyapatite material. At 9 months of follow up, the radiographic evaluation displayed uniform radiopacity of the graft followed by the follow up of 12 months i.e, uniform radiopacity of the graft and surrounding bone was observed in cases of Mta Angelus. Therefore, the size of the lesion reduced from 7.11mm vertically, 10.42mm horizontally to 2.66mm vertically and 3.8mm horizontally by the use of retrograde material during apicoectomy within one year follow up.<sup>8</sup>

#### **IV. Conclusion**

On basis of numerous investigations and clinical trials, MTA can be suggested as a biocompatible root-end filling material. Newly introduced materials have also shown comparable biocompatibility with potential to provide favorable environment for cell, showing cell proliferation and osteogenic capability but further researches and clinical trials are required.

#### **References**

- [1]. **Saxena P.** Biocompatibility of root-end filling materials: recent update Restor Dent Endod. 2013 Aug; 38(3): 119–127
- [2]. **Bhagwat SA, Hegde S, Mandke LP.** An investigation into the effectiveness of periapical surgery with Biodentine™ used as a root-end filling alone or in combination with demineralized freeze-dried bone allograft and plasma rich fibrin: A 6 months follow-up of 17 cases. Endodontology 2016;28:11- 7.
- [3]. **Carrotte P.** Surgical endodontics. BRITISH DENTAL JOURNAL. JANUARY 22 2005; VOLUME 198 NO. 2
- [4]. **G Caron et al.** Use of a new retrograde filling material (Biodentine) for endodontic surgery: two case reports International Journal of Oral Science advance online publication. 9 May 2014.
- [5]. **William Ha.** The properties of Mineral Trioxide Aggregate and how it can be manipulated. Australian Society of endodontology. 2015.
- [6]. **Silva W J D, Souza P H C, Rosa E A R, Cury A A D B, Rached R N.** Rev. odonto ciênc. 2010;25(4):386-390
- [7]. **Xavier C B, Weismann R, Oliveira M G, Demarco F F, Pozza D H.** Root-end filling materials: apical microleakage and marginal adaptation. J Endod. 2005 Jul;31(7):539-42
- [8]. **Alshehri M A.** CBCT applications in dental practice: A literature review, 2010

r.Panna Mangat" Periapical Surgery of Left Lateral Incisor Using Mta Angelus as a Root End Filling Material-A Case Report" IOSR Journal of Dental and Medical Sciences (IOSR-JDMS), vol. 18, no. 5, 2019, pp 71-74.