

Vats in Penetrating Thoracic Injuries: Study from A Tertiary Care Hospital, Guntur.

Dr. Dasari Kalyani Rama MS Mch¹, Dr. S. Seetha Ramaiah, Prof & HOD²,
Dr. B. Trinath Kumar³, Dr. B. Venu Gopalan⁴, Dr. S. Vikram Mourya⁵.

(Cardio Vascular and Thoracic Surgery), Assistant Professor, Department of Cardio Vascular and Thoracic Surgery, Government General Hospital, Guntur Medical College, Guntur, Andhra Pradesh.

Department of Anaesthesia, Government General Hospital, Guntur Medical College, Guntur, Andhra Pradesh.

Assistant Professor, Department of Anaesthesia, Government General Hospital, Guntur Medical College, Guntur, Andhra Pradesh.

Assistant Professor, Department of Anaesthesia, Government General Hospital, Guntur Medical College, Guntur, Andhra Pradesh.

3rd year Post Graduate, Department of General Surgery, Government General Hospital, Guntur Medical College, Guntur, Andhra Pradesh.

Corresponding Author: Dr. Dasari Kalyani Rama, Corresponding Author Mail Id: dr.kalyanirama@gmail.com

Abstract

Introduction: Penetrating chest injuries constitute 1–13% of thoracic trauma hospital admissions. To diagnose missed injuries, chronic sequelae and late mortality; Video-assisted thoracoscopic surgery (VATS) is safe and effective.

Material & Methods: The present study was conducted in the Department of Cardiovascular and Thoracic Surgery, Government General Hospital, Guntur Medical College, Guntur to review the experience with VATS in the management of penetrating thoracic injuries. Inclusion criteria was stable hemodynamic condition, ability to tolerate single lung ventilation and maintain lateral decubitus position. Study period was from November 2017 to September 2018.

Results: Total number of patients with thoracic trauma during the study period were 127. Out of whom, nine were penetrating injuries. VATS was performed in six patients and rest three patients underwent thoracotomy. Among six patients, mean age was 32 years. Sex wise, 4 were males and 2 females. Five had right sided penetrating injury and one left sided. Indications for thoracoscopy were management of retained and persistent pneumothorax, infected pleural space collections, evaluation of diaphragm and ongoing bleed.

Conclusions: VATS is safe & reliable with effective alternative to thoracotomy in managing penetrating chest injuries in hemodynamically stable patients.

Keywords: thoracic injuries, penetrating, VATS, effective, safety

Date of Submission: 20-04-2019

Date of acceptance: 04-05-2019

I. Introduction

Due to multiplicity of the factors, thoracic injuries are on the rise to be the second most common traumatic injury^[1]. Chest trauma is an important cause of morbidity and mortality. It could be as a result of penetrating injury or a blunt trauma. While the blunt trauma is common, penetrating trauma could be life threatening^[2].

Thoracic trauma represents a major diagnostic and therapeutic challenge to surgeons. The approach to diagnosis and treatment of injuries to the chest depends on greatly on the mechanism of injury and the evidence and type of the associated injury.

In the vast majority of traumatized patients, the traumatic force is applied to and through the chest wall, making trauma to the ribs and sternum the most common of all thoracic injuries and therefore a subject of considerable importance.

The majority of chest trauma does not require major operations and tube thoracostomy remains the basis of the treatment. While there is no doubt that urgent thoracotomy remains an important lifesaving intervention, but in patients who are hemodynamically stable, thoracoscopy or video-assisted thoracic surgery (VATS) has a definite role in timely assessment and treatment^[3].

Video-Assisted Thoracoscopic Surgery (VATS) is minimally invasive thoracic surgery that does not use a formal thoracotomy incision. VATS provides adequate visualization and is principally employed in the management of pulmonary, mediastinal and pleural pathology. The advantage of VATS is that avoidance of a

thoracotomy incision which further allows a shorter operating time, less post-operative morbidity, and earlier return to normal activity^[4].

The objective of the study was to review the experience with VATS in the management of penetrating thoracic injuries in Government General Hospital, Guntur Medical College, Guntur.

II. Material And Methods

The present hospital based observational study was conducted in the Department of Cardiovascular and Thoracic Surgery, Government General Hospital, Guntur Medical College, Guntur which is a tertiary care centre.

It was intended to review the experience with VATS in the management of penetrating thoracic injuries admitted in the hospital from November 2017 to September 2018.

Inclusion criteria:

- Stable or normal hemodynamic condition
- Ability to tolerate single lung ventilation
- Maintain lateral decubitus position

Initial assessment, resuscitation and stabilization was performed. Routine investigations were done and specific investigations such as chest radiographs, ultrasound chest and computerized tomography (CT) chest also were done as indicated.

VATS was performed only in hemodynamically stable patients meeting the inclusion criteria. Procedure was carried out in the operating room under general anesthesia and thoracic epidural. A double lumen endotracheal tube of 7.5 mm was used with uniport/2-port/3-port access with 30 degree scope in lateral decubitus position.

A predesigned proforma was used to get the required information. The basic demographic data, type of traumatic injury, procedures performed, indication for VATS, post-operative outcome, length of hospital stay and other required details were collected.

Statistical analysis was done by using Microsoft Excel 2010 and EPI INFO 7 version. Data was presented in percentages and proportions.

III. Results

A total of 127 patients with thoracic trauma were admitted in the Department of Cardiovascular and Thoracic Surgery, Government General Hospital, Guntur Medical College, Guntur during the study period from November 2017 to September 2018.

Out of the 127 admitted cases of thoracic trauma, nine patients had penetrating injuries. And among the total 9 cases of penetrating injuries, Video-Assisted Thoracoscopic Surgery (VATS) was performed in six patients and rest three patients underwent thoracotomy.

Table 1: Total cases and type of procedure done during the study period

Total number of patients with thoracic trauma	127
Total penetrating injuries	09
VATS	06
Thoracotomy	03

Demographic characteristics found that the mean affected age presenting with penetrating thoracic injuries and underwent VATS was 32 years indicating a younger age group being affected.

Sex distribution among the six cases of VATS found a male preponderance with 4 males among whom VATS was performed and rest two were females.

Anatomical distribution of the injury revealed majority (n=5) had right sided and only 1 cases had left sided distribution. Location was cranially nipple line and caudally costal margin.

Table 2: Demographic and clinical characteristics

Characteristic	Number
Sex distribution	
Male	04
Female	02
Mean age (years)	32
Anatomic distribution	
Right sided	05
Left sided	01

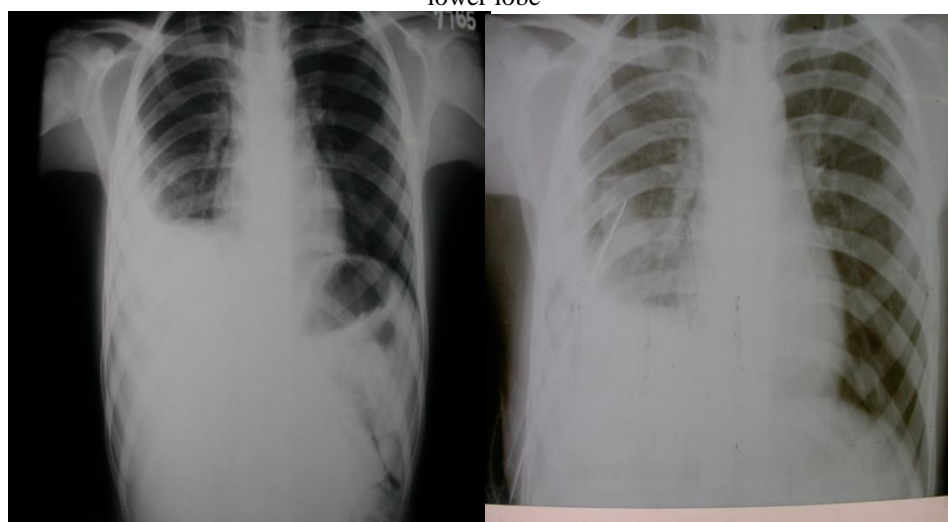
Table 3: VATS

VATS	Number
Diaphragmatic injury	01
Intercostal artery	01
Diaphragmatic artery	01
Pulmonary parenchyma laceration	01
Missed diaphragmatic injury	01
Latefibrothorax and empyema	01

The main indications of VATS in the present study were management of retained haemothorax, management of persistent pneumothorax, evaluation of the diaphragm in penetrating thoraco-abdominal injuries and management, management of infected pleural space collections and diagnosis and management of on-going bleeding in hemodynamically stable patients. ICD placement was converted to VATS for empyema thoracis, persistent pneumothorax, missed injuries of diaphragm, artery of diaphragm and intercostal artery.

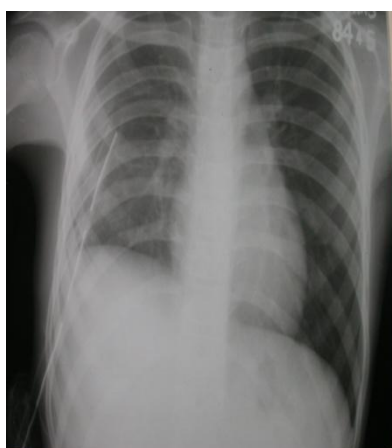Outcome: With regards to hospital stay, the average number of days of hospital stay was 5 days with no hospital mortality in the present study.

Figure 1: Chest Skiagram in a patient with Pleural collection right hemithorax with partial collapse of right lower lobe



12 year old female with right hemothorax

After ICTD



After VATS

IV. Discussion

Thoracotomy is a major operation with associated risk of morbidity and mortality. Because the morbidity from VATS is much lower, it can be implemented with a lower degree of suspicion and thus allow earlier direct inspection of the intrathoracic organs and chest wall^[5]. VATS allows complete visualization of the diaphragm, thoracic cavity, mediastinum and pericardium. VATS facilitates identification and evaluation of residual hemothorax and empyema^[6].

The present hospital based observational study conducted in the Department of Cardiovascular and Thoracic Surgery, Government General Hospital, Guntur Medical College, Guntur which is a tertiary care centre with an objective of the study was to review the experience with VATS in the management of penetrating thoracic injuries in the institute.

Present study found that out of the 127 admitted cases of thoracic trauma, nine patients had penetrating injuries. Video-Assisted Thoracoscopic Surgery (VATS) was performed in six patients. Mean age was 32 years. Sex wise, 4 were males and 2 females. Five had right sided penetrating injury and one left sided. Indications for thoracoscopy were management of retained and persistent pneumothorax, infected pleural space collections, evaluation of diaphragm and ongoing bleed. Mean duration of hospital stay was 5 days with no hospital mortality.

Similar findings were observed in study by Goodman M et al^[7] on video assisted thoracoscopic surgery for acute thoracic trauma where out of twenty-three patients, 3 (13%) had blunt injury and 20 (87%) penetrating trauma. Indications for urgent thoracoscopy included diaphragmatic/esophageal injury, retained hemothorax, ongoing hemorrhage, and open/persistent pneumothorax. No conversions to thoracotomy were required and no patient required re-operation. Mean postoperative chest tube duration was 2.9 days and mean length of stay was 5.6 days.

Another study by Milanchi S et al^[8] found that The most common indication for VATS was retained haemothorax. Thoracotomy was avoided in 21 patients. VATS failed in two cases. On an average VATS was performed on trauma day seven (range 1-26) and the length of hospital stay was 20 days (range 3-58). There was no mortality. VATS was performed in an emergency (day 1-2), or in the early (day 2-7) or late (after day 7) phases of trauma.

A study on role of emergency VATS in blunt chest trauma patients by Gabal A, Alghorori M^[9] observed that all VAT procedures were performed within 24 hours except for 3 cases with retained haemothorax as the procedure was repeated again at day 7. Seven patients required conversion to an open thoracotomy. ICT stayed in our patients from 2 to 15 days (average 5.91 ± 2.6). The average length of stay in the hospital after VATS was 9.1 ± 2.73 days (vary from 4 to 21 days). There was no mortality.

The role of diagnostic VATS in penetrating thoracic injuries by Paci M et al^[10] revealed in the 13 patients who underwent VATS, 5 injuries to the diaphragm, 3 lesions to an intercostal artery, and 1 lesion to the diaphragmatic artery were detected. In 12 of these patients a laceration of the pulmonary parenchyma was also present. A conversion to thoracotomy was necessary due to a broad laceration of the diaphragm and due to hemostasis of an intercostal artery. In all but one case, which was later converted, diagnostic imaging missed the diagnosis of laceration of the diaphragm. There was no intra- or postoperative mortality, and average hospital stay was five days.

V. Conclusion

VATS is safe & reliable with effective alternative to thoracotomy in managing penetrating chest injuries in hemodynamically stable patients. It plays a pivotal role in reduction in the number of missed potentially missed lesions and chronic sequelae. Further extensive studies would be required to determine its safety and usefulness in acute settings.

References

- [1]. Ludwig C, Koryllos A. Management of chest trauma. *J Thorac Dis.* 2017 Apr;9(Suppl 3):S172-S177.
- [2]. Jain A, Burns B. Penetrating Chest Trauma. [Updated 2018 Dec 21]. In: StatPearls [Internet]. Treasure Island (FL): StatPearls Publishing; 2019 Jan-. Available from: <https://www.ncbi.nlm.nih.gov/books/NBK535444/>
- [3]. Laleng M, Darlong. Thoracoscopy for trauma. *Lung India* 2011;28(2):87-88.
- [4]. Lewis RJ, Caccavale RJ, Sisler GE. Imaged thoracoscopic lung biopsy. *Chest.* 1992 Jul;102(1):60-2.
- [5]. Mehmet Dakak D. The role of vats in thoracic trauma (our initial clinical experience). *Gulhane Med J.* 2003; 45(2): 218-220.
- [6]. Liu, D.W., Liu, H.P., Lin, P.J., Chang, C.H. Video-Assisted Thoracic Surgery in Treatment of Chest Trauma. *J Trauma* 42(4): 670-3, 1997.
- [7]. Goodman M, Lewis J, Guitron J, Reed M, Pritts T, Starnes S. Video-assisted thoracoscopic surgery for acute thoracic trauma. *J Emerg Trauma Shock.* 2013;6(2):106-109. doi:10.4103/0974-2700.110757.
- [8]. Milanchi S, Makey I, McKenna R, Margulies DR. Video-assisted thoracoscopic surgery in the management of penetrating and blunt thoracic trauma. *J Minim Access Surg.* 2009;5(3):63-66. doi:10.4103/0972-9941.58499.
- [9]. Gabal A, Alghorori M. Role of emergency VATS in blunt chest trauma patients. *J Cardiothorac Surg.* 2013;8(Suppl 1):O73. doi:10.1186/1749-8090-8-S1-O73
- [10]. Paci M, Ferrari G, Annessi V, de Franco S, Guasti G, Sgarbi G. The role of diagnostic VATS in penetrating thoracic injuries. *World J Emerg Surg.* 2006 Oct 5;1:30.

Dr. Dasari Kalyani Rama. "Vats In Penetrating Thoracic Injuries: Study From A Tertiary Care Hospital, Guntur." *IOSR Journal of Dental and Medical Sciences (IOSR-JDMS)*, vol. 18, no. 05, 2019, pp 01-04.