

A Rare Case Of Primary Lymphoma Of The Ovary Presenting As A Localized Ovarian Cancer

Sabrina Boukhris¹, Olfa Jaidane¹, Ghada Sahraoui², Yasmine Ayari¹, Molka Chemleli¹, Maher slimene¹, Riadh Chargui¹, Karima Mrad², Monia Hechiche¹, Khaled Rahal¹

¹ Department of Surgical oncology, Salah Azaïz Institute, Tunis, Tunisia

² Department of Immuno-Histo-Cytology, Salah Azaïz Institute, Tunis, Tunisia

Corresponding Author : Sabrina Boukhris

Abstract: Primary non hodgkin lymphoma of the ovary is an extremely rare disease. This entity must be differentiated from other ovarian neoplasms as its management is significantly different from them. A 44-year-old woman presented with signs and symptoms suggestive of an advanced ovarian cancer. Ultrasonography and CT scan showed an enlarged left ovary mass revealed bilateral abdominal tumors, each measuring 10 cm in diameter associated with a uterine but no enlarged lymph nodes. she underwent an a total abdominal hysterectomy with bilateral salpingo-oophorectomy. The histopathological examination along with immunochemistry confirmed the diagnosis of malignant ovarian lymphoma infiltrating the uterus. The tumour was classified as diffuse large B cell lymphoma of high grade. Total body work up revealed no sign of disseminated disease and The patient received six cycles of standard chemotherapy. After 34 months of initial treatment, she was still alive and disease free. True primary ovarian lymphoma (POL) has been considered to carry a favorable prognosis, although many studies of POL have reported a poor outcome.

Key words: Primary ovarian lymphoma , Ovarian tumor.

Date of Submission: 17-05-2019

Date of acceptance: 02-06-2019

I. Introduction

Involvement of the ovary in malignant lymphoma is more common as a manifestation of disseminated nodal disease [1]. The ovary is the most common genital localisation followed by uterus, vagina, and vulva [2]. However, primary ovarian lymphoma POL is extremely rare and accounts for 1.5% of all ovarian neoplasms [3]. The clinical presentation is similar to other ovarian tumors as an abdominal or pelvic mass, often accompanied by pain and, occasionally, ascites; less commonly, the tumors are incidental findings. [2]. We present a case of primary ovarian lymphoma, initially manifesting like an advanced ovarian cancer, successfully managed by surgery followed by chemotherapy.

II. Case Report

A 44-year-old nulligravida woman presented with a palpable abdominal mass that had commenced three months earlier, complicated with bowel and bladder symptoms one month previous to consultation. The patient had no comorbid medical disease requiring treatment. There was no history of irradiation and no family history of gynecological malignancy. On physical examination, a 15 cm mass was palpable in the lower abdomen associated with omeprazole. Her vulva, vagina, cervix, and anus appeared normal. The liver and spleen palpation was normal. None of the peripheral lymph nodes were enlarged. Ultrasonography and abdominopelvic CT showed an increased volume of the right ovary associated with a 10 cm complex uterine mass. The patient's serum levels of CA-125 and CA 19-9 were 21 U/mL and 4 U/mL, respectively. She underwent explorative laparotomy. The right ovary was replaced by a 7 cm white mass while the left ovary was normal. The uterine palpation revealed an irregular mass measuring 10 cm. There was no ascites, no abnormal peritoneal lesions and no pelvic or paraaortic lymph node enlargement. The patient underwent total abdominal hysterectomy with bilateral salpingo-oophorectomy. The pathological examination was not conclusive and we decided to wait for the final pathological examination. There was no macroscopic residual tumor left after surgery. Her postoperative course was uneventful.

Macroscopic examination showed a right ovarian mass with greyish white surface and focal cystic lesions. The ovarian capsule was not involved in the mass. The histopathology revealed an ovarian parenchyma massively

infiltrated by diffuse patches of large, discarded, atypical cells intermingled with lymphoid-shaped cells (Fig1). The tumor cells were positive to Leukocyte common antigen (LCA) and CD20 and negative to cytokeratin, actin, C-KIT, CD10 et CD3 (Fig2). The examination of the uterine mass revealed a 6 cm leiomyoma associated with a 3 cm lesion presenting the same characteristics as the ovarian tumor. The left ovary was free of any malignant infiltration. The final diagnosis was a primary right ovarian NHL (B-cell type phenotype of high grade) with infiltration of the uterus.

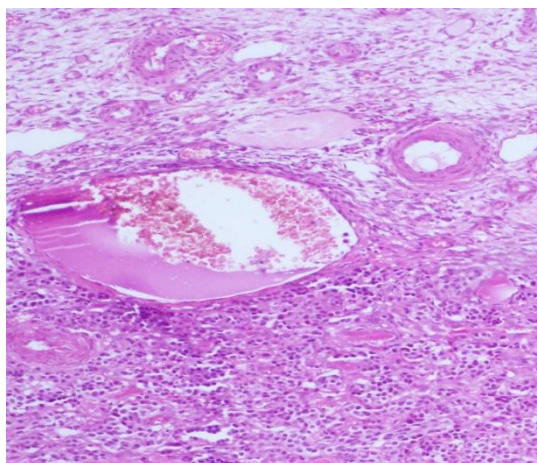


Fig 1 : (HE X100) ovarian parenchyma massively infiltrated by diffuse patches of large, discarded, atypical cells intermingled with lymphoid-shaped cells

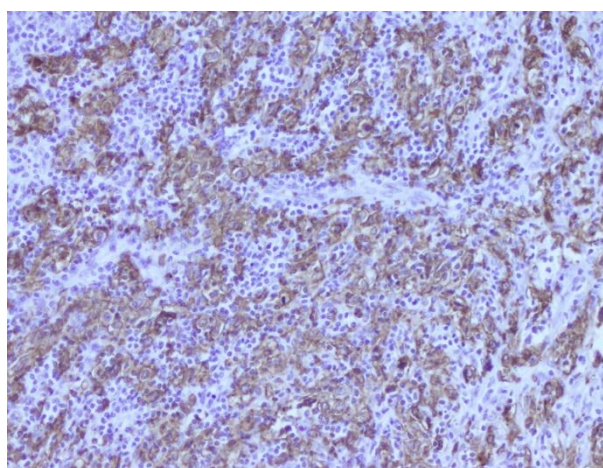


Fig 2 : (IHC X200) CD20-positive tumor cells

After this surprising histopathological findings. An elaborate clinical and radiological work-up revealed no hepatomegaly, splenomegaly or lymphadenopathy. Peripheral blood smear, bone marrow biopsy examination showed no evidence of leukemia or myeloproliferative disorder and excluded systemic NHL. Final diagnosis of primary ovarian lymphoma was made.

The patient was treated with a chemotherapy protocol consisting of six cycles of CHOP (cyclophosphamide 750mg/m², doxorubicin 50mg/m², vincristine 1.4mg/m², prednisolone 40mg/m² for 5 days) with no major side effects. Following treatment, CT scan showed no evidence of local or disseminated disease. The patient was still alive and free of disease 34 months after treatment.

III. Discussion

The involvement of the ovary during malignant systemic lymphomas is quite common and occurs in 7–26% of cases, but less than 1% of lymphoma patients initially present with ovarian enlargement [3, 4].

Although ovarian lymphoma frequently present as a part of disseminated systemic disease, Primary ovarian lymphomas (POL) are extremely rare [5-7]. It accounts for 0.5% of all non-Hodgkin's lymphoma (NHL) and 1.5% of all ovarian neoplasms [3, 6]. The majority of POL arising in the ovary are of B-cell phenotype ; among these, Burkitt lymphoma and diffuse large B-cell lymphoma are the most common types [4, 7]. Our patient had diffuse large B-cell lymphoma and immunohistochemical evaluation showed strong staining

for LCA and CD20. Ovarian lymphoma can occur at any age but it is more common in women in their forties.[2, 4].

The origin of POL is still debated, since normal ovary has no lymphoid tissue. Some authors suggest that lymphoid aggregates may be found in the ovary in some lesions such as pelvic inflammatory disease, and may undergo in some rare case a malignant transformation into POL[5]. Furthermore, Monterroso et al.[8] identified small numbers of lymphocytes in the ovaries, surrounding blood vessels in the hilus, and within or surrounding corpora lutea in 54% of lymphoma patients with ovarian involvement. Then, the scarcity of lymphoid tissue in the ovaries could explain the rarity of this entity [3].

The features of POL are similar to secondarily lymphoma involving the ovaries with respect to age, symptoms at presentation, mean tumor size, except there is a propensity for secondary ovarian lymphoma to be usually bilateral [2]. Differential diagnosis also include other ovarian tumors such as granulosa cell tumour, dysgerminoma, small cell carcinoma of hypercalcaemic type, and granulocytic sarcoma [1, 6].

The matter of whether ovarian lymphomas should be considered truly primary arising in the ovary and not merely a localized initial manifestation of a disseminated disease remain controversial. In 1976, Fox et al [9]. proposed the following criteria for the diagnosis of a primary ovarian lymphoma :

(i) At the time of the diagnosis the lymphoma is clinically confined to the ovary and a full investigation fails to reveal evidence of lymphoma elsewhere. A lymphoma can still, however, be considered as primary if spread has occurred to immediately adjacent lymph nodes or if there has been direct spread to infiltrate immediately adjacent structures.

(ii) The peripheral blood and bone marrow should not contain any abnormal cells.

(iii) If further lymphomatous lesions occur at sites remote from the ovary then at least several months should have elapsed between the appearance of the ovarian and extra-ovarian lesions.

Because of the rarity of POL, There is no clear consensus on optimal management of these patients. Most authors would advocate that surgery should be the initial treatment [2]. POL with no evidence of systemic involvement can be treated successfully with surgical excision associated with chemotherapy. The protocol for chemotherapy recommended is the standard R-CHOP regimen. Rituximab has a major role in treatment of CD20-positive B-cell lymphoma[4]

The staging system for ovarian lymphoma is quite difficult. The Ann Arbor staging system, designed for hodgkins disease, is limited in NHL especially in case of neoplasms arising at extranodal site. Some authors suggest that POL can be classified according to FIGO system, designed for ovarian neoplasms [5]. Our case was classified as FIGO stage IIA.

The study of prognosis factors of POL are limited due to its rarity. It is reported that unilateral ovarian involvement and focal dissemination may be indicators of good prognosis, while poor prognosis is usually associated with the rapid growth of pelvic mass and advanced stage at presentation[10].

After total body work up confirming the complete remission, the patient should be assessed clinically every 3 months for 2 years, every 6 months for the next 2 years, and yearly thereafter.

IV. Conclusion

Primary ovarian non-Hodgkin lymphoma is a rare entity that must be differentiated from other ovarian malignancies as its treatment and prognosis differs from them. The best treatment option seems to be chemotherapy. Oncologist and pathologist should be aware of this rare to avoid radical surgery, which is often unnecessary.

Conflict of interest : The authors declare that they have no conflict of interests regarding the publication of this paper.

References

- [1]. Sun J, Zhang J, Ling Q et al. Primary diffuse large B-cell lymphoma of the ovary is of a germinal centre B-cell-like phenotype. *Virchows Archiv.* 2015; 466: 93-100.
- [2]. Yadav BS, George P, Sharma SC et al. Primary non-Hodgkin lymphoma of the ovary. In *Seminars in oncology.* Elsevier. 2014; e19-e30.
- [3]. Yamada T, Iwano N, Kasamatsu H, Mori H. A case of malignant lymphoma of the ovary manifesting like an advanced ovarian cancer. *Gynecol Oncol.* 2003; 90: 215-219.
- [4]. Senol T, Doger E, Kahramanoglu I et al. Five cases of non-hodgkin B-cell lymphoma of the ovary. *Case reports in obstetrics and gynecology.* 2014; 2014.
- [5]. Ambulkar I, Nair R. Primary ovarian lymphoma: report of cases and review of literature. *Leukemia & Lymphoma.* 2003; 44: 825-827.
- [6]. Yadav BS, George P, Sharma SC et al. Primary non-Hodgkin lymphoma of the ovary. In *Seminars in oncology.* 2014; e19.
- [7]. Özsan N, Bedke BJ, Law ME et al. Clinicopathologic and genetic characterization of follicular lymphomas presenting in the ovary reveals 2 distinct subgroups. *Am J Surg Pathol.* 2011; 35: 1691-1699.
- [8]. Monterroso V, Jaffe ES, Merino MJ, Medeiros LJ. Malignant lymphomas involving the ovary. A clinicopathologic analysis of 39 cases. *Am J Surg Pathol.* 1993; 17: 154-170.

- [9]. Fox H, Langley F, Govan A et al. Malignant lymphoma presenting as an ovarian tumour: a clinicopathological analysis of 34 cases. *Int Obstet Gynaecol.* 1988; 95: 386-390.
- [10]. Guvvala SL, Sakam S, Niazi M, Skaradinskiy Y. Case of primary bilateral diffuse large B-cell lymphoma of the ovary with plasmablastic features in an HIV-negative female patient. *BMJ case reports.* 2017: bcr2016218117

Sabrine Boukhris. “ A Rare Case Of Primary Lymphoma Of The Ovary Presenting As A Localized Ovarian Cancer.” *IOSR Journal of Dental and Medical Sciences (IOSR-JDMS)*, vol. 18, no. 5, 2019, pp 38-41.