

Intramuscular Hematoma As A Cause For Trismus Following Inferior Alveolar Nerve Block:- A Special Consideration For Patients On Antiplatelet Therapy.

Dr.Sailesh Kumar Mukul, Dr.Pranav Santhalia, Dr.Amit kumar, Dr.

Abhishek Singh, Dr. Sumit Singh, Dr. Shweta Pandey

Corresponding Author:- Dr. Amit Kumar

Abstract: Background: A dental patient under anticoagulant medication is a challenge for dentists, as anti-coagulant therapy produces an increase risk of bleeding. Bleeding following Inferior alveolar nerve block may lead to formation of intramuscular hematoma ultimately resulting in trismus. Since such complications are inevitable, their prevention and management are essential. Comprehensive knowledge is required for the management of such complications and injection techniques to prevent these complications. In this case report authors have discussed about the possible role of free haemoglobin in triggering specific pathophysiology that are associated with adverse clinical outcome in a patient undergoing hematoma lysis. This case report emphasize on management part of such complication and how a meticulous history and special precaution can help in preventing such complications in patients undergoing antiplatelet drug therapy.

Keywords: Inferior alveolar nerve block , antiplatelet therapy, intramuscular hematoma, trismus

Date of Submission: 10-05-2019

Date of acceptance: 27-05-2019

I. Introduction

Inferior alveolar nerve block (IANB) is a routine local anesthetic procedure and is generally considered very safe. ^[1] Since it is an invasive technique, it has many inherent potential risks for the patients. IANB complications may include pain or burning sensation, tissue blanching, penetration of a blood vessel, oedema, hematoma, trismus, nerve damage, facial nerve paralysis, needle breakage and adverse drug reactions (overdose, allergy or idiosyncrasy). ^[2-4]

Trismus is a painful condition that restricts normal jaw movement and function as a result of masticatory muscle spasms. In this condition patients are unable to open the mouth within the normal range of 35 to 45 mm. ^[5,6] Trismus has a number of potential causes, which range from the simple and non-progressive to those that are potentially life-threatening. ^[5,6] Pain and trismus following IANB produced by tearing the mucosa during insertion or even by the withdrawal of the needle, needle breakage at that point of injection, extensive prolonged bleeding leading to intramuscular hematoma and infection. ^[7,8] Occasionally, muscles of mastication is accidentally penetrated or a vessel is punctured and a small bleed follows: a haematoma can occur in the muscle bed and subsequently organize, causing a fibrosis. Trismus due to this cause can be protracted and quite severe. ^[9] Intramuscular hematoma is characterized by the integrity of epimysium and by blood extravasation into the body of the muscle affected by the trauma. Intramuscular hematomas are considered a more serious condition because the intact fascia creates an increasing of muscle pressure. ^[10] Harn and Durham surveyed 9587 patients after they had received conventional IANB anaesthesia and reported that 0.54% experienced post-injection complications including trismus. ^[11]

Antiplatelet and anticoagulants are commonly prescribed drugs in elderly who have cardiovascular ailments. Hematoma formation due to bleeding tendencies is frequently encountered in patients receiving antiplatelet therapy. In this context, the following case report presents a subject, on antiplatelet drug therapy, who underwent endodontic treatment in the left lower second molar tooth. The remarkable feature in this case is that the subject developed trismus on the third day following the procedure for which IANB was given.

II. Case Report

Intramuscular Hematoma as a Cause for Trismus following Inferior alveolar nerve Block :- A special

A patient, 75 year-old man – hypertensive ,cardiovascular compromised and diabetic and on medication Clopitab (Clopidogrel) 75 mg, Cardace (Ramipril) 2.5 mg, Storvas 10 mg and Pioz MF since 1 year, had visited his dentist 10 days previously for restorative procedure of left lower second molar tooth. Inferior alveolar nerve block was given to obtain anesthesia for root canal procedure in respect to mandibular left second molar. The following day the patient felt that the jaw as a “bit sore” but no great discomfort was encountered. On the third day following treatment he noticed trismus developing. There was still no spontaneous pain, but pain did occur if the patient attempted to open the jaw forcibly.

Patient was then referred for Oral & Maxillofacial consultation. On examination, it was found that the lateral excursions were limited to approximately 2 mm bilaterally [Figure:- 1,2]. The protrusive movement was also limited to an estimated 2 mm [Figure:- 3] and interincisal mouth opening was 15 mm [Figure 4]. There was slight tenderness in the medial pterygoid and temporalis muscle with mild swelling in the mouth, face or neck. The patient was not having a history of joint sounds, pain, or any previous limitation of mandibular movement. The clinical features were not attributed to Temporomandibular Joint disorder. Magnetic resonance imaging (MRI) revealed subacute hematoma in left temporalis muscle [Figure:- 5].

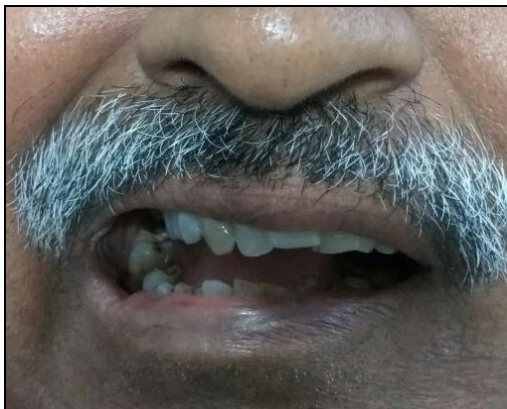

Fig 1:- Showing Right lateral excursions.

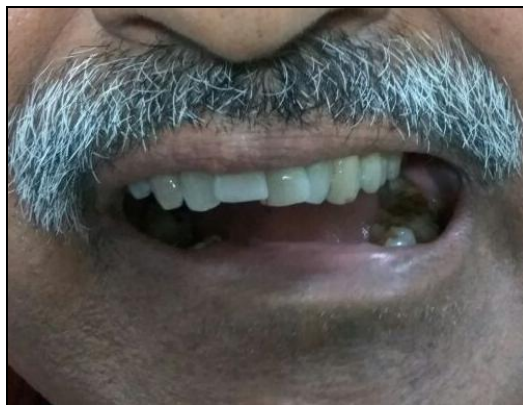

Fig 2:-Showing Left lateral excursions.

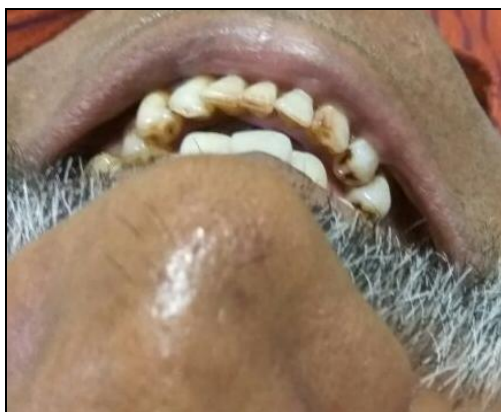

Fig 3:- Showing restricted Protrusive Movement.

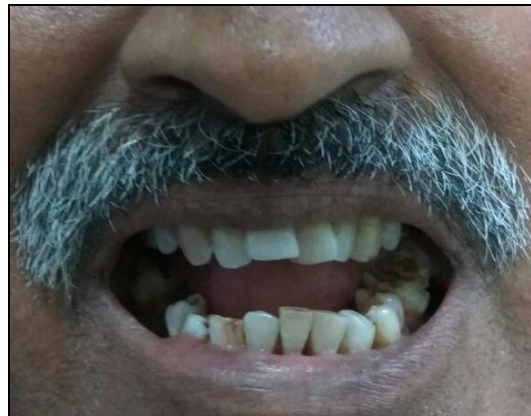

Fig 4 :- Showing restricted mouth opening.

Patient was kept on heat therapy:- placement of moist hot towels on the affected area for 10-20min/h, Analgesics:- Paracetamol (500mg) + Aceclofenac (100mg) twice daily for 5 days, Antibiotics:- containing Amoxicillin 500 mg and clavulanic acid 125mg thrice daily for 5 days, Muscle relaxants:- Benzodiazepines 2.5-5 mg 3 times a day and physiotherapy was advised. In physiotherapy patient was instructed for opening and closing, as well as lateral excursion, of the mandible for 5 minutes every 3 to 4 hours. This was done to prevent the organization, fibrosis, and contraction that are typical when the patient is treated only with rest. Patient was then recalled regularly after every 1 week for re-evaluation. After 1 month follow-up patient had excellent lateral excursions and opened his jaw upto 45 mm between the upper and lower incisors [Figure 6]. **Figure 7** shows the resolution of hematoma in the left temporalis muscle 1 month Postoperative.

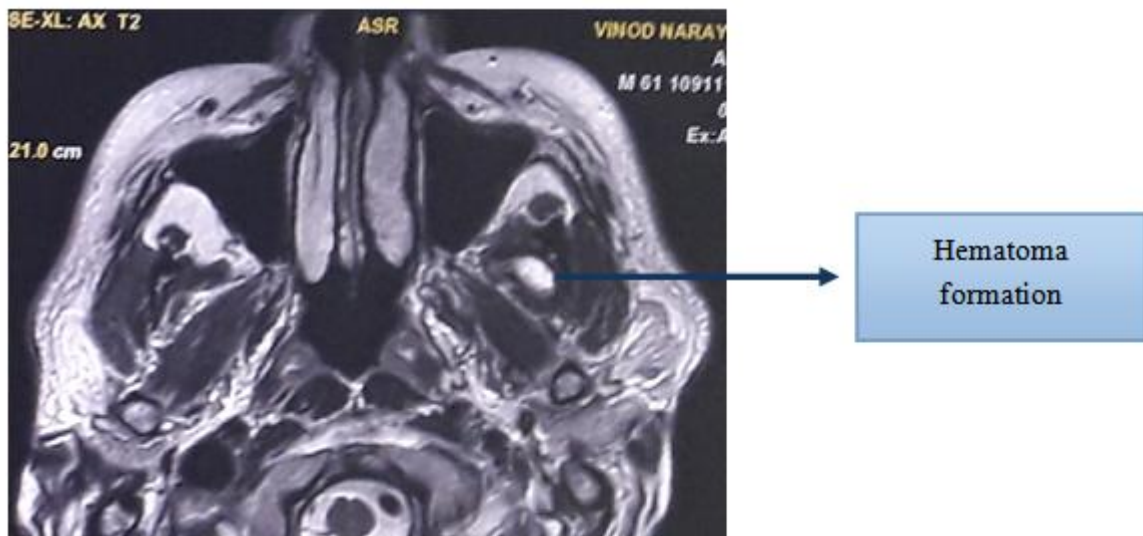


Fig 5 :- T2 image showing subacute hematoma in the left temporalis muscle (Preoperative).

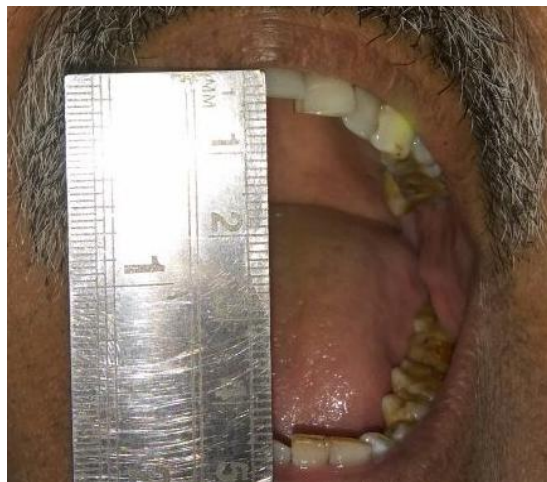

Fig 6 :- Patient Mouth opening upto 45 mm (Postoperative)

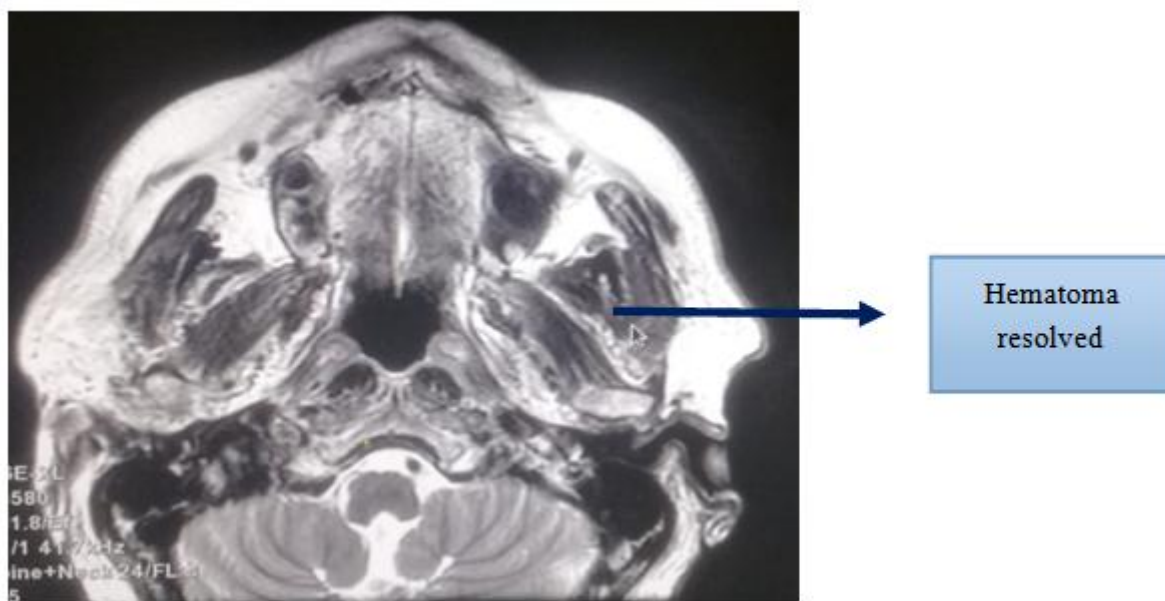


Fig 7:- MRI image showing resolution of hematoma in the left temporalis muscle (1 month Postoperative).

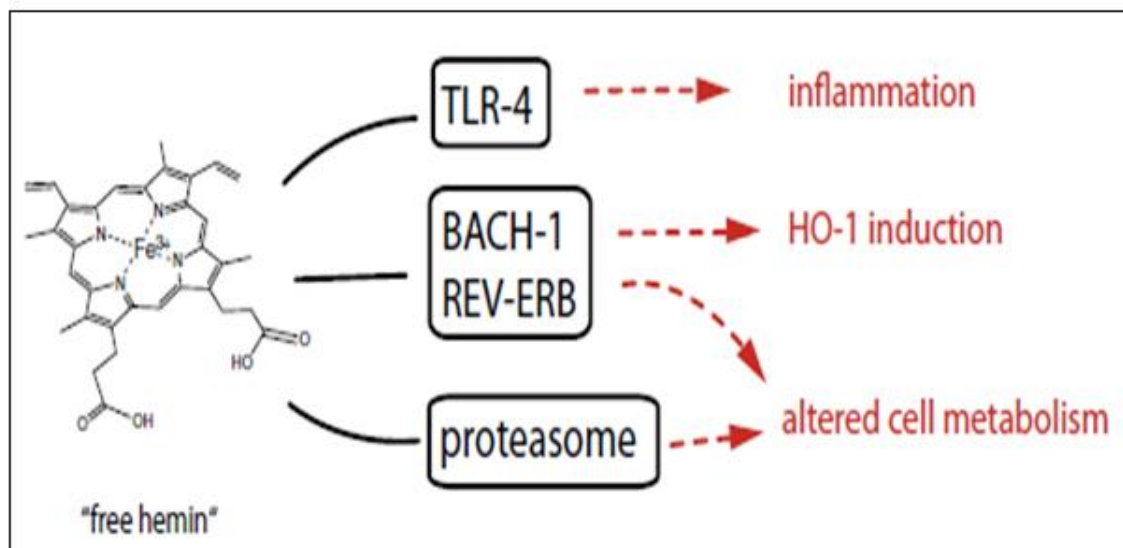


Fig 8:- Showing HB toxicity causing inflammation in muscles.

III. Discussion

Inferior alveolar artery and vein often get accidentally penetrated while giving Inferior alveolar nerve block (IANB) which leads to intramuscular hematoma.^[12] In the acute phase of intramuscular trauma, pain due to hemorrhage leads to muscle spasm and limitation of motion. If treatment is not instituted, there will be a progression to chronic limitation of movement. Chronic hypomobility is secondary to organization of the hematoma with subsequent fibrosis and scar contracture. The anterior attachments of the temporalis muscle as well as the medial pterygoid muscle are at risk of injury during administration of a mandibular nerve block.^[1] Similar type of complications, as presented in this case report, was observed by Smyth et al^[2] where they had reported two cases with trismus and sensory deficit that arose during resolution of trismus as a delayed complication of inferior alveolar nerve block. In our case report patient may have been particularly prone to hematoma formation following IANB due to a long history of antiplatelet drug therapy.^[13]

An antiplatelet agent is described as a drug whose main effect is to inhibit the aggregation of thrombocytes and, therefore, the formation of a thrombus or clot inside the arteriovenous system. Patients undergoing antiplatelet therapy show a higher haemorrhage risk due to which there is a greater chance of intramuscular hematoma formation.^[13] In subsequent stages hematoma undergoes hemolysis and results in the release of free hemoglobin. When hemoglobin (Hb) bursts from RBCs, the naked Hb, devoid of its antioxidant sentries that are normally available within the RBC, can wreak oxidative havoc in exposed tissues.^[14]

It has also been suggested that activation of Toll-like receptor 4 (TLR4) is one of the ways in which the ‘danger signal’ of free heme is detected. High concentrations of heme (50 mM) triggered TLR4-mediated IL-8 production in the human. The role of heme in inflammation can be either protective or harmful: small concentrations of heme can rapidly up-regulate heme oxygenase-1 (HO-1) and have cytoprotective effects,^[15] whereas accumulation of large amounts of heme that exceed the neutralizing capacity of heme-binding proteins or HO-1 may be deleterious in tissues via its pro-oxidative and pro-inflammatory actions [Figure 8].^[16]

There are some recommendations about lessening the risk of haemorrhagic complications related to the IANB in patients prone to a haemorrhagic response. It is usually emphasised that IANB should be used “cautiously”,^[17] without any additional explanation. Carter et al^[18] cited the advantages of short needles of small diameter (27 G), and relatively slow infusion of local anesthetic (lasting over a minute). These suggestions should be followed whenever possible. It seems that slow advancement of the needle together with repeatedly injecting the local anesthetic while advancing the needle contributes to avoiding injury to the blood vessel.

Early treatment should be geared toward the prevention of chronic hypomobility. Usually in acute muscle injury the treatment protocol initially starts with the RICE (Rest, Ice, Compression and Elevation) and PRICE (Protection, Rest, Ice, Compression and Elevation) principle.^[19] As this case was referred to our department after 10 days of masticatory muscle injury. We started with **1. Heat therapy** (Placement of moist hot towels on the affected area for 10–20 min/h) :- which results in pain relief, increases in blood flow and metabolism, and increased elasticity of connective tissue. **2. Analgesics therapy** – Analgesic containing Paracetamol (500mg) + Aceclofenac (100mg) was started twice daily for 5 days. It reduces associated pain and inflammation. **3. Muscle relaxants** - Benzodiazepines 2.5–5 mg 3 times a day was advised. **4. Antibiotics:-** Antibiotic containing Amoxicillin 500 mg and clavulanic acid 125 mg thrice daily for 5 days **5. Soft diet**^[20].

Physiotherapy can be started after cessation of the acute phase. Physiotherapy includes exercises which relax the masticatory muscles and strengthen them. Mouth opening can be achieved in a gradual manner by devices such as the wooden top or bunch of ice cream sticks inserted between the teeth to keep the mouth open. The goals of physiotherapy include: Edema reduction, softening and stretching of scar tissue, increase in the range of joint movement and increase in the strength of masticatory muscles.^[21] Forced opening of the jaw under general anesthesia can be done when all other treatment modalities is not of great help. Manipulation under anesthesia can cause instability of temporomandibular joint.^[22]

IV. Conclusion

Mandibular anaesthesia is an essential part of clinical practice for dental and local surgical procedures in the oral region. Dental surgeon should be well aware of IANB complications, its prevention and immediate management especially in patients who are on antiplatelets drug therapy. It is advisable to use intraligamentary or intraseptal techniques of local anaesthesia in these patients, as they are safer in that they are less likely to provoke haemorrhagic complications. In the future, we believe that computer- assisted systems will develop which will determine the three dimensional relationships between the structure of the mandible, the location of the mandibular foramen, and the injection needle, thereby preventing the formation of intramuscular hematoma in such medically compromised patients.

References

- [1]. Haas DA. Localized complications from local anesthesia. *J Calif Dent Assoc* 1998;26:677-82.
- [2]. Smyth J, Marley J. An unusual delayed complication of inferior alveolar nerve block. *Br J Oral Maxillofac Surg* 2010;48:51-2.
- [3]. Augello M, von Jackowski J, Grätz KW, Jacobsen C. Needle breakage during local anesthesia in the oralcavity – A retrospective of the last 50 years with guidelines for treatment and prevention. *Clin Oral Investig* 2011;15:3-8.
- [4]. Tzermpos FH, Cocos A, Klefogiannis M, Zarakas M, Iatrou I. Transient delayed facial nerve palsy after inferior alveolar nerve block anesthesia. *Anesth Prog* 2012;59:22-7.
- [5]. Stone J, Kaban LB. Trismus after injection of local anaesthetic. *Oral Surg Oral Med Oral Pathol* 1979; **48**: 29–32.
- [6]. Malamed SF. *Handbook of Local Anesthesia*, 3rd ed. St. Louis: C.V. Mosby Co., 1990; pp.248–249.
- [7]. Wright EF. Medial pterygoid trismus (myospasm) following inferior alveolar nerve block: case report and literature review. *Gen Dent*. 2011;59(1):64-7.
- [8]. Brown AE. Persistent limitation of opening following inferior alveolar nerve block injections. *Br Dent J*. 1976;141(6):186-90.
- [9]. Stacy GC, Hajjar G. Barbed needle and inexplicable paresthesias and trismus after dental regional anesthesia. *Oral Surg Oral Med Oral Pathol* 1994; **77**: 585–586.
- [10]. Klein, J. H. Muscular hematomas: diagnosis and management. *J Manipulative Physiol Ther.* (1990). Feb., 13(2), 96-100.
- [11]. Harn SD, Durham TM. Incidence of lingual nerve trauma and postinjection complications in conventional mandibular block anesthesia. *J Am Dent Assoc* 1990;121:519-23.
- [12]. Malamed S. *Handbook of Local Anesthesia*. 6th ed. Maryland Heights: Mosby; 2012;157-253.
- [13]. Sáez-Alcaide LM, Sola Martín C, Molinero Mourelle P, Paredes-Rodríguez V, Zarrias-Caballero C, Hernández-Vallejo G. Dental management in patients with antiplatelet therapy: A systematic review. *J Clin Exp Dent*. 2017;9(8):e1044-50.
- [14]. Schaer DJ, Buehler PW, Alayash AI, Belcher JD, Vercellotti GM. Hemolysis and free hemoglobin revisited: exploring hemoglobin and heme scavengers as a novel class of therapeutic proteins. *Blood*. 2013;121(8):1276–84.
- [15]. Hayashi S, Takamiya R, Yamaguchi T et al. Induction of heme oxygenase-1 suppresses venular leukocyte adhesion elicited by oxidative stress. *Circ Res* 1999; 85: 663–671.
- [16]. Nath KA, Haggard JJ, Croatt AJ, Grande JP, Poss KD, Alam J. The indispensability of heme oxygenase-1 in protecting against acute heme protein-induced toxicity in vivo. *Am J Pathol* 2000;156: 1527–1535.
- [17]. Perry DJ, Noakes TJ, Helliwell PS, for the British Dental Society. Guidelines for the management of patients on oral anticoagulants requiring dental surgery. *Br Dent J* 2007;**203**:389–93.
- [18]. Carter G, Goss AN, Lloyd J, Tocchetti R. Current concepts of the management of dental extractions for patients taking warfarin. *Aust Dent J* 2003;**48**:89–96.
- [19]. Thorsson, O, Lilja, B, Nilsson, P, & Westlin, N. Immediate external compression in the management of an acute muscle injury. *Scand J Med Sci Sports*. (1997). Jun.; 7(3),182-90.
- [20]. Tveteras K, Kristensen S. The aetiology and pathogenesis of trismus. *Clin Otolaryngol* 1986;11:3S3-fi7.
- [21]. O'brien PJ, Gropper PT, Tredwell SJ, Hall JG. Orthopaedic aspects of the trismus Pseudocamptodactyly syndrome. *J Pediatr Orthop* 1984;4:469-71.
- [22]. Dijkstra PU, Kropmans TJ, Tamminga RY. Modified use of a dynamic bite opener-treatment and prevention of trismus in a child with head and neck cancer: A case report. *CRANIO®* 1992;10:327-29.

S K Mukul, P Santhalia, A Kumar, A Singh, S Singh, S Pandey et al. “Intramuscular Hematoma As A Cause For Trismus Following Inferior Alveolar Nerve Block :- A Special Consideration For Patients On Antiplatelet Therapy.” *IOSR Journal of Dental and Medical Sciences (IOSR-JDMS)*, vol. 18, no. 5, 2019, pp 26-30.