

Role of MRI & MR Spectroscopy (Metabolic Mapping) In Characterization of Ring Enhancing Lesions in Brain

Dr.Sarita Mirchandani, Mr. Jaival Dave, Dr. Asutosh N. Dave

2nd year resident doctor(MD Radiodiagnosis) Department of radio-diagnosis, GCS Medical college,
Ahmedabad, Gujarat, India

Final year MBBS student, NHL Medical College, Ahmedabad, Gujarat, India

MD Radiodiagnosis, Professor and head, GCS Medical college, Ahmedabad, Gujarat, India.

*Corresponding author: Dr.Sarita Mirchandani

Abstract

Metabolic Mapping includes use of MRI and MR spectroscopy in differentiating various ring enhancing lesions like abscess, tumour like glioblastoma multiformae, tuberculoma, radiation necrosis and metastasis. MRI has inherent sensitivity and capability to detect ring enhancing lesions. MR spectroscopy provides information about the chemical nature of ring enhancing lesions by analyzing the presence and ratio of tissue metabolites like NAA, choline, creatine, lactate, lipid etc.

Objectives

To evaluate the efficacy of metabolic mapping(MRI and MR spectroscopy) in evaluation of brain lesions that shows ring enhancement on post contrast T1 images and to determine which method is more effective.

Method and materials

40 patients with Ring enhancing lesions who were diagnosed as having abscess, tumour, metastasis, tuberculoma on MRI were subjected for MR spectroscopy using MR SIGNA EXPLORER 1.5T machine.

Duration of the study

The study was carried over period of 7 months from July 2018 to January 2019.

Result

40 patients were included in study (30 males, 10 females) ranging from 10- 65 years) conducted at Department of Radiodiagnosis at GCS medical college.

Among them 10 patients were diagnosed as tuberculoma, 2 of neurocysticercosis, 18 as brain abscess, 2 of meningioma, 5 of brain metastases and 3 of glioblastoma multiformae.

Conclusion

Both the phases of metabolic mapping i.e MRI and MR spectroscopy are efficient in characterizing ring enhancing lesions and are complementary to each other and give better results when used together rather than alone.

Keywords

MRI and MR spectroscopy, Ring enhancing lesions, tuberculoma, abscess

Date of Submission: 07-05-2019

Date of acceptance: 23-05-2019

I. Introduction

There is huge dilemma in diagnosing various ring enhancing lesions like abscess from tumor, tuberculoma from neurocysticercosis (3, 9) which impose dramatic change in treatment. Depending upon non-specific symptoms and signs and their appearances on CT scan and conventional MRI, their differentiation is challenging. It is shown that conventional MRI has only 60% sensitivity in differentiating brain neoplasms from abscess. Therefore metabolic mapping is shown to cover up the drawback of CT scan and convention MRI with significant increase in diagnostic accuracy when used together i.e MRI and MR spectroscopy.

The medical management for abscess, infection(4) and neoplasms are different. Therefore correct diagnosis must be obtained before their treatment(2, 13). An early and correct diagnosis of aerobic abscesses, tuberculoma by metabolic mapping as a non invasive method will reduce the morbidity and mortality rate.

II. Patients and Methods

The study was performed between July 2018 to January 2019. 40 patients(30 male, 10 females) with pyogenic brain abscesses, tuberculoma, cystic and necrotic brain tumours (1, 2) were included in the study, age range between 20-60 years, all patients referred from medicine and neurosurgery department of our institution. These patients had ring enhancing lesions on post contrast T1 images, all were examined with both MR and

MRS. We excluded the patients with brain lesions that showed hemorrhage on T1WI, lesions less than 1cm in diameter that were too small to be evaluated by MRS, post radiations states, large area of calcifications detected by CT.

Imaging procedures

MRI: All patients showing evidence of ring enhancing brain lesion on post contrast T1WI of conventional MRI were examined by both MRI and MRS using 1.5 Tesla MR unit with a standard head coil.

The conventional MRI included T1W (TR/TE = 500/15 ms), T2WI (TR/TE = 4000/126 ms) and FLAIR (TR/TE= 8000/142 ms, inversion time =2200 ms) sequences, contrast enhanced MRI was done for all patients after intravenous injection of gadolinium-diethylene triaminopenta-acetic acid, with dose 0.1 mmol/kg body weight. We evaluated the MRI commenting on the lesion's signal characteristics, and the presence of haemorrhage, necrosis, peritumoural oedema, mass effect and contrast enhancement(6).

MR spectroscopy of brain lesions

Some cases were evaluated by single voxel spectroscopic technique and the other cases were evaluated by multivoxel spectroscopic technique (MRS)(10).

Voxel positioning :

Single voxel positioning : It uses restricted anatomic coverage, voxel size of 2 x 2 x 2 (8cm³) .It uses short scan time , acquired in 3 - 5 mins. It gives good field homogenisity and accurate quantification of metabolites.

Multi voxel positioning : It obtains many voxels and spatial distribution of metabolites with single sequence. Voxel size is 1 x 1 x 1 cm. It gives simultaneous evaluation of affected and unaffected areas.

Pulse sequence

We used point resolved spectroscopy (PRESS) .It uses 90 degree pulse and two 180 degree pulses.

It uses spin echo that can be performed with short and long TE which used to clearly visualize peak intensity of CHO, Cr, and NAA, to obtain CHO/Cr ratio, and to determine the presence of Lac, while short TE was mainly used to illustrate Lip peak. It gives more SNR (2, 10).

Spectroscopic data analysis

Chemical compound	Chemical shift (ppm)	Comments
NAA(N acetyl aspartate)	2.0	Marker of neuronal and axonal viability
Creatine	3.0, 3.9	Cerebral metabolism marker
Choline (cho)	3.2	Reflect cellular proliferation
Myoinositol (ml)	3.6	Glial marker, cell volume regulator
Glutamate(Glu) Glutamine (Gln) Glu+ Gln = Glx	2.1-2.5	Ammonia intake
Lipids (Lip)	0.9-1.4	Indicator of necrosis, myelin sheath disruption
Lactate (Lac)	1.3	Anaerobic metabolism

NAA: decreased in neoplasm, abscess, infarction. Increased in Canavan's disease.

Creatine: Decreased in tumor, necrosis, infarction, trauma . Increased in post hepatic transplant.

Choline: Decreased in abscess, necrosis, hepatic disease. Increase in tumors, demyelination.

Lactate: Increased in hypoxia, infarction, necrosis, abscess, tumors.

Lipids: Increased in necrosis, TB, Toxoplasma, infarction.

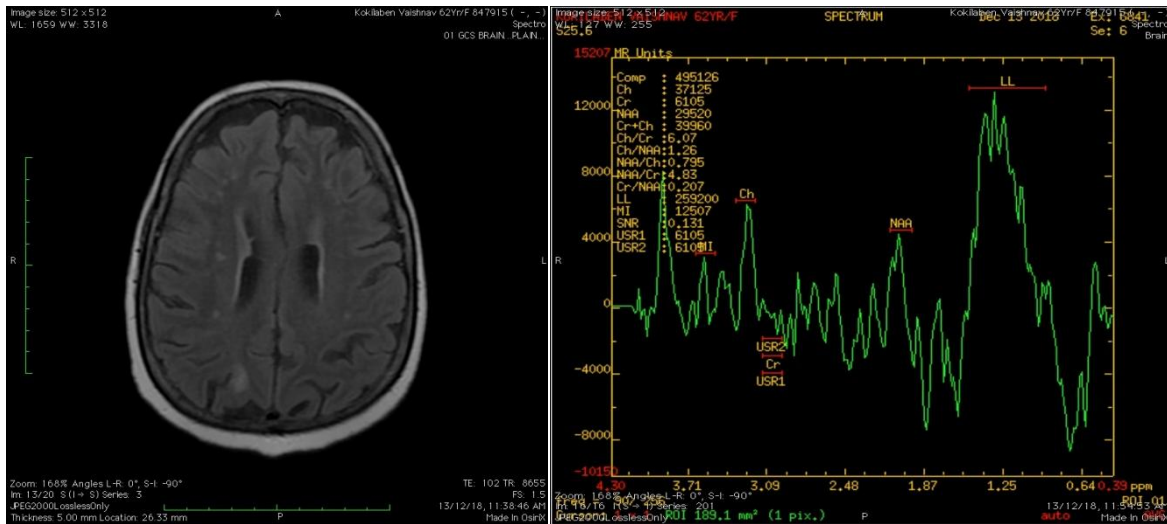
Glutamate: Decreased in Alzheimer's, hyponatremia, head injury.Increased in Meningioma,HIE.

III. Results

40 patients were included in study (30 males, 10 females) ranging from 10- 65 years) conducted at Department of Radiodiagnosis at GCS medical college .

Among them **12 patients were suspected of tuberculoma(4)** on basis of MRI findings, (appears relatively iso- to hypointense on both T1W and T2W images with an iso- to hyperintense rim on T2W images. It shows rim enhancement on

post contrast T1W images. whereas lesions with a heterogeneous



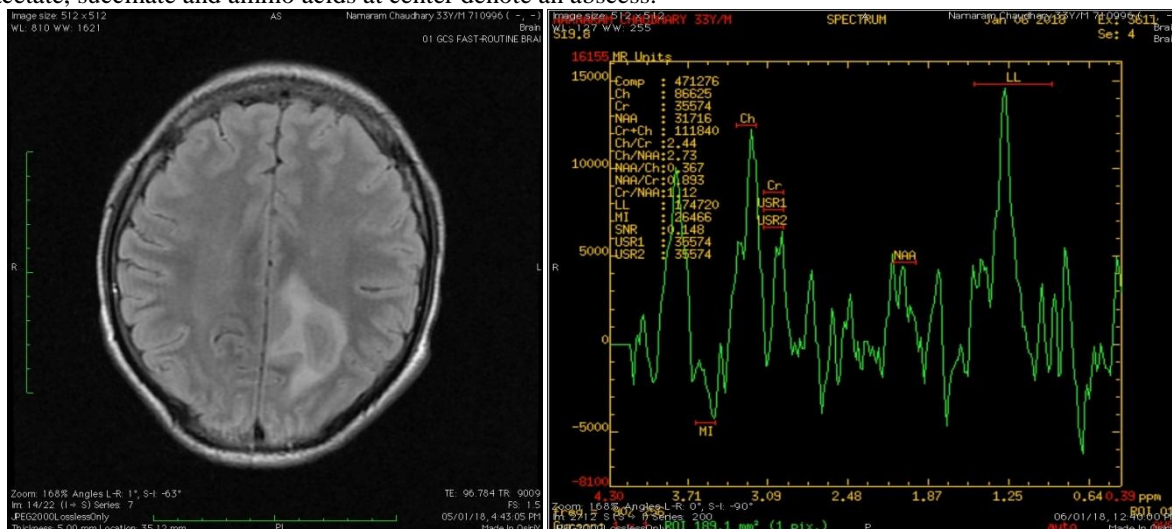
appearance show Cho at 3.22 ppm along with lipid) further MR spectroscopy confirmed the diagnosis in 10 patients by giving lipid peak, increased choline (3.22 ppm in cases with heterogeneous appearance) and decreased NAA and aspartate levels. **The choline/ creatine ratio was greater in all tuberculomas but not in 2 cases which were diagnosed as early stage neurocysticercosis(3).** Thus choline/ creatine ratio helps to differentiate between tuberculoma(4) and NCC which changes the line of treatment.

2 patients with variable findings on MRI suspected as meningiomas underwent MR spectroscopy to differentiate them from glioma. MRS showed absence of NAA, elevated choline, double inverted peak was obtained at 1.48 ppm that points to alanine. MRS support the diagnosis of non neuronal tumor. The presence of alanine peak is characteristic to differentiate meningioma(1,2,12,13) from glial tumor.

In 18 cases suspected of brain abscess, MRI and MRS was done.

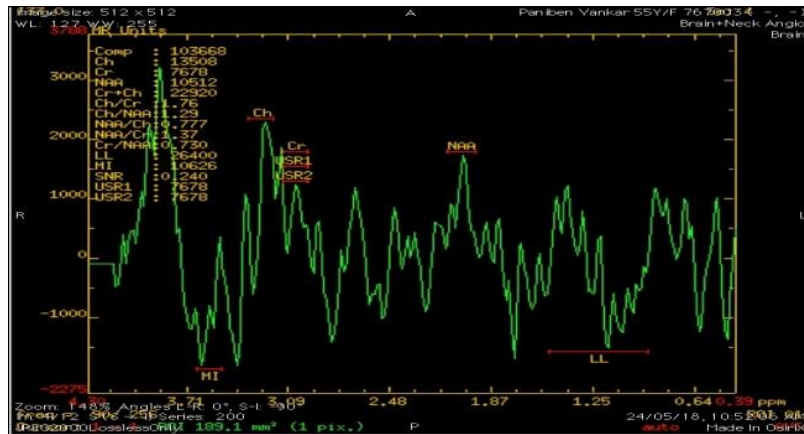
In a typical brain abscess with central liquefactive necrosis, the center of the cavity is slightly hyperintense to CSF, whereas the surrounding edematous brain is slightly hypointense to normal brain parenchyma on T1-weighted images(7,8). On unenhanced MR images, the mature, surgically drainable abscess often has a rim with distinctive features (5,11). The rim is isointense to slightly hyperintense to white matter on T1- weighted images and is hypointense on T2-weighted images. There is smooth ring enhancement of an abscess capsule on post gadolinium

MR images. Abscesses tend to demonstrate high signal intensity on DWI, with a corresponding reduction in the apparent diffusion coefficient values(7,8) . In an untreated abscess, resonances may be seen corresponding to acetate (1.92 ppm), lactate (1.3 ppm), alanine (1.5 ppm), succinate (2.4 ppm), and pyruvate, as well as a complex peak at 0.9 ppm indicating amino acids valine, leucine, and isoleucine . Thus most pyogenic abscess shows restricted diffusion. MR spectroscopy played a major role. Presence of choline indicates neoplasm, whereas presence of acetate, succinate and amino acids at center denote an abscess.



In 5 cases with ring enhancing lesions in brain suspected as metastasis 3 showed increased lipid content, absent NAA and Cr.No peritumoral increase in choline.

Majority of metastases are located in the supratentorial compartment. Intraparenchymal metastases are the most common type of metastatic disease to affect the intracranial space(10). Most common, in decreasing incidence are lung cancer, breast cancer, melanoma, gastrointestinal cancers, renal cell carcinoma and tumors of unknown primary. Metastases are notoriously surrounded by massive amounts of edema. Best delineated by conventional T2-weighted images rather than FLAIR.



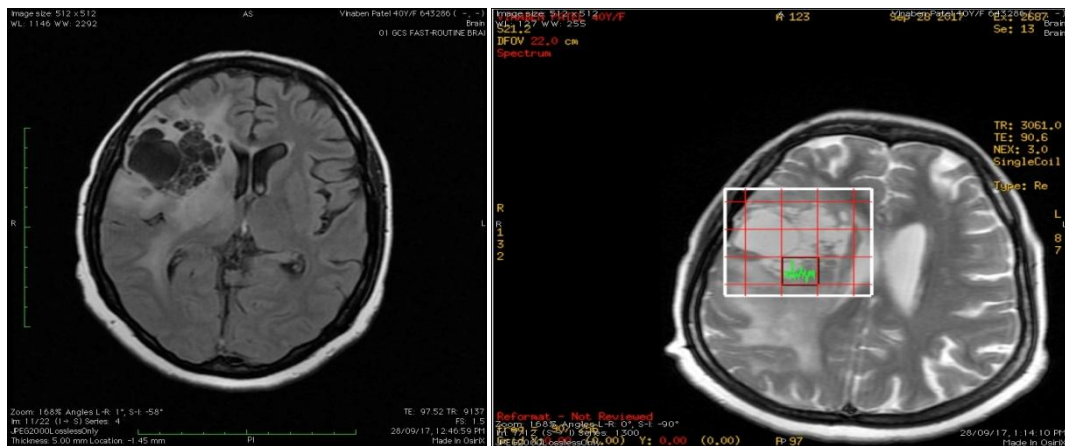
In 2 cases out of 5, with unknown primary the lesion looked like Glioblastoma multiforme. On MRS, high cho and low NAA was obtained. Perilesional elevation of Cho/Cr ratio is seen in high grade gliomas which was low here. Tumor cells are present outside the enhancing margin of gliomas, this feature is not seen in metastases(15).

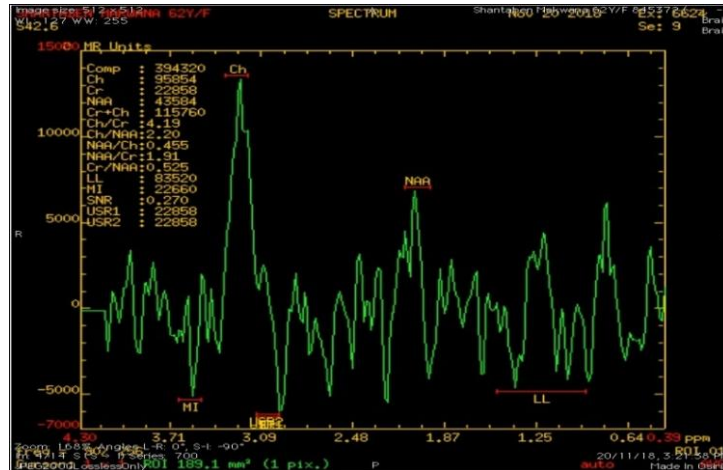
In 3 cases demonstrating a large, heterogeneous mass in the cerebral hemisphere exhibiting necrosis, hemorrhage, and ring enhancement **Glioblastoma multiforme (WHO grade IV astrocytoma) was suspected. At spectroscopy, elevation of choline, lactate and lipid and depression of NAA suggest tumor(2,15).**

In 1 case perilesional choline was raised strongly suggesting GBM.

These cases were confirmed on biopsy.

GBM is the most common primary brain malignancy, accounting for 12%–15% of all intracranial neoplasms. Glioblastoma occurs most frequently in the cerebral hemisphere of adults between 45 and 70 years of age.

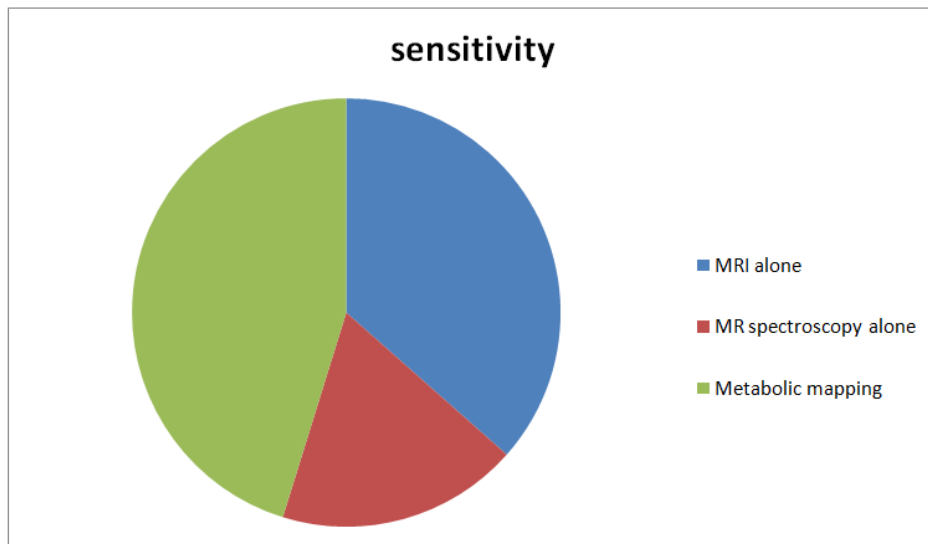




Incidence of various ring enhancing lesions.

Tuberculoma	10
Neurocysticercosis	02
Brain abscess	18
Meningioma	02
Metastases	05
Glioblastoma multiforme	03

Thus MRI alone has sensitivity of 80 % whereas spectroscopy alone has sensitivity of 40 %, but when used together for metabolic mapping gives sensitivity of 99%.



IV. Conclusion

Magnetic resonance imaging is a noninvasive, multiplanar and highly accurate method with better inherent contrast that demonstrates the lesion accurately. MRI provides an accurate assessment of the brain changes in various ring enhancing lesions, for accurate diagnosis and introduction of immediate treatment. MRI is the most sensitive modality in the characterization of intracranial ring enhancing lesions – RELs. It shows characteristic imaging findings which helps in differentiating the various RELs. Pattern of signal intensity on T2 and FLAIR, DWI and MRS help to differentiate between benign and malignant lesions. CISS 3D and MRS are to be routinely used in evaluation of ring enhancing lesions. MRI plays a critical role in patient management by suggesting the correct diagnosis based on characteristic imaging findings. MRS helps in characterization of various ring enhancing lesions. However no lesion can be diagnosed based on the findings of MRS as the sole criteria.

Both the phases of metabolic mapping i.e MRI and MR spectroscopy are efficient in characterizing ring enhancing lesions and are complementary to each other and give better results when used together than alone.

References

- [1]. Omuro AM, Leite CC, Mokhtari K, Delattre JY. Pitfalls in the diagnosis of brain tumours. *Lancet Neurol* 2006;5:937-48.
- [2]. Cunliffe CH, Fischer I, Monoky D, Law M, Revercomb C, Elrich S, et al. Intracranial lesions mimicking neoplasms. *Arch Pathol Lab Med* 2009;133:101-23.
- [3]. Zee CS, Segall HD, Boswell W, et al. MR imaging of neurocysticercosis. *J Comput Assist Tomogr* 1988;12:927-934
- [4]. Sze G, Zimmerman RD. The magnetic resonance imaging of infections and inflammatory diseases. *RadiolClin North Am* 1988;26:839-859
- [5]. Desprechins B, Stadnik T, Koerts G, et al. Use of diffusion-weighted MR imaging in differential diagnosis between intracranial necrotic tumors and cerebral abscesses. *AJNR Am J Neuroradiol* 1999;20:1252-1257.
- [6]. Kim YJ, Chang KH, Song IC, et al. Brain abscess and necrotic or cystic brain tumor: discrimination with signal intensity on diffusion-weighted MR imaging. *AJR Am J Roentgenol* 1998;171:1487-1490.
- [7]. Dev R, Gupta RK, Poptani H, et al. Role of in vivo proton magnetic resonance spectroscopy in the diagnosis and management of brain abscesses. *Neurosurgery* 1998;42:37-42
- [8]. Kim SH, Chang KH, Song IC, et al. Brain abscess and brain tumor: discrimination with in vivo H-1 MR spectroscopy. *Radiology* 1997;204:239-245.
- [9]. Poptani H, Gupta RK, Jain VK, et al. Cystic intracranial mass lesions: possible role of in vivo MR spectroscopy in its differential diagnosis. *MagnReson Imaging* 1995;13:1019-1029.
- [10]. Poptain H, Gupta RK, Roy R, et al. Characterization of intracranial mass lesions with in vivo proton MR spectroscopy. *AJNR Am J Neuroradiol* 1995;16: 1593-1603
- [11]. Grand S, Passaro G, Ziegler A, et al. Necrotic tumor versus brain abscess: importance of amino acids detected at 1H MR spectroscopy— initial results. *Radiology* 1999;213:785-793
- [12]. Potts DG, Abbott GF, von Sneidern JV. National Cancer Institute study: evaluation of computed tomography in the diagnosis of intracranial neoplasms. III. Metastatic tumors. *Radiology* 1980;136:657-664.
- [13]. Mandybur TI. Intracranial hemorrhage caused by metastatic tumors. *Neurology* 1977;27:650-655.
- [14]. Zimmerman RA, Bilaniuk LT. Computed tomography of acute intratumoral hemorrhage. *Radiology* 1980;135:355-359
- [15]. Kee-Hyun Chang, In Chan Song, Sung Hyun Kim, Moon Hee Han et al In Vivo Differentiation of Aerobic Brain Abscesses and Necrotic Glioblastomas Multiforme.

Dr.Sarita Mirchandani. "Role of MRI & MR Spectroscopy (Metabolic Mapping) In Characterization of Ring Enhancing Lesions in Brain." *IOSR Journal of Dental and Medical Sciences (IOSR-JDMS)*, vol. 18, no. 5, 2019, pp 55-60.