

## Patello Femoral Impingement -Dynamic Imaging of Knee with Musculoskeletal Ultrasound.

Dr.J.Jeyakhar<sup>1</sup>, Dr.Uma<sup>2</sup>,Dr.Premalatha<sup>3</sup>,Dr.T.Jayakumar<sup>4</sup>,Dr.C.Ramesh<sup>5</sup>

1.Post Graduate. 2,3. Senior Resident, 4. Associate Professor, 5.Director & Hod

Government Institute of Rehabilitation Medicine, Madras Medical College.

Corresponding Author: Dr.J.Jeyakhar

**Aim:**To Investigate & Visualize Soft Tissue Impingement At Patellofemoral Joint Using Real Time Dynamic Musculoskeletal Ultrasound.

To Identify The Cause Of Pain In Anterior Knee Joint And To Determine Patellofemoral Impingement As In Rotator Cuff Impingement.

**Keywords:** Patellofemoral Impingement, Patellofemoral Pain, Anterior Knee Pain, Quadriceps Tendon Impingement, Quadriceps Fat Pad & Bursa Impingement,Ultrasound Of Knee, Musculoskeletal Ultrasound.

Date of Submission: 27-03-2019

Date of acceptance: 12-04-2019

### I. Introduction

The Incidence Of “Anterior Knee Pain” Is High And Is Located At 22/1,000 Persons Per Year. Women Are Affected About More Than Twice As Often As Men. Pain At The Front Of The Knee Usually Comes From The Patellofemoral Joint, Which Is Quite Separate From The Tibio Femoral Joint. This Joint Is Stressed When The Knee Is Flexed Under Load, As When Squatting Or Descending Stairs, But There Are Many Other Causes.

The Mechanics Of The Joint Means That It Takes Up To Seven Times The Weight Of The Body When Loaded In Flexion And It Is Therefore Exposed To Enormous Stresses. The Pain Is Felt Around The Knee Cap And Patients Usually Indicate The Site Of The Pain By Rubbing The Palm Of The Hand Over The Knee Cap. The Pain Can Be Serious Enough To Curtail Sports Or Even Make It Difficult To Climb Stairs. The Articular Surface May Be Abnormal But Pain Can Also Arise From Structures Around The Joint.

Patellofemoral Pathology Causes Pain On Bending More Than 30 Degree Due To

Increased Load On Patellofemoral Joint. Difficulty From Getting Up After Sitting For Long Time “Cinema Sign” Or Clicking Sound Without Pain Is Common.

The Causes For Anterior Knee Pain Are Multifactorial. Enlisted Below Are The Reason For Anterior Knee Joint Pain

- Referred Pain From Lumbar Spine
- Referred Pain From Hip
- Patellofemoral Disorders:
  - Patellar Instability
  - Patellofemoral Overload
  - Osteochondral Injury
  - Patellofemoral Osteoarthritis
- Knee Joint Disorders:
  - Osteochondritis Dissecans
  - Loose Body In The Joint
  - Synovial Chondromatosis
  - Plica Syndrome
- Periarticular Disorders:
  - Patellar Tendinitis
  - Patellar Ligament Strain
  - Bursitis
  - Osgood–Schlatter’s Disease

In Government Institute Of Rehabilitation Medicine We Identified Patients With Anterior Knee Joint Pain With Patellofemoral Impingement Due To Osteophytes In The Femur And Patella.

## II. Materials & Methods

- i. **Study Design :** Cross Sectional
- ii. **Sample Size:** 108 Patients With Anterior Knee Joint Pain.
- iii. **Materials Used :**
  - Clinical Examination,
  - Goniometer,
  - X Ray Knee Ap/Lateral,
  - Musculoskeletal Ultrasound (High Frequency Linear Transducer )
- iv. **Participants :** Patients Attending Out Patient Department With Anterior Knee Pain In Government Institute Of Rehabilitation Medicine In The Month Of November 2018 - January 2019

### Exclusion Criteria :

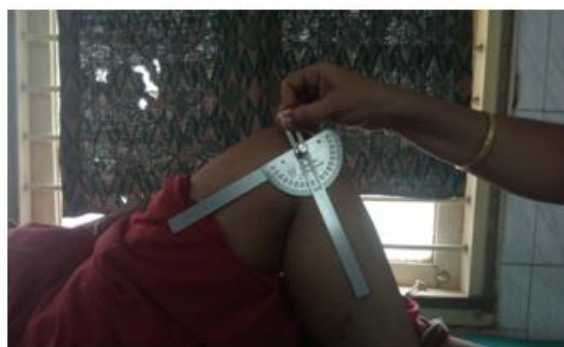- Referred Pain From The Lumbar Spine And Hip Joint
- Severe Lower Limb Length Discrepancy
- Recent Trauma History Of Knee
- Fracture (Femur, Patella, Tibia)
- Tendon Injuries
- Ligament Injuries (Acl, Pcl, Mcl)
- Knee Effusion
- Hoffa's Syndrome

**Inclusion Criteria :** All Anterior Knee Pain Excluding The Patients With Exclusion Criteria

### Examination:

Out Of The 108 Patients Presented With Anterior Knee Pain, Lumbo Sacral Spine, Both Hip And Knee Joint Examination Were Done. On Examination And Applying The Exclusion Criteria , 37 Patients Were Not Included In The Study.

71 Patients Were Clinically Diagnosed As Patellofemoral Syndrome. In All These 71 Patients Knee Rom Was Measured Using Universal Goniometer. 53 Out Of 71 Patients Had Painful Range Of Motion. Out Of 53 Patients 17 Of Them Had The Features Suggestive Of Knee Painful Arc Viz Pain Experienced At Terminal Rom Of Knee Flexion(Cam Type Femoral Osteophytes) , Terminal Rom Of Knee Extension (Pincer Type Patellar Osteophytes) & Pain Experienced At Terminal Rom Of Both Knee Flexion & Knee Extension (Mixed Type Both Cam & Pincer).



**Measuring Range of Movements with Universal Goniometer**

X Ray Of The Knee Joint Were Taken For All The 53 Patients On The Symptomatic Side. X Ray Revealed The Following Findings. 26 Patients Had Consistent Xray Findings Suggestive Of Cam/ Pincer / Mixed Type Osteophytes.

Patients With Pincer Type Osteophytes In Patella - 14 Patients.

Patients With Cam Type Osteophytes In Femoral Condyle - 9 Patients.

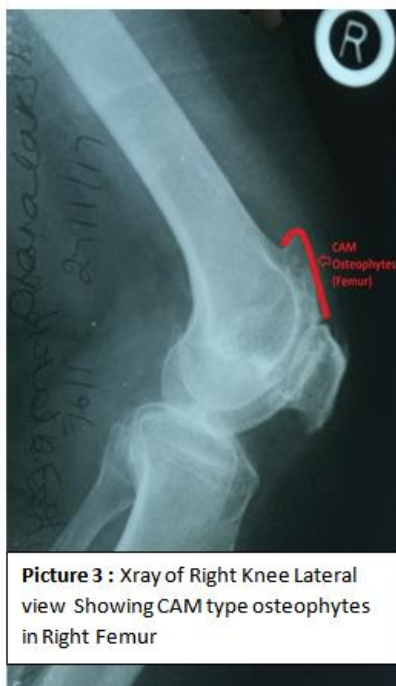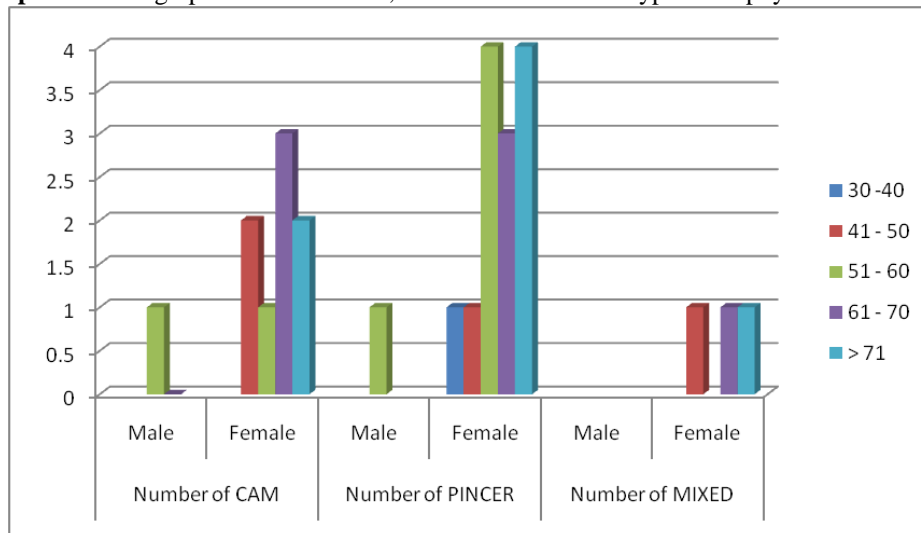
Patients With Mixed Type Osteophytes In Femoral Condyle And Patella - 3 Patients.

**Table 1 : Demographic Data Of Types Of Osteophytes In Knee Joint**

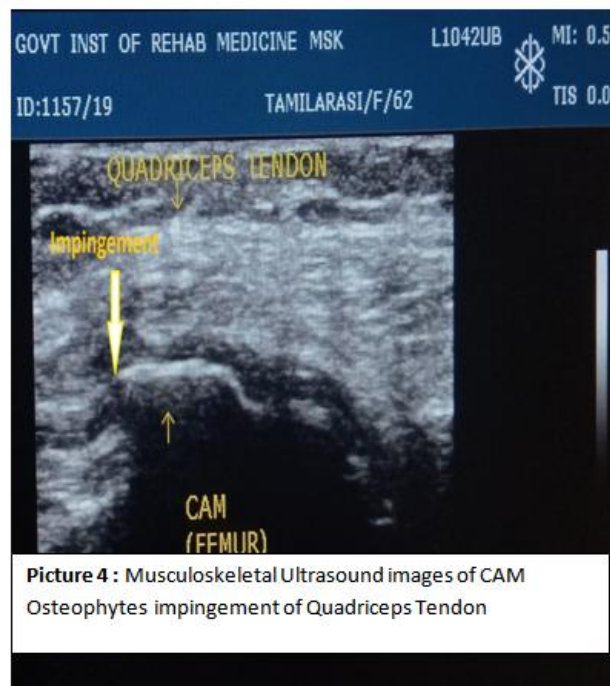
Serial Number	Age Group	Number Of Patients		Number Of Cam		Number Of Pincer		Number Of Mixed	
		Male	Female	Male	Female	Male	Female	Male	Female
1	30 -40	8	5	-	-	-	1	-	-
2	41 - 50	5	27	-	2	-	1	-	1
3	51 - 60	4	32	1	1	1	4	-	-
4	61 - 70	4	17	-	3	-	3	-	1
5	> 71	2	4	-	2	-	4	-	1

All The 26 Patients Underwent Musculoskeletal Ultrasound Of The Knee Joint. For All The 26 Patients Irrespective Of The Symptomatic Side, Both Knee Joint Ultrasound Was Done With B Mode High Frequency Linear Transducer Probe In Musculoskeletal Ultrasound Setting. Ultrasound Of Knee Joint Done With Dynamic Mobilisation Of Knee Joint From Neutral To Flexion And From Full Flexion To Complete Extension. Osteophytes Were Identified And During The Dynamic Mobilisation The Impingement Of Quadriceps Tendon By Cam Osteophytes In Femur During Flexion Of Knee, Quadriceps Fat Pads By Pincer Osteophytes In Patella During Extension Of Knee And In Mixed Type Both Structures Were Impinged.

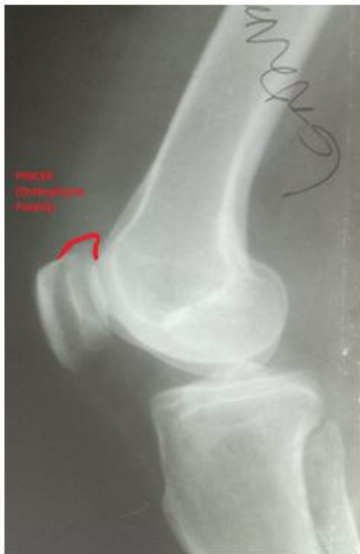**Graph 1 : Demographic data of CAM , PINCER & MIXED type Osteophytes in Knee Joint**



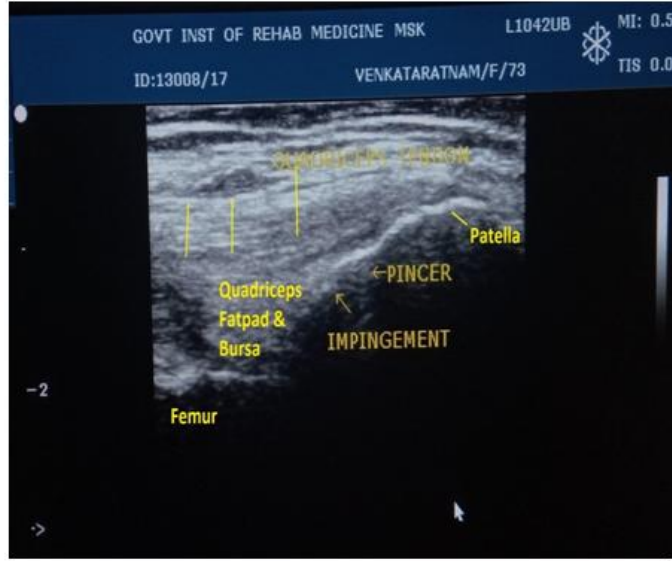
**Picture 3 : Xray of Right Knee Lateral view Showing CAM type osteophytes in Right Femur**



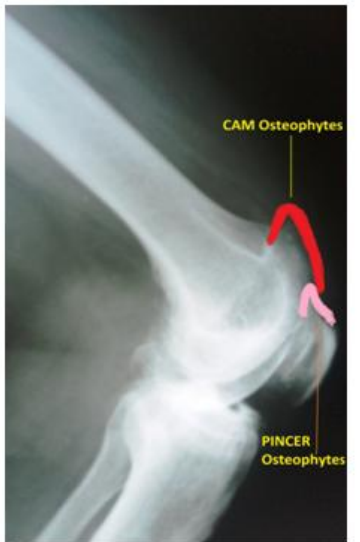**Picture 4 : Musculoskeletal Ultrasound images of CAM Osteophytes impingement of Quadriceps Tendon**



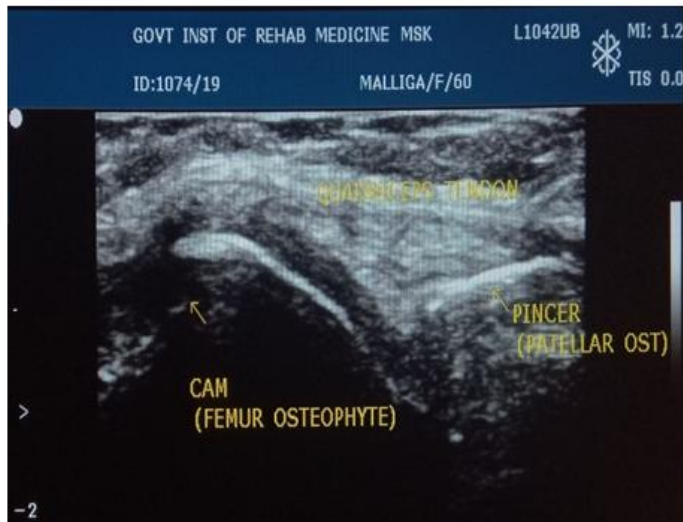**Picture 5 :** Xray of Right Knee Lateral view Showing Pincer type osteophytes in Patella



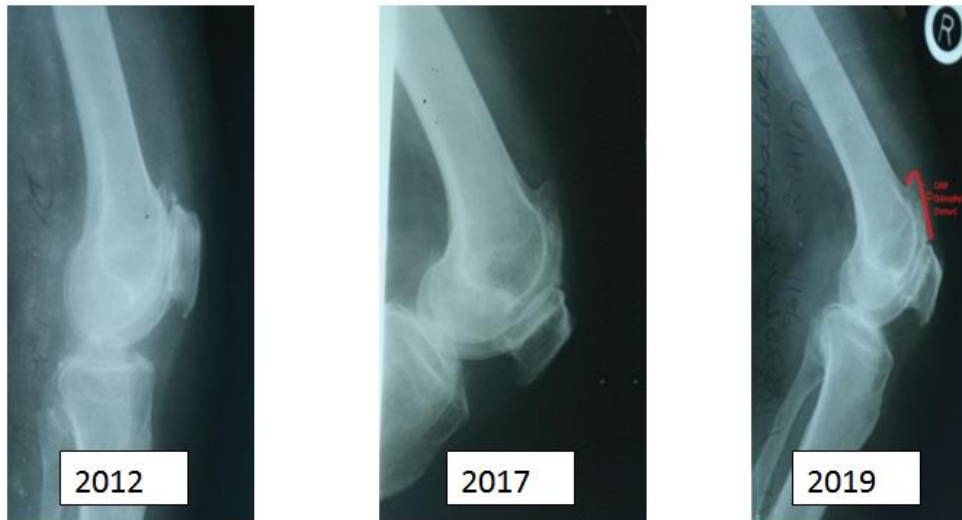**Picture 6 :** Musculoskeletal Ultrasound images of Pincer Osteophytes impingement of Quadriceps Fat pads



**Picture 7 :** Xray of Right Knee Lateral view Showing MIXED type osteophytes in Patella



**Picture 8 :** Musculoskeletal Ultrasound images of Mixed Osteophytes impingement of Quadriceps Tendon & Quadriceps Fat pads



**X Ray Right Knee Lateral view Of the same patient taken during various years**

One Of The Patient Had Old Xray Of Her Knee Joint Which Was Taken 7 Years Before Which Showed The Early Cam Osteophytic Changes In The Femur. The Degree Of Rom At Which The Pain Starts Depend On The Size Of The Cam & Pincer Osteophytes. The Size Of The Osteophytes Is Inversely Proportional To The Degree At Which The Patient Feels Pain.

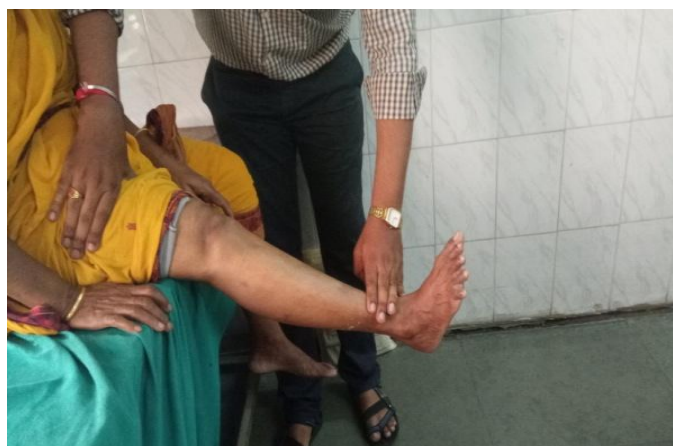**Discussion :**

During The Dynamic Musculoskeletal Ultrasound, It Was Noted That Even The Patients With Early Cam Or Pincer Osteophytic Changes In Xray, Who Does Not Show Classical Knee Painful Arc While Measuring With Universal Goniometer , Pain Was Reproduced During The Sono Palpation (Probe Tenderness)With The Ultrasound Probe .

Alternatively Pain Can Be Reproduced In These Patients On Clinical Examination Done By Giving Pressure With Thumb Over The Midcondylar Region Of Anterior Aspect Of Femur In Cam Type Osteophyte (**QTCompression test**)And Pressure Over Patella In The Pincer Type Osteophyte(**Patellar Compression Test**).

**III. Results**

Dynamic Us Examination Revealed Quadriceps Fat Pads And Bursa Impingement Underneath Prominent Superior Patellar Osteophytes (Pincer Type) Reproducing Pain At The Terminal Range Of Motion Of Extension In 8 Patients. Quadriceps Tendon (Qt) Impingement Over Prominent Anterior Osteophyte Arising From Femoral Condyle (Cam Type) Reproducing Pain During The End Range Of Flexion In 6 Patients And Mixed Impingement Of Qt, Fat Pads And Bursa Between Femoral And Patellar Osteophytes (Mixed Type) With Pain In Both End Range Of Flexion & End Range Of Extension In 3 Patients.



#### IV. Conclusion

- To Our Knowledge This Is The First Study To Use Dynamic Us And Goniometry To Diagnose And Coin The Term Patellofemoral Impingement Syndrome, Though Rotator Cuff Impingement Of The Shoulder Is Described In Literature.
- Dynamic Ultrasound Is A Best Way To Identify The Impingement As It Allows To Visualize The Real Time Live Movement Of The Soft Tissues.
- This Technique Can Help Understand Mechanism And Type Of Soft Tissue Impingement To Modify Exercise Prescription Using Pain Free Arc Exercise And Improve Rehabilitation Outcome.
- Even If Patient Has Complaints In One Leg And The Xray Of The Affected Side Knee Shows Cam Or Pincer Type, Contralateral Side Has The Similar Xray Changes.(Needed Larger Sample To Confirm)
- Operative Osteochondroplasty Can Be Considered For Painfree Arc And There By Improving The Quality Of Life.

#### References

- [1]. **Knee Painful Arc, Imaging By Dynamic Sonography: A Novel Technique** Muhammad Dughbaj, 2diaa Shehab, 3salem Alkandari, 4levent Ozcakar M. Dughbaj Physical Medicine And Rehabilitation Hospital, Physical Medicine And Rehabilitation Department, Kuwait, Kuwait. Oral Abstracts / Annals Of Physical And Rehabilitation Medicine 61s (2018) E1–E102
- [2]. **Diagnostic Accuracy And Association To Disability Of Clinical Test Findings Associated With Patellofemoral Pain Syndrome** Chad Cook, Eric Hegedus, Richard Hawkins, Field Scovell, Doug Wyland
- [3]. **Patellar Taping, Patellofemoral Pain Syndrome, Lower Extremity Kinematics, And Dynamic Postural Control** Naoko Aminaka, Ms, Atc; Phillip A. Gribble, Phd, Atc The University Of Toledo, Toledo, Oh
- [4]. **A Prospective Investigation Of Biomechanical Risk Factors For Patellofemoral Pain Syndrome. The Joint Undertaking To Monitor And Prevent Acl Injury (Jump-Acl) Cohort** Michelle C. Boling,\*†‡ Phd, Atc, Darin A. Padua,† Phd, Atc, Stephen W. Marshall,† Phd, Kevin Guskiewicz,† Phd, Atc, Scott Pyne,§ Md, And Anthony Beutler,|| Md From The †University Of North Carolina At Chapel Hill, Chapel Hill, North Carolina, The ‡University Of North Florida, Jacksonville, Florida, The §United States Naval Academy, Annapolis, Maryland, And The ||Uniformed Services University Of The Health Sciences, Bethesda, Maryland
- [5]. **The Accuracy Of Diagnostic Ultrasound Imaging For Musculoskeletal Soft Tissue Pathology Of The Extremities: A Comprehensive Review Of The Literature** Rogan E A Henderson<sup>1,4\*</sup>, Bruce F. Walker<sup>2</sup> And Kenneth J. Young<sup>3</sup>

Dr.J.Jeyakhar. “Patello Femoral Impingement -Dynamic Imaging Of Knee With Musculoskeletal Ultrasound..” IOSR Journal of Dental and Medical Sciences (IOSR-JDMS), vol. 18, no. 4, 2019, pp 51-56.