

Endoscopic Suprasellar Arachnoid Cysts Fenestration Series of 22 Cases and Literature Review

Bouaita.K¹, Benmamar.T¹

¹(Cherchell Hospital, Neurosurgery department, Tipaza, Algeria)
Corresponding Author: Bouaita.K

Abstract: Introduction: Suprasellar arachnoid cysts are benign developmental collections of CSF and constitute approximately 9% of all pediatric intracranial arachnoid cysts.

Objectif: The aim of this study is to demonstrate the feasibility and interest of the endoscopy in the treatment of suprasellar arachnoid cysts.

Materials and methods: We report our experience with endoscopic management in 22 patients with suprasellar arachnoid cyst treated with endoscopic fenestration during the period ranged from 2009 to 2018 in our institution.

Results: The average age of the patients at the time of presentation was 24 months. There was a male predominance. Clinical manifestations include macrocephaly (100%), visual problems (41%) and rarely Bobble-head doll syndrome (9%). Preoperative CT and MRI scans were performed in all cases. All the patients were treated by endoscopic fenestration of the cysts. No intraoperative complications were encountered, no mortality occurred. Postoperative CSF leak without meningitis occurred in three cases (14%), treated by lumbar puncture, with good outcomes. Patients with macrocephaly, visual disturbances and head bobbling improved after surgery.

Conclusion: Endoscopic management of suprasellar arachnoid cysts is a safe and effective modality. Our results compare favorably to a previously reported case series.

Keywords: Arachnoid cyst, ventriculostomy, head bobbling, hydrocephalus

Date of Submission: 25-03-2019

Date of acceptance: 09-04-2019

I. Introduction

Suprasellar arachnoid cysts constitute 9-21% of all pediatric intracranial arachnoid cysts. [1] Arachnoid cysts are found to occur more often in male than female subjects. [2] They are known to be associated with hydrocephalus and to cause visual and endocrine dysfunction due to their anatomical locations, which may require specific management. [8] Their etiology is thought to arise from an abnormality during embryologic development, although other mechanisms have been reported. [3] Treatment options include surgical drainage via craniotomy, treatment with shunt insertion, and recently endoscopic fenestration. [13]

II. Materials And Methods

This is a retrospective study of the data collected from 22 patients that received endoscopic treatment for suprasellar arachnoid cysts in our neurosurgery department from 2009 to 2018. The average age of the patients at the time of presentation was 24 months. Age of the patients ranged from 13 to 47 months. There was a male predominance (19 patients).

III. Results

Clinical manifestations: All patients had progressive macrocephaly. Visual decline was diagnosed in nine patients (41%). We reported two cases of head bobbling (9%). No patient presented with precocious puberty or any endocrine dysfunction.

Neuroradiological assessment: Preoperative computed tomography (CT) and magnetic resonance imaging (MRI) scans were performed in all the cases. Hydrocephalus was demonstrated on preoperative MRI in all the patients. These lesions are often described as cystic masses with an MRI signal intensity similar to CSF on all sequences, such as T1-weighted, T2-weighted, and diffusion-weighted images, with vertical deflection of the optic chiasm/tracts, upward displacement of the anterior mesencephalon and mammillary bodies, and effacement of the ventral surface of the upper brainstem (figure 1).

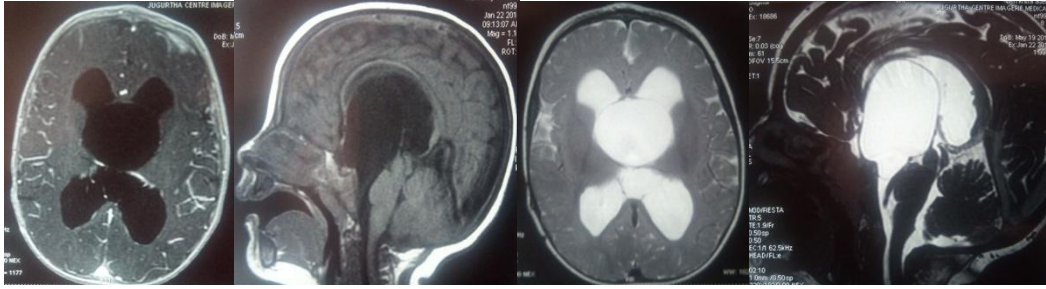


Fig 1:A 3-year-old male presented with worsening headaches and bobble head doll syndrom. MRI axial, sagittal (T1, T2) images show a suprasellar arachnoid cyst projecting into the third ventricle with hydrocephaly.

Surgical treatment: All patients underwent cyst fenestration procedures, with ventriculocysternostomy. The main indications for surgical treatment include increased intracranial pressure due to obstruction of CSF pathways, increased head circumference, visual impairment, and progressive cyst enlargement. The endoscopic procedure included lateral ventricle puncture by precoronal burr hole and superior and inferior wall of the cyst was communicated with the lateral ventricle and the interpeduncular cistern respectively (figure 2).

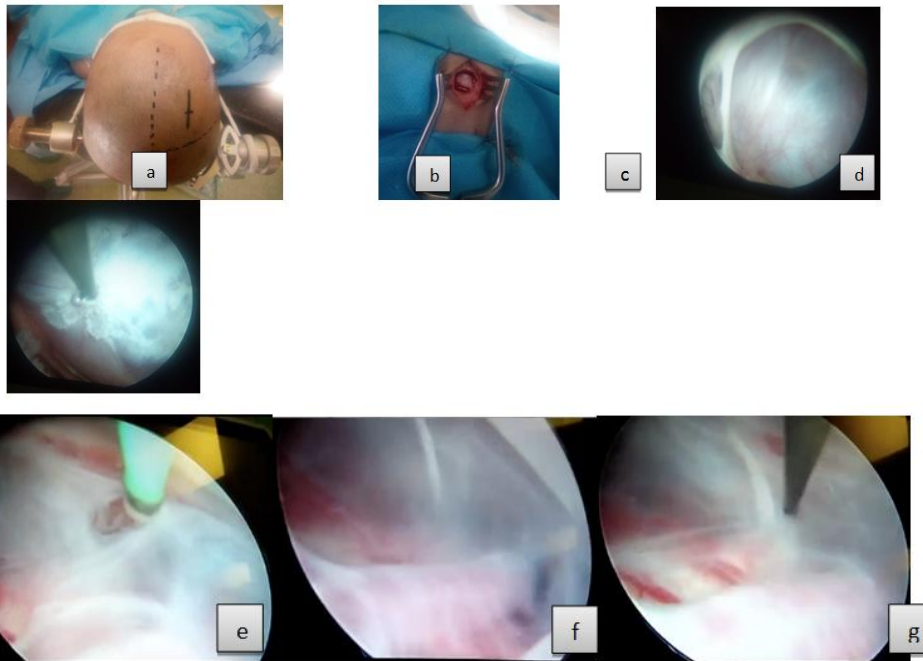


Fig 2: Intraoperative images demonstrating: a,b) position of the head and placement of the burr hole c,d) superior membrane of the cyst and her coagulation e) fenestration of the cyst f) visualization of the basilar artery and the sixth cranial nerve g) creating a small pore at the Liliquist membrane surrounding the basilar artery to establish a communication between the cyst and the prepontine cistern.

Outcome: All patients had postoperative imaging and clinical visits within 3 months of the intervention and at yearly follow-up visits. The total follow-up period was, on average, 34 months (14-56 months). In our series, no intraoperative complications were encountered, no mortality occurred. Postoperative CSF leak without meningitis occurred in three cases (14%), treated by lumbar puncture, with good outcomes. A complete resolution of preoperative head circumference growth, hydrocephalus, visual disturbances, head bobbling was observed in all cases. No patients experienced any new focal neurological deficits postoperatively. Postoperative MRI showed significant reduction in cyst volume in all patients (figure 3).

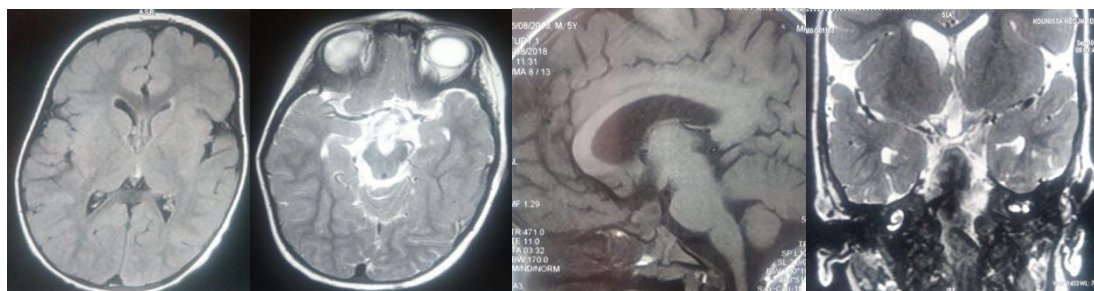


Fig 3: Axial, sagittal and coronal MRI scan after 4 months of surgery. The size of the cyst decreased and hydrocephaly improved after the procedure.

IV. Discussion

Suprasellar arachnoid cysts occur in 9-21% of all pediatric intracranial arachnoid cysts.[1,2]The etiology and pathophysiology of arachnoid cysts remain debatable and many theories have been suggested as to their formation. In general, arachnoid cysts are seen as developmental abnormalities, occurring during embryonic development where splitting or duplication of the primary arachnoid membrane leads to intracranial fluid collections. In addition, acquired cysts can occur secondary to trauma, hemorrhage and inflammation.[3,4]They generally expand from the prepontine space, causing elevation of the third ventricle, with an upward and forward displacement of the pituitary stalk and optic chiasm.They can also cause superior and posterior distortion of the mammillary bodies. As the cyst size increases, occlusion of the third ventricle and blockage of the cerebral aqueduct may occur, and lead to obstructive hydrocephalus. Posterior displacement of the brainstem with subsequent dysfunction may also occur. [5]Most patients with suprasellar arachnoid cysts at diagnosis are younger than 5 years old. In infants, the main presenting clinical symptoms were macrocrania and motor deficits. In children and adolescents, the main presenting symptoms were elevated ICP, endocrine dysfunction, and reduced visual field or acuity, and bobble head doll syndrom.[6,7,8,9]The diagnosis is best made by MRI. [10]The therapeutic goals in cases of suprasellar arachnoid cysts are to normalise CSF flow by establishing and maintaining communication between cyst cavity and the intraventricular or subarachnoid space. Surgical indications include signs of elevated ICP, motor deficits, head bobbing, and visual impairment.[11,12]Numerous treatments have been described. A direct approach to the cyst for microsurgical excision or fenestration is rather invasive because of the deep location of these cysts. [21]The common problems with any shunting procedure, such as shunt malfunction, infection, and shunt dependency, are also well known, which can be avoided by transventricular endoscopic technique performed in our cases. Moreover, the success rate of the ventriculoperitoneal shunt as a definitive treatment of suprasellar arachnoid cysts is reported to be only 10%.[13,20]Advances in endoscopy have raised endoscopic fenestration to the initial surgical procedure in the management of suprasellar arachnoid cysts with hydrocephalus at the present time, and the procedure has been demonstrated to be safe and effective in children.[23]in the literature, success rates have ranged from 75-90.9%.[15,16,18]In previous studies transient cranial nerve injury occurred in 2.3%, [18,22]we had none cases of cranial nerve injuries in our series.The study of Özek et al.[16] shows a complete resolution of preoperative head circumference growth, hydrocephalus, and visual disturbances in all cases,as observed in our series.Endoscopic ventriculocystostomy has been shown to have optimal CSF dynamic outcomes. Long-term analysis of CSF dynamics showed that, in long-term follow-up, the perforation at the bottom of the cysts remained patent and functional. [14]All patients demonstrated a decrease in cyst size on postoperative imaging in our series, like seen in previous studies.[18]We agree with the review from Maher and Goumnerova[18] and Yadav et al.[19] who concluded that endoscopic ventriculocystocisternostomy is more effective than ventriculocystostomy.In the same way, Crimmins et al. [22] found that in large cysts associated with aqueduct obstruction, ventriculocystostomy was only effective in 25% of cases but ventriculocystocisternostomy was effective in every case.

V. Conclusion

Suprasellar cysts are heterogeneous entities.Considering numerous disadvantages associated with various treatment procedures, endoscopic fenestration is a minimally invasive technique, which is a safe, effective and durable alternative treatment for suprasellar arachnoid cyst.

References

- [1]. Hoffman HJ, Hendrick EB, Humphreys RP, Armstrong EA: Investigation and management of suprasellar arachnoid cysts. *J Neurosurg* 57:597-602, 1982
- [2]. Al-Holou WN, Terman S, Kilburg C, Garton HJ, Muraszko KM, Maher CO: Prevalence and natural history of arachnoid cysts in adults. *J Neurosurg* 118:222-231, 2013
- [3]. Miyajima M, Arai H, Okuda O, Hishii M, Nakanishi H, Sato K. Possible origin of suprasellar arachnoid cysts: neuroimaging and neurosurgical observations in nine cases. *J Neurosurg*. 2000;93(1):62-67.
- [4]. Froelich SC, Abdel Aziz KM, Cohen PD, van Loveren HR, Keller JT. Microsurgical and endoscopic anatomy of Lilliequist's membrane: a complex and variable structure of the basal cisterns. *Neurosurgery*. 2008;63(1 suppl 1): ONS1-ONS8; discussion ONS8-ONS9.
- [5]. Lyu J. Possible origins of suprasellar arachnoid cysts based on anatomical considerations. *World Neurosurg*. 2014;82(3-4):e570-e573.
- [6]. Onteddo J, Reddy, Jamkhana Abdul Gafoor, Balla Suresh, and P. Obuleswar Prasad. Bobble head doll syndrome: A rare case report. *J Pediatr Neurosci*. 2014 May-Aug; 9(2): 175-177.
- [7]. Shighakolli Ramesh, Subodh Raju. Suprasellar arachnoid cyst presenting with bobble-head doll syndrome: Report of three cases. *J Pediatr Neurosci*. 2015 Jan-Mar; 10(1): 18-21.
- [8]. Gul SB, Wang XS, Zong XY, et al. Suprasellar cysts: clinical presentation, surgical indications, and optimal surgical treatment. *BMC Neurol* 2011;11:52.
- [9]. Adan L, Bussi eres L, Dinand V, Zerah M, Pierre-Kahn A, Brauner R: Growth, puberty and hypothalamic-pituitary function in children with suprasellar arachnoid cyst. *Eur JPediatr* 159:348-355, 2000
- [10]. Mohamed Badaoui, Soufiane Belabbes, Abdellatif Darbi, Abdennasser El Kharras. Kyste arachnoıdien intra et supra sellaire: apport de l'IRM. *Pan African Medical Journal*. 2015
- [11]. Mattox A, Choi JD, Leith-Gray L, Grant GA, Adamson DC. Guidelines for the management of obstructive hydrocephalus from suprasellar-prepontine arachnoid cysts using endoscopic third ventriculocystocisternostomy. *Surg Innov*. 2010;17 (3):206-216.
- [12]. M. Memet  zek, Kamran Urgan. Neuroendoscopic Management of Suprasellar Arachnoid Cysts. *World Neurosurg*. (2013).
- [13]. Gui SB, Wang XS, Zong XY, Zhang YZ, Li CZ. Suprasellar cysts: clinical presentation, surgical indications, and optimal surgical treatment. *BMC Neurol*. 2011;11:52.
- [14]. Elias Rizk, Joshua J. Chern, Christine Tagayun, R. Shane Tubbs, Todd Hankinson, Curtis Rozzelle, W. Jerry Oakes, Jeffrey P. Blount, John C. Wellons. Institutional experience of endoscopic suprasellar arachnoid cyst fenestration. *Childs Nerv Syst* (2013) 29:1345-1347.
- [15]. Hideki Ogiwara, Nobu Hito Morota, Masa Hiro Jko, Kengo Hirota. Endoscopic fenestrations for suprasellar arachnoid cysts. *J Neurosurg Pediatrics* 8:484-488, 2011.
- [16]. Ozek MM, Urgan K. Neuroendoscopic management of suprasellar arachnoid cysts. *World Neurosurg*. 2013;79(2 suppl):S19.e13-S19.e18.
- [17]. Ogiwara H, Morota N, Joko M, Hirota K. Endoscopic fenestrations for suprasellar arachnoid cysts. *J Neurosurg Pediatr*. 2011;8(5):484-488.
- [18]. Maher CO, Goumnerova L. The effectiveness of ventriculocystocisternostomy for suprasellar arachnoid cysts. *J Neurosurg Pediatr*. 2011;7(1):64-72.
- [19]. Y. R. Yadav, Vijay Parihar, Mallika Sinha, Nishin Jain. Endoscopic treatment of the suprasellar arachnoid cyst. *Neurology India*, Mar-Apr 2010, Vol 58, Issue 2
- [20]. Martınez-Lage JF, Ruız-Espejo AM, Almagro MJ, Alfaro R, Felipe Murcia M, L pez-Guerrero AL. CSF over drainage in shunted intracranial arachnoid cysts: A series and review. *Childs Nerv Syst* 2009;25:1061-9.
- [21]. Gangemi M, Colella G, Magro F, Maiuri F. Suprasellar arachnoid cysts: Endoscopy versus microsurgical cyst excision and shunting. *Br J Neurosurg* 2007;21:276-80.
- [22]. Crimmins DW, Pierre-Kahn A, Sainte-Rose C, Zerah M: Treatment of suprasellar cysts and patient outcome. *J Neurosurg* 105 (2 Suppl):107-114, 2006
- [23]. Wang JC, Heier L, Souweidane MM: Advances in the endoscopic management of suprasellar arachnoid cysts in children. *J Neurosurg* 100 (5 Suppl Pediatrics):418-426, 2004

Bouaita.K. " Endoscopic Suprasellar Arachnoid Cysts Fenestration Series of 22 Cases and Literature Review." *IOSR Journal of Dental and Medical Sciences (IOSR-JDMS)*, vol. 18, no. 4, 2019, pp 50-53.