

Extranasopharyngeal Angiofibroma of Nasal Septum-A Rare Case Report

Dr.B.Shobana¹, Dr.R.Narmadha², Dr .A.P.Rajesh Nataraj³, Prof.Dr.Bharathi Vidhya Jayanthi⁴

(1.Post graduate,Institute of Pathology .Madras Medical College)

(2.Assistant Professor , Institute of Pathology .Madras Medical College)

(3.Assistant Professor , Institute of Pathology .Madras Medical College)

(4.Director ,Institute of Pathology.Madras Medical College)

Corresponding author: R.Narmadha

Abstract: Juvenile nasopharyngeal angiofibroma(JNA) is a benign ,richly vascularised mesenchymal neoplasm. Most commonly occurs in adolescent males. It originates mostly from the posterolateral wall of the nasopharynx and extents into the surrounding tissue. Extranasopharyngeal angiofibroma(ENA) is an uncommon tumor with only 65 cases being reported in world literature, in which maxillary sinus is the common site and nasal septum is found to be an extremely rare site. Here we report a case of 15 year old male patient with extranasopharyngeal angiofibroma arising from nasal septum. This case is being published for its rarity and unusual site of origin.

Key Words: extranasopharyngeal angiofibroma(ENA), nasal septum ,unusual site.

Date of Submission: 20-03-2019

Date of acceptance: 06-04-2019

I. Introduction

Juvenile nasopharyngeal angiofibroma is a benign neoplasm, rich in vascular network with fibrous stroma. It is a locally destructive tumour. It represents <1% of all nasopharyngeal tumours and 0.5% of all head and neck neoplasms and predominantly occurs in adolescent males (1). Out of 704 cases of angiofibroma reviewed by de Vincentiis and Pinelli; only 13 cases occurred outside the nasopharynx, suggesting that extranasopharyngeal angiofibroma is a rare entity (2). A recent review of the literature reported a total of 65 patients with atypical localizations of nasopharyngeal angiofibromas, the maxillary sinus being the most commonly involved site(3) .Nasal septum is an extremely unusual site and to the best of our knowledge less than 10 cases have been reported(3-5).

II. Case Report

A 15year old male presented with history of nasal obstruction and bleeding from nose on and off for past 2 months. On anterior rhinoscopy, a fleshy mass was seen filling the whole of right nasal cavity and deviation of nasal septum to the left. MRI –PNS revealed a polypoidal mass measuring 3.2x1.2x3cms visualised in the floor of the anterior nasal cavity on the right side (FIG:1) with bilateral ethmoido - maxillary sinusitis.

Patient underwent excision of mass, peroperatively the mass was found to be arising from the nasal septum and mass was removed in toto.

We received single gray tan globular mass measuring 2.5x1.5x0.5cm (FIG:2)

Microscopic examination revealed respiratory epithelium with focal squamous metaplasia and a neoplasm composed of varying sized blood vessels lined by flattened epithelium with irregular smooth muscle coat and fibrous stroma composed of spindle and stellate shaped cells.(FIG:3,4,5)

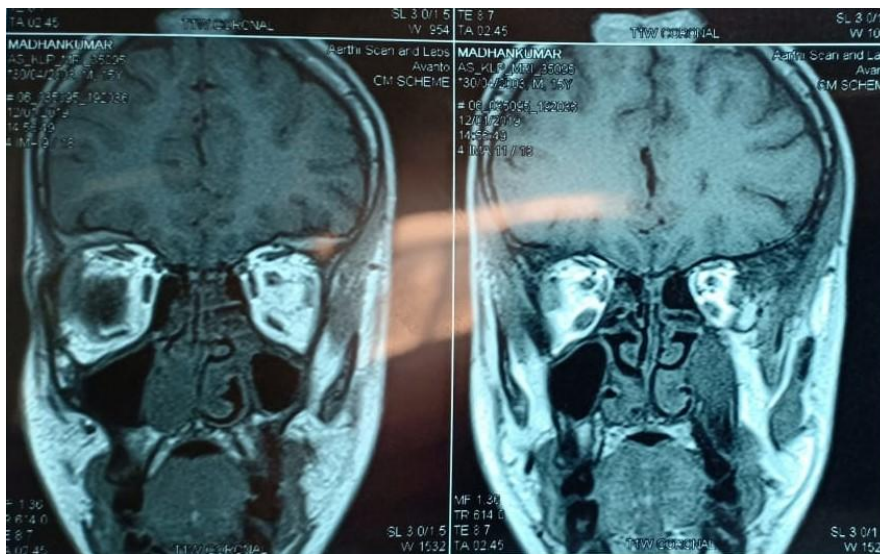


FIG 1: MRI-PNS shows mass in the right nasal cavity

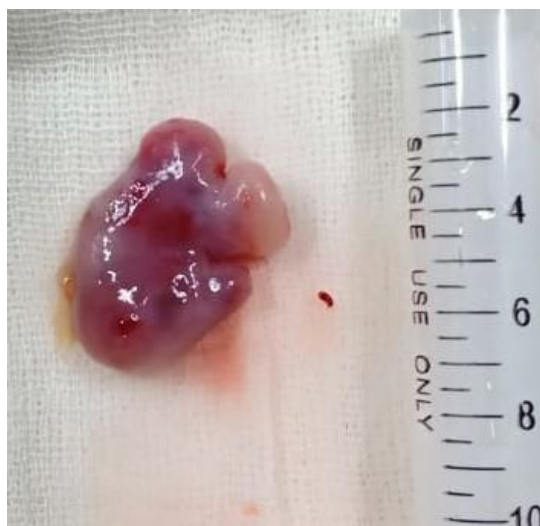

FIG 2: Globular vascular mass

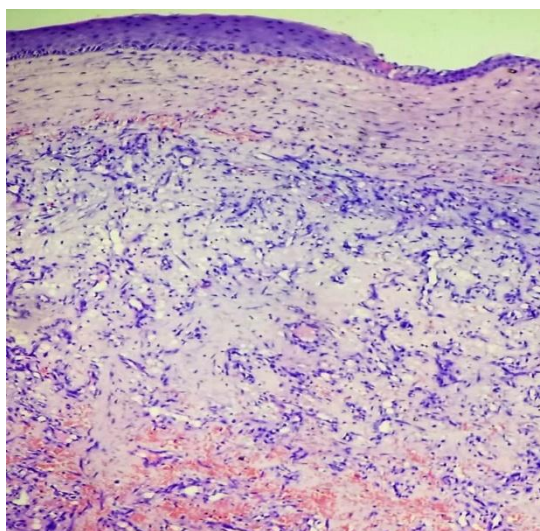


FIG 3: H&E: 10x-shows respiratory epithelium with squamous metaplasia and a neoplasm composed predominantly of blood vessels.

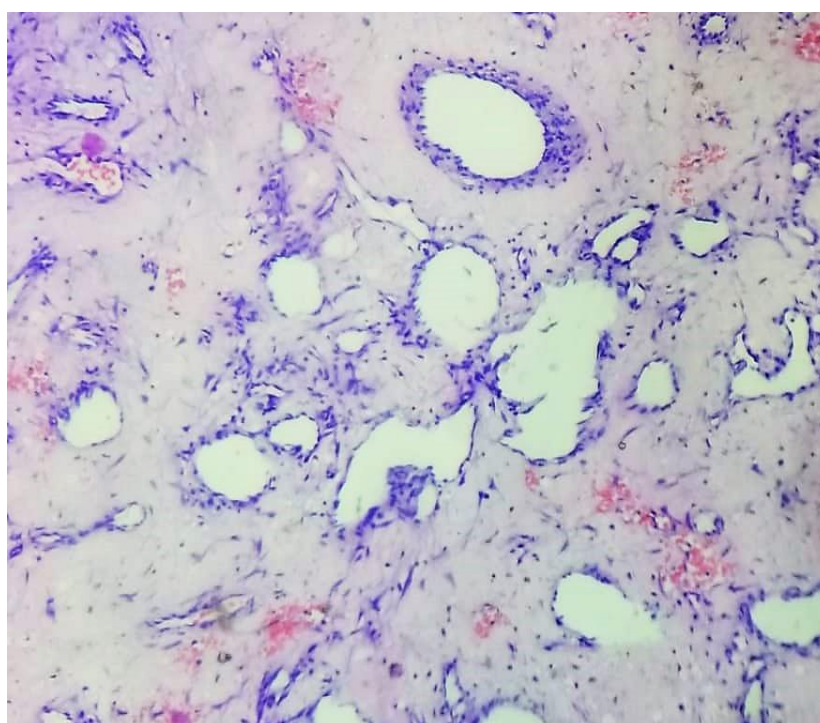
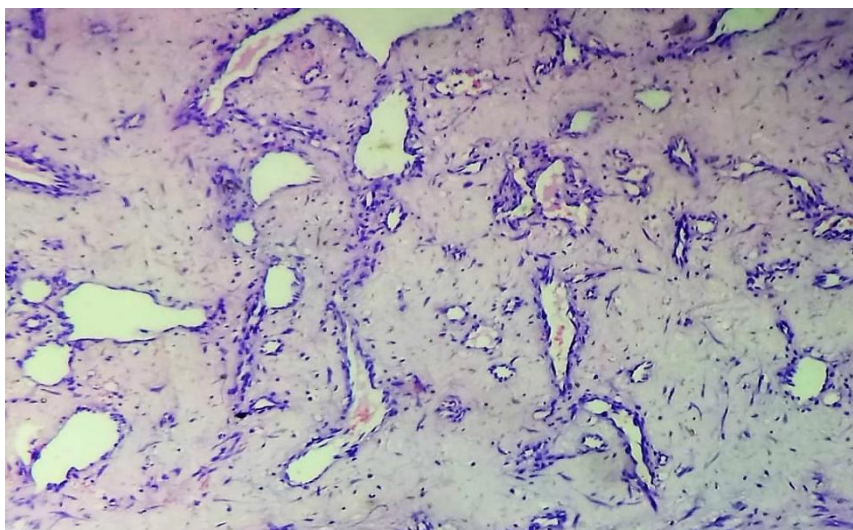


FIG 4 and 5:H&E:40X-shows varying sized blood vessels with incomplete smooth muscle coat in a fibrous stroma

III. Discussion

Extranasopharyngeal angiofibroma is a rare entity, which arises outside nasopharynx. The sites involved are maxillary sinus, ethmoid sinus, sphenoid sinus, nasal septum, middle turbinate, inferior turbinate, cheek, conjunctiva, pterygomaxillary fissure, infratemporal fossa and laryngotracheal tree. Among this maxillary sinus is commonly involved.

When compared to JNA, ENAs occur at slightly older age, i.e. 2nd decade with mean age being reported as 22 years as compared to 17 years for JNA. ENAs have been reported to have a higher incidence in females (6). The clinical manifestations depends on the site and extent of tumor. ENA of nasal septum commonly presents with nasal obstruction and nasal bleeding.

Contrast enhanced CT scan (CECT) and magnetic resonance imaging (MRI) is used to determine the tumour site and its extension, and to see skull base involvement, intracranial spread and relationship to important vascular and neurologic structures(7).

Grossly the mass is polypoidal with a rounded or multinodular contour, with grey-tan cut surfaces. The microscopic finding of ENA shows varying sized blood vessels lined by plump or flattened endothelium

with absent or incomplete smooth muscle coat. The fibrous stroma is a striking feature, composed of spindle or stellate cells.

The differential diagnosis will be lobular capillary hemangioma which is composed of lobules of capillary sized blood vessels which are lined by plump endothelial cells with less fibrous stroma which helps in differentiating it from angiofibroma.

Surgical excision of the mass is the treatment of choice, and recurrence is rare after complete excision.

Conclusion

Though ENA of nasal septum is extremely rare, we conclude that extranasopharyngeal angiofibroma should be considered as a differential diagnosis in a patient presenting with a vascular neoplasm of nasal cavity. As it has tendency to recur in case of incomplete excision and there is chance of excessive bleeding.

References

- [1]. Gullane PJ, Davidson JO. Dwyer T, Forte V. Juvenile angiofibroma: A review of literature and a case series report. *Laryngoscope* 1992;102:928-33.
- [2]. De Vincentiis G, Pinelli V. Rhinopharyngeal angiofibroma in the pediatric age group. *Clinical-statistical contribution. Int J Pediatr Otorhinolaryngol* 1980;2:99-122.
- [3]. Windfuhr JP, Remmert S. Extranasopharyngeal angiofibroma: Etiology, incidence and management. *Acta Otolaryngol* 2004;124:880-89.
- [4]. Huang RY, Damrose EJ, Blackwell KE, Cohen AN, Calcaterra TC. Extranasopharyngeal angiofibroma. *Int J Pediatr Otorhinolaryngol* 2000;561:59-64.
- [5]. Somdas MA, Ketenci I, Unlu Y, Canoz O, Guney E. Extranasopharyngeal angiofibroma originating from the nasal septum. *Otolaryngol Head Neck Surg* 2005;133:1-2.
- [6]. Handa KK, Kumar A, Singh MK, Chhabra AH. Extranasopharyngeal angiofibroma arising from the nasal septum. *Int J Pediatr Otorhinolaryngol* 2001;58:163-66.
- [7]. Alvi A, Myssiorek D, Fuchs. An extranasopharyngeal angiofibroma. *J Otolaryngol*. 1996;25:346-348.

R.Narmadha. "Extranasopharyngeal Angiofibroma of Nasal Septum-A Rare Case Report." *IOSR Journal of Dental and Medical Sciences (IOSR-JDMS)*, vol. 18, no. 04, 2019, pp 22-25.