

Co –Relation Of Fundus Changes & Pregnancy Induced Hypertension – A Prospective Observational Study.

Dr. Shivangini Kumari Shekhawat¹, Dr. Vinu Choudhary^{*2},
Dr. Usha Shekhawat³

¹Resident Doctor, Dept. Of Ophthalmology, Mahatma Gandhi Medical College & Hospital, Jaipur, Rajasthan.

²Fellow in Reproductive Medicine, Dept. Of Reproductive Medicine & Medical Genetics, Mahatma Gandhi Medical College & Hospital, Jaipur, Rajasthan.(Corresponding Author)

³Senior Professor and Head of Reproductive Medicine & Medical genetics, Mahatma Gandhi Medical College & Hospital, Jaipur, Rajasthan.

Corresponding Author: Dr. Vinu Choudhary

Abstract: The national incidence of PIH is 15.2% in India¹, while it is four times higher in primipara women than in multipara. Ocular involvement in PIH is common and the occurrence rate varies from 30-100% in different studies². Objective of the study is to determine the prevalence of retinal changes in pregnancy induced hypertension and to study the association between retinal changes and severity of the PIH. A hospital based cross-sectional study was conducted in the setting of department of Ophthalmology and Obstetrics and Gynaecology, Mahatma Gandhi Medical College, Jaipur, Rajasthan, during the year 2017. The results were analyzed using SPSS program. Majority of patients in our study were found in age group of 21 to 25 years. 74% of patients were primigravida in our study. In our study normal fundus changes were seen in 66% of cases, grade I in 29%, grade II in 5% of cases. Grade III and IV changes were not seen. We can consider presence of the retinal changes to be an indirect marker of severity of PIH and of the prognostic value.

Date of Submission: 20-03-2019

Date of acceptance: 06-04-2019

I. Introduction

Pregnancy induced hypertension (PIH) is a hypertensive disorder in pregnancy that occurs in the absence of other causes of elevated blood pressure (140/90 mmHg, or a rise of 30mmHg of systolic pressure, or a rise of 15mmHg of diastolic pressure), taken on two occasions after rest, in combination with generalized edema and/or proteinuria. When there is significant proteinuria it is termed as preeclampsia; seizures or coma as a consequence of PIH is termed as eclampsia. The incidence of pre-eclampsia in nulliparous population ranges from 3 to 10 per cent worldwide.

The national incidence of PIH is 15.2% in India¹, while it is four times higher in primipara women than in multipara. Ocular involvement in PIH is common and the occurrence rate varies from 30-100% in different studies²

PIH is a multisystem disorder affecting cardiovascular, hepatobiliary system, GIT, cerebrovascular system and eyes. The changes in the retinal vasculature generally, but not always, correlate with the severity of systemic hypertension. Vasospastic manifestations are reversible and the retinal vessels rapidly return to normal after delivery. There is paucity of data available in the published literature on the prevalence of retinal changes in PIH from India³. Therefore, this study was undertaken to determine the prevalence of retinal changes in PIH and association between the retinal changes and severity of PIH.

Objective of the study is to determine the prevalence of retinal changes in pregnancy induced hypertension and to study the association between retinal changes and severity of the PIH.

II. Methodology

Study design

A hospital based cross-sectional study was conducted in the setting of department of Ophthalmology and Obstetrics and Gynaecology, Mahatma Gandhi Medical College, Jaipur, Rajasthan, during the year 2017. Inclusion and exclusion criteria All antenatal pregnant women who fulfilled the following criteria

>34 weeks of pregnancy

high arterial blood pressure systolic BP >140 mm Hg and diastolic BP of 100 mm Hg.

proteinuria

admitted in Obstetric ward were included in this study. Patients who had pre-existing diabetes or hypertension or renal disease or hazy media which did not permit fundus visualization were excluded from the study.

After taking history for any eye symptoms, anterior segment was examined with torch light on the bed itself. Both pupils were dilated with 1% tropicamide eye drops and fundus examination was done by ophthalmologist with direct ophthalmoscope in a semi dark room in the ward. Hypertensive retinopathy changes seen in right or left or both eyes, was taken as positive findings in that patient. Age, race, para, gravida, blood pressure, proteinuria were noted from the case records. The PIH was graded as preeclampsia (mild and severe) and eclampsia. All the findings were noted on a data sheet.

The retinal changes (hypertensive retinopathy) were graded according to Keith Wagener classification into: Grade I – mild generalized arterial attenuation, particularly of small branches; Grade II – more severe grade I + focal arteriolar attenuation; Grade III – grade II + haemorrhages, hard exudates, cotton wool spots; Grade IV – grade III + optic disc swelling (papilloedema)

The severity of PIH was classified into preeclampsia (mild and severe) and eclampsia, based on the following findings: Mild preeclampsia --- BP >140/90mmHg, proteinuria +, and/or mild edema of legs; Severe preeclampsia --- BP >160/110mmHg, proteinuria ++ or +++, headache, cerebral or visual disturbances, epigastric pain, impaired liver function tests, and increased serum creatinine; Eclampsia --- severe preeclampsia + convulsions. Proteinuria was tested using dipstix method and was graded as + = 0.3gm/L, ++ = 1gm/L, and +++ = 3gm/L.

The results were analyzed using SPSS program. A *P* value < 0.05 was taken as significant.

Incidence of PIH in our study was found to be 16%.

Table 1. Table depicting no. of registration status of subjects

	No. of subjects
Registered	89
Unregistered	11

Graph 1.

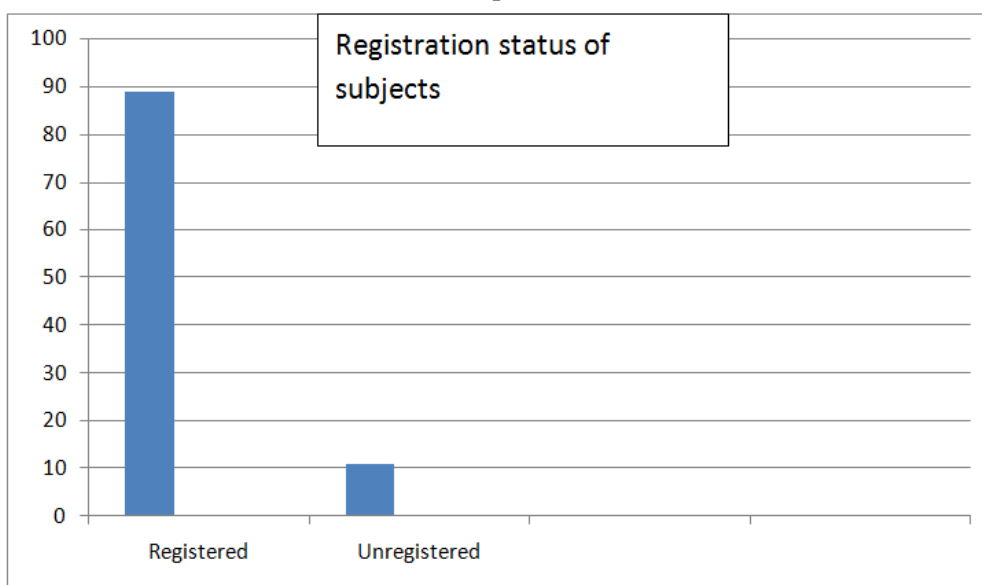


Table 2. Age distribution

Age groups (yrs)	Number of subjects
Upto 20	28
21- 25	34
26-30	19
31-35	13
>=35	06

Graph 2.
Age distribution

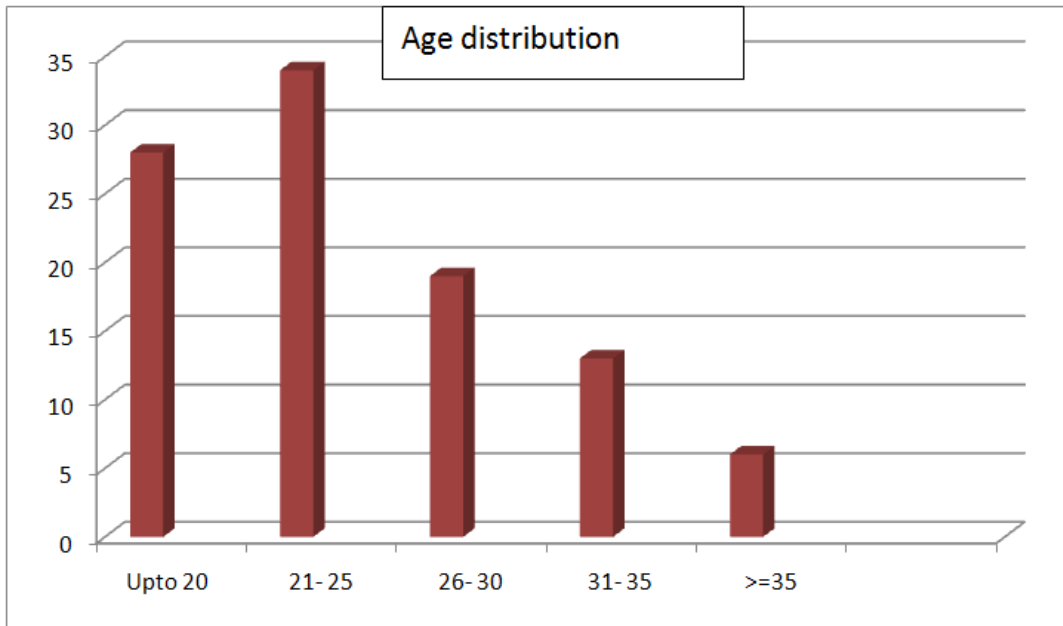


Table 3. Gravida distribution

Gravida status	No. of subjects
Primigravida	74
Multigravida	26

Graph 3. Gravida distribution

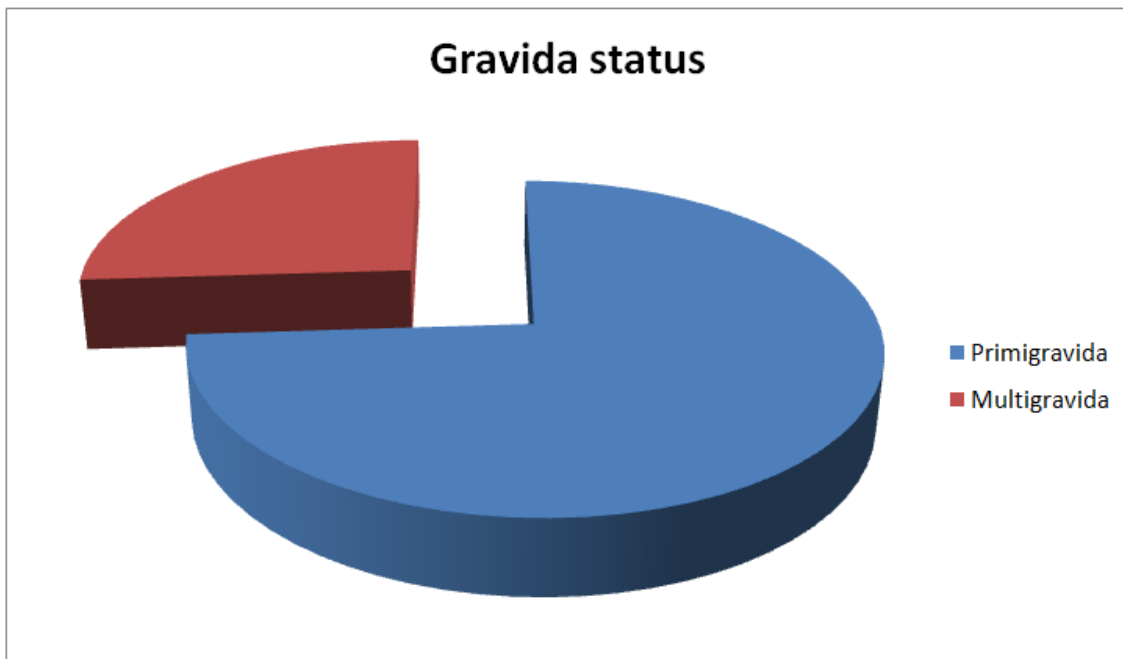


Table 4. Severity of disease

Category of disease severity	No. of Subjects
Gestational Hypertension	25
Mild pre- eclampsia	54
Severe pre- eclampsia	20
Eclampsia	01

Graph 4.

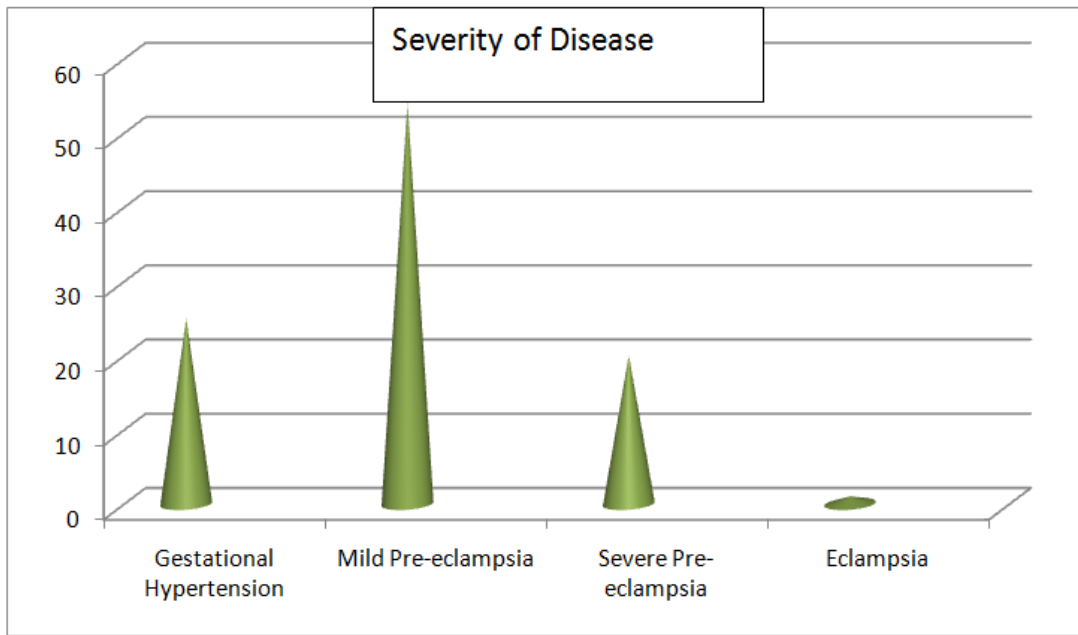


Table 5. Symptoms of Disease

Symptoms	Number of subjects
Asymptomatic	65
Headache	23
Blurring of vision	07
Epigastric pain	05
Sudden loss of vision	00

Graph 5.

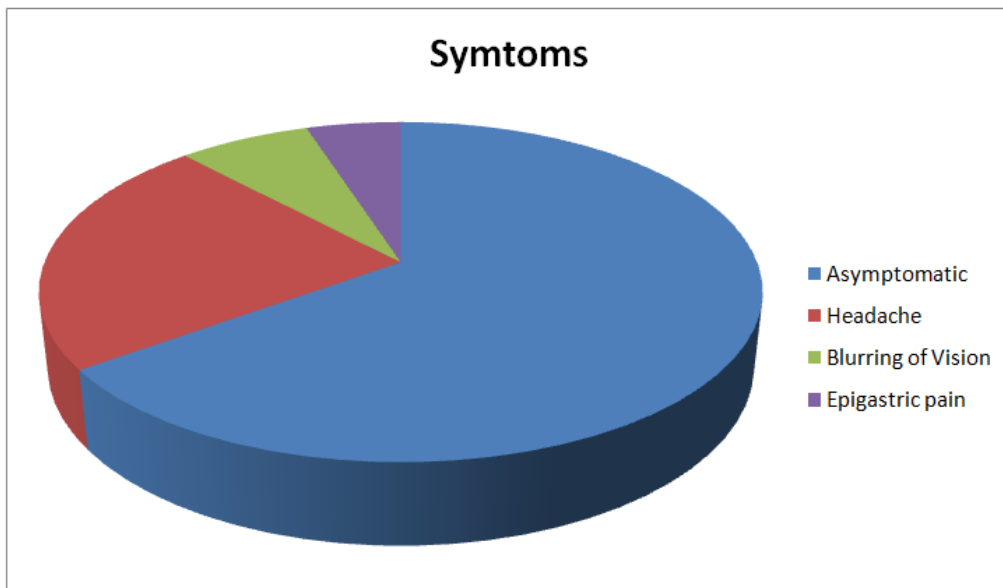


Table 6. Systolic blood pressure and no. of cases of PIH

Systolic BP (mm of Hg)	No. of Subjects
Upto 140	69
141-160	10
161-180	16
181-200	05

Graph 6.

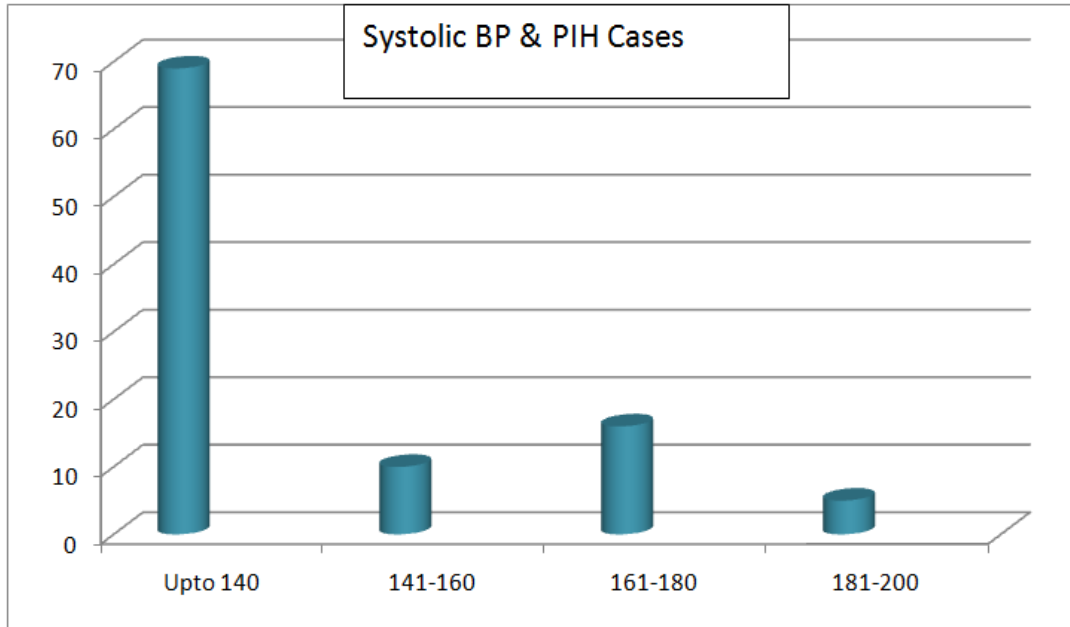


Table 7. Diastolic BP & no. of PIH cases

Diastolic BP (mm of Hg)	No. of subjects
Upto 90	60
91-100	18
101-110	15
111-120	06
>120	01

Graph 7.

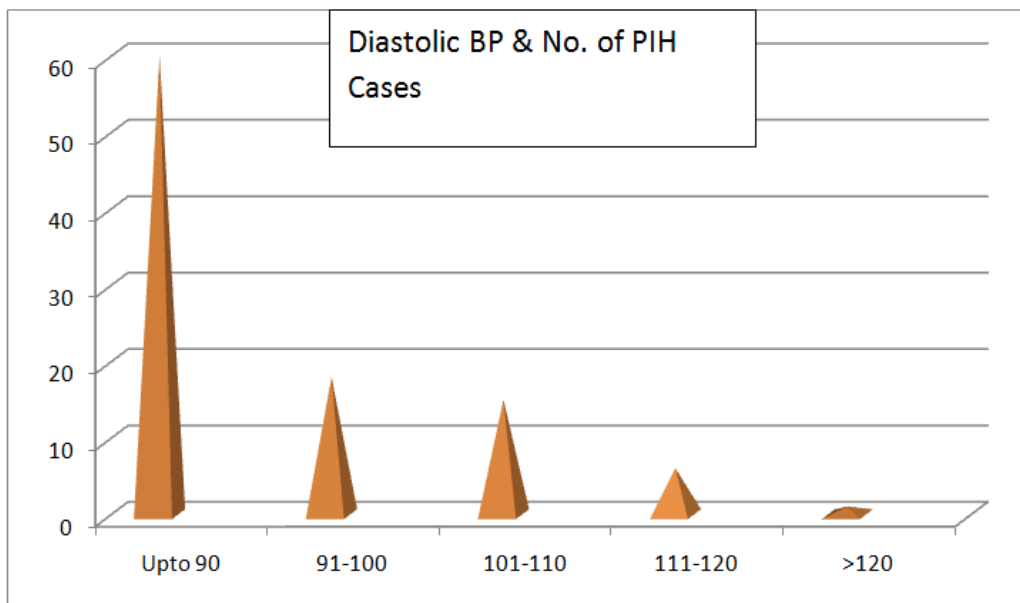


Table 8. Grades of Proteinuria in PIH cases

Grades of Proteinuria	No. of subjects
Traces	25
1+	44
2+	10
3+	17
4+	04

Graph 8.

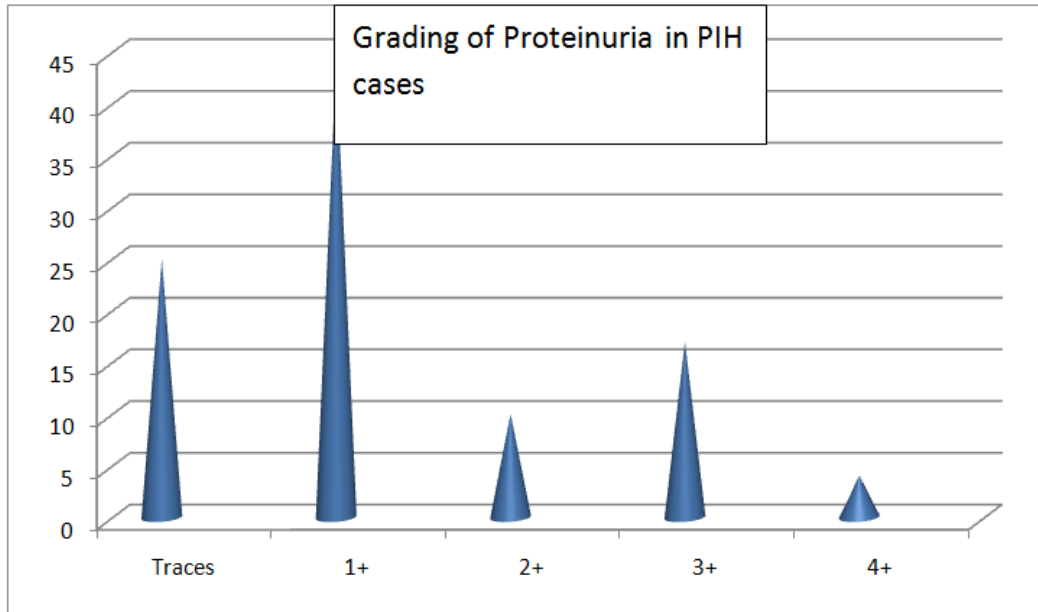


Table 9. Mode of Delivery

Mode of Delivery	No. of Subjects
LSCS	25
Vaginal- spontaneous	27
Vaginal - induced	48

Graph 9.

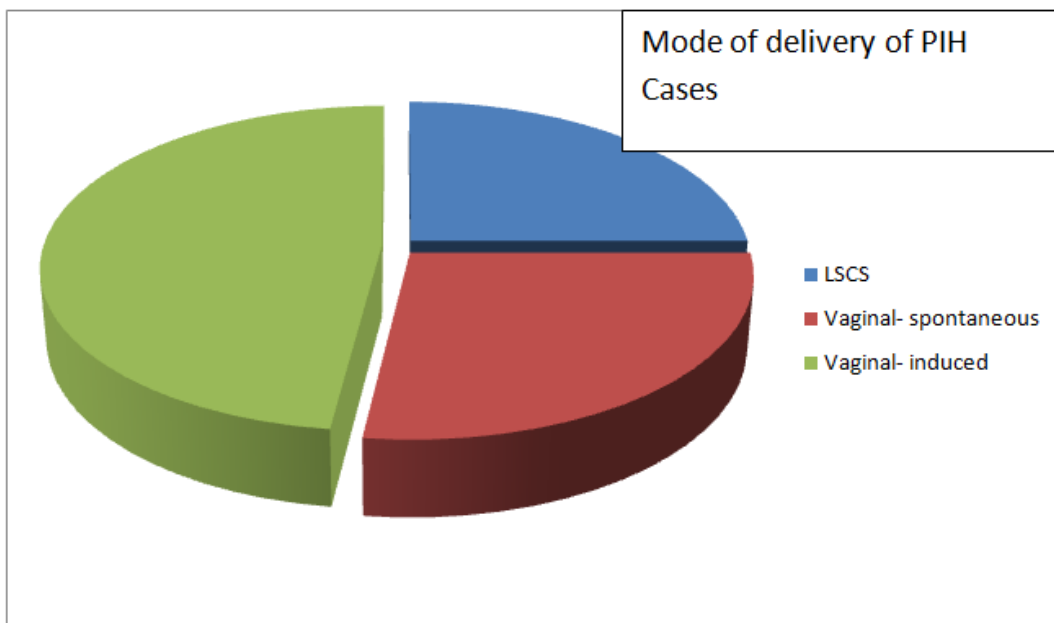


Table10. Ophthalmoscopic changes in PIH (Keith Wagener classification)

	No. of Patients	Percentage(%)
No changes	66	66
Grade I	29	29
Grade II	05	05
Grade III	0	0
Grade IV	0	0

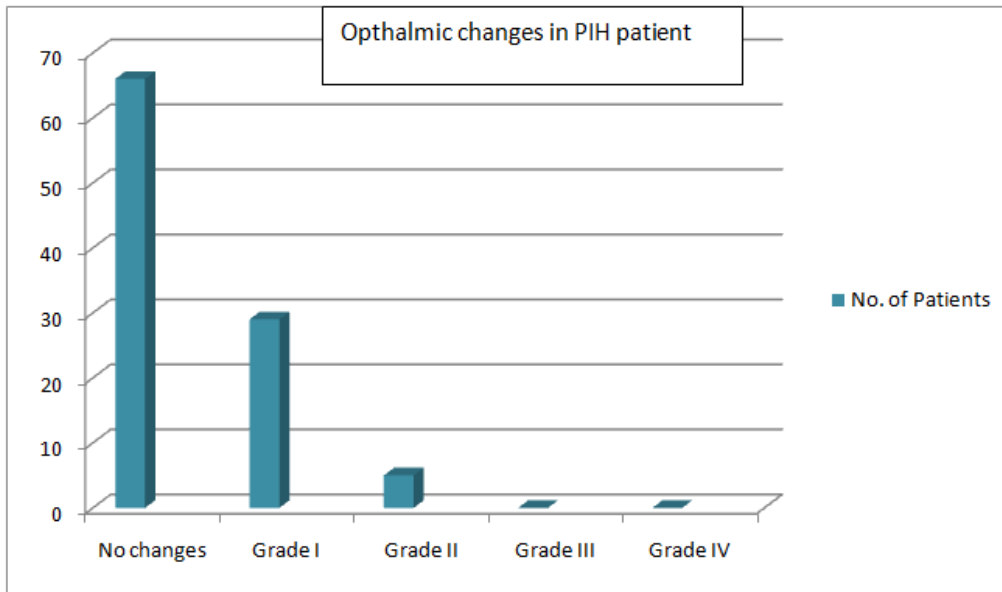
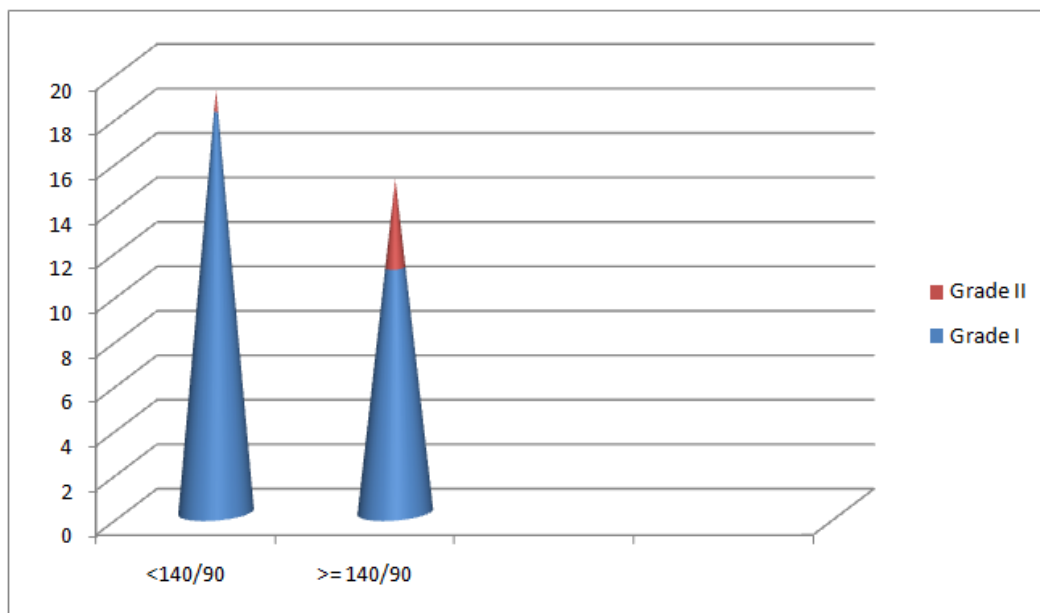


Table 11. BP and Ophthalmic changes (Grade I & II)

BP (mm Hg)	Grade I	Grade II
< 140/90 mmHg	18	01
>= 140/ 100 mmHg	11	04



III. Discussion

Pregnancy Induced Hypertension (PIH) is a challenging stigma in the field of obstetrics and one of the major contributors to maternal and perinatal mortality.

Preeclampsia is a multisystem hypertensive disorder which is a clinical syndrome that afflicts 3-5% of pregnancies and is a leading cause of maternal mortality, especially in developing countries. In pregnancy induced hypertension, the various pathological changes in different organs of the body can be studied directly visualizing the ocular fundus and may give a true index of changes in vascular system of brain and retina. The retinal vascular changes have been said to correlate with the severity of hypertension. Many studies have considered the progression of retinal vascular changes as a sign of increasing severity of PIH and have correlated them with fetal mortality. These changes help as a guideline for termination of pregnancy as they may reflect similar ischemic vascular changes in the placenta.

Fundus changes in Pregnancy Induced Hypertension (Clinical Manifestations in PIH)

The clinical course of fundus changes in PIH may be divided into three stages:

- (i) Spastic stage: Characterised by spasm of retinal arterioles.
- (ii) The stage of sclerosis: When pregnancy induced hypertensive changes are superimposed on pre-existing organic sclerotic changes in the vessels.
- (iii) The stage of retinopathy: Characterised by cotton wool spots, micro aneurysms, flame shaped and splinter haemorrhages, hard exudates, disc edema etc.

Majority of patients in our study were found in age group of 21 to 25 years. Mean age-group of patients in the present study matches with the studies by Karki *et al.*, and Shukla *et al.*, Tadin *et al.* In a study by Jaffe and Schatz, mean age of patients with pre-eclampsia was 28 years. Mean age of patients in studies by Tadin *et al.*, Jaffe, and Schatz was higher than that of our study.

74% of patients were primigravida in our study which is supported by studies conducted by Jaffe and Schatz *et al.* and was also found to be statistically significant. Majority of patients belonged to mild pre eclampsia category in our study with 69% of patients having systolic BP upto 140 mm Hg and 60% of patients having diastolic BP upto 90 mm Hg.

According to Duke Elder the most common retinal change is attenuation of retinal arterioles, occurring in approximately 60% of patients with pre-eclampsia⁴. In our study grade I retinal changes were noticed in 29% of cases i.e. generalized arterial attenuation. From above, it is seen that arteriolar attenuation is the major retinal change seen in PIH.

We did not find any case of retinal edema in pre-eclampsia group. Reddy *et al.*, found 6 cases (3%) with retinal hemorrhages and 6 cases (3%) with cotton wool spots belonging to severe pre-eclampsia. Naval *et al.*, found 1.5% of cases with cotton wool spots and retinal hemorrhage. Francis *et al.*, found 5% of cases with cotton wool spots and retinal haemorrhage⁵. None of these three studies showed observations as we found in our study. Reddy SC *et al.*, (2012) in their study did not find any case of retinal detachment which is in conjunction with our study.

In our study normal fundus changes were seen in 66% of cases, grade I in 29% , grade II in 5 % of cases. Grade III and IV changes were not seen. In the study by Tadin *et al.*, the percentage of occurrence of Grade I retinal vascular changes in PIH cases was similar to that of our study. Reddy *et al.*, (2012) in their study found higher percentage of occurrence of Grade I retinal vascular changes (52.6%) as compare to our study. In the study by Reddy *et al.*, (2012), the percentage of occurrence of Grade II retinal vascular changes in PIH cases was similar to that of our study. Tadin *et al.*, in their study found higher percentage of occurrence of Grade II retinal vascular changes (15%) as compare to our study⁶.

Vision is important criteria to be seen in these patients including on follow-up after delivery. Most cases of late onset severe eclampsia present with exudative retinal detachment which usually resolves with termination of pregnancy. Vision and the retinal findings documented need to be followed up after the termination of pregnancy and any residual optic nerve affection should be correlated. In our study on follow-up examination of cases after termination of pregnancy, all the changes were resolved with no residual retinal or optic nerve changes^{7,11}.

It is believed that the presence of changes in the retinal arterioles^{7,8} and retinal haemorrhages may indicate similar changes in the placenta. Since the well being of the foetus depends on the placental circulation, ophthalmoscopic examination of mother's fundus may give a clue to similar micro-circulation changes in the placenta and indirectly to the foetal wellbeing. Fundus examination in patients with PIH is an important clinical evaluation to predict adverse foetal outcomes^{9,10}.

IV. Conclusion

Retinal changes progress with severity of PIH. Ocular examination reveals important objective information concerning the disorder. Also, we can consider presence of the retinal changes to be an indirect marker of severity of PIH and of the prognostic value.

References

- [1]. Kamath RK, Nayak SR. Preeclampsia/Eclampsia and retinal micro vascular characteristics affecting maternal and foetal outcome: a prospective study amongst south indian pregnant women. IJIRD. 2013;2(11): 444-8.
- [2]. Dornan KJ, Mallek DR, Wittmann BK. The sequelae of serous retinal detachment in preeclampsia. *ObstetGynaecol.* 1982;60(5):657-63.
- [3]. Rasdi AR, Nik-Ahmad-Zuki NL, Bakiah S, Shatriah I. Hypertensive retinopathy and visual outcome in hypertensive disorders in pregnancy. *Med J Malaysia.* 2011;66(1):42-7.
- [4]. Jaffe G, Schatz H. ocular manifestations of preeclampsia. *Am J Ophthalmol.* 1987;103(3 Pt1):309- 15. 23. Reddy SC. Raghavamma TV. Retinal detachment in preeclampsia- a case report. *J ObstetGynaec of India.* 1981;31(3):501-3.
- [5]. McEvoy M, Runicman J, Edmonds DK, Kerin JF. Bilateral retinal detachment in association with preeclampsia. *AustNZ J ObstetGynaecol.* 1981;21(4):246-7.
- [6]. Jyotsana, Sharma AK, Bhatt S. Reversible blindness in severe preeclampsia and Eclampsia. *JK Sci.* 2004;6:43- 5.

- [7]. Ryan SJ, Sunness JP. Pregnancy and retinal disease. In: Ryan SJ, eds. Retina. 1994;2:1393-403. 27. Karki P, Malla KP, Das H, Uprety DK. Association between pregnancy induced hypertensive fundus changes and fetal outcome. Nepal J Ophthalm
- [8]. Classification of hypertension in pregnancy (National blood pressure education program 2000 and ACOG - 2013. 12. Noraihan MN, Sharda P, Jammal AB. Report of 50 cases of eclampsia. J ObstetGynaecol Res. 2005;31(4):302-9.
- [9]. Nalliah S, Thavarasha AS. Transient blindness in pregnancy induced hypertension. Int J Gynaecol Obstet.1989;29(3):249-51.
- [10]. Abu Samra K. The eye and visual system in the preeclampsia/eclampsia syndrome: what to expect? Saudi J of Ophthal. 2013;27(1):51-3.
- [11]. Das KA, Jaisal P. Fundus Changes in Pregnancy Induced Hypertension. Int J Med Res Prof. 2016;2(2):47-50.

Dr. Shivangini Kumari Shekhawat. “Co –Relation Of Fundus Changes & Pregnancy Induced Hypertension – A Prospective Observational Study.” IOSR Journal of Dental and Medical Sciences (IOSR-JDMS), vol. 18, no. 04, 2019, pp 46-54.