

Diplopia after Local Anaesthesia

Dr. P. Kamalakannan¹, Dr. C. Prasad², Dr.R.Karthikeyan³

¹(Senior assistant professor Government peripheral hospital (periyarnagar) Madras medical college, TN.Dr.MGR Medical University Chennai, Tamil Nadu, India)

²(Professor and HOD Dept of oral and maxillofacial surgery, Tamil Nadu Government Dental College and Hospital, TN Dr.MGR Medical University Chennai, Tamil Nadu, India)

³(Senior Assistant Professor Dept of Dental Surgery, Govt Royapettah Hospital, Kilpauk medical college), TNDr.MGR Medical University Chennai, Tamil Nadu, India

Corresponding Author- Dr.R.Karthikeyan

Abstract : Local anaesthesia is safely used in routine dental practice. Diplopia following LA injection is a rare but distressing complication. This article elaborates a case of diplopia following local anaesthetic injection and stresses the importance of awareness among the dental surgeons about such rare complication and its management.

Keywords: Diplopia,

Date of Submission: 20-03-2019

Date of acceptance: 06-04-2019

I. Introduction

Local anaesthesia is routinely used in dental practice and is usually safe. However it has certain local and systemic complications. Local complications include infection, trismus, hematoma, facial nerve palsy, and rarely ophthalmic consequences. While systemic complications include syncope, toxicity, allergy, and rarely neurological effects¹.

Diplopia or double vision as it is commonly known is the simultaneous perception of two images of a single object. It is of two types - monocular and binocular. Monocular diplopia is usually due to globe injury and is rarely encountered in oral surgical practice. Binocular diplopia is usually the result of impaired function of the extra ocular muscles.

II. Case Report

A 19 year old female patient reported to the OP with a chief complaint of pain in left lower back tooth region for past 1 month. She had no relevant past medical, Dental or surgical history. No History of drug allergy as well. Clinical and radiological examination revealed an distoangularly Impacted 38. Routine blood investigations were carried out and she was posted for surgical removal of 38 under local anesthesia

In semi supine position, routine Inferior Alveolar Nerve block was given using 25 mm, 27-gauge needle with 3ml of 2% lignocaine with 1 : 1,00,000 adrenaline by direct method. Aspiration was negative. Effectiveness of LA was checked both objectively and subjectively. Impacted 38 was removed

Towards the end of the procedure, patient complained of double vision. She was nervous and apprehensive, Vitals were stable. The cranial nerves II, III, IV, V, VI and VII were examined. She had restricted movement of left eye (Figure -1) on lateral excursion suggesting impaired function of the left lateral rectus muscle. Thus it was confirmed that the patient developed Binocular diplopia following the injection

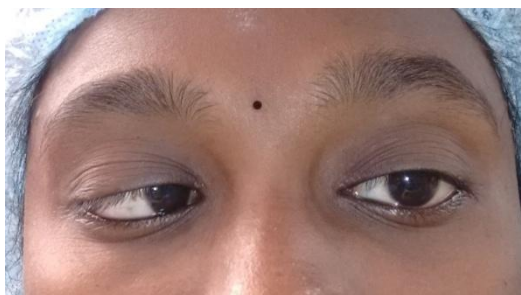

Figure-1 - Diplopia following injection

Affected eye was covered with gauze, After 40 minutes, she recovered gradually and there was conjugate movement of eye completely after 2 hours(Figure 2).Reassurance was given that condition is transient and she escorted with her attender.

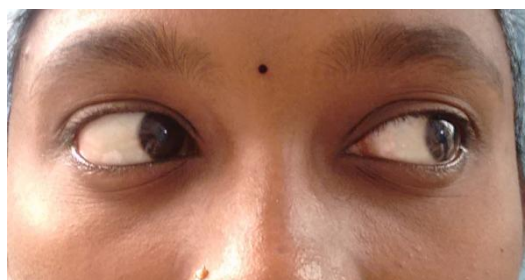

Figure- 2 - Recovery after 2 Hours

III. Discussion

Ophthalmic complications of LA is a rare phenomenon and reported more commonly in females than males. It includes - Diplopia(39.8%), Ptosis(16.7%), Mydriasis(14.8%) and Amaurosis(13%)^{2,3,4}. It is more Common with Gow-Gates technique and posterior superior alveolar nerve block as the solutions are deposited at a higher level in these nerve blocks compared to classic technique.

The various ways through which the local anaesthetic reaches the orbit includes – arterial route, venous route and by direct diffusion through spaces⁵.

Arterial route - the inferior alveolar artery lie in close proximity to the inferior alveolar nerve and if the LA solution is inadvertently and forcefully injected in to the artery, it can pass in an retrograde fashion in to maxillary artery then the middle meningeal artery and can reach the lateral rectus muscle through its ophthalmic and lacrimal branches (Figure -3)

Venous route – similarly the solution injected in to the inferior alveolar vein can pass into pterygoid plexus of veins from there the solution can involve the abducent nerve either via the cavernous sinus or via the inferior ophthalmic vein causing paresis of lateral recti muscle (Figure -4)

Direct diffusion – here the solution diffuses in to infratemporal fossa, pterygomaxillary fossa, and then in to the orbital cavity via the inferior orbital fissure (Figure -5)

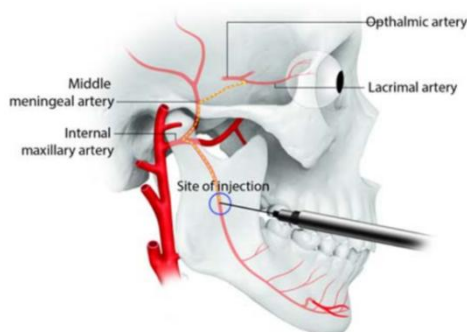


Figure 3 - arterial route

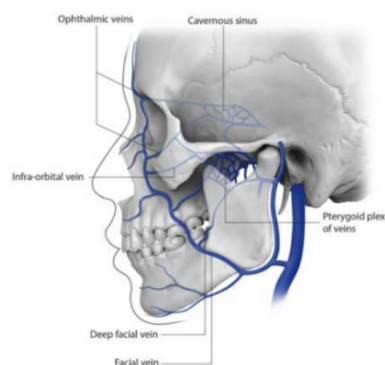


Figure 4- Venous route

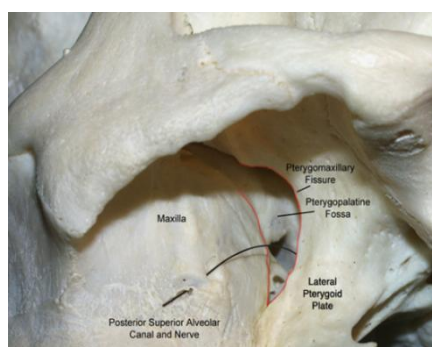


Figure -5 Direct diffusion

Though the way through which the solution has reached the orbit in our case cannot be ascertained clinically, it has definitely involved either the lateral recti muscle directly or its nerve supply, the abducent nerve.

If an ophthalmic complication occur, patient should be observed for vital signs, pupillary reflexes, eyeball movements, facial muscle movements and for blanching (the activation of sympathetic plexus due to the injury to vessel wall)

Though the ophthalmic complications are rare they are highly distressing to the patient and hence due precautions should be carried out before administration of LA, these include aspiration of the syringe checked in two planes and slow administration with frequent aspiration.

Management of the patient who developed an ophthalmic complication include Reassurance, Protection the affected eye with gauze tape and Referral to ophthalmologists If persists for more longer than 6 hours

IV. Conclusion

Ophthalmic complications are rare but distressing. Dental surgeons who routinely use local anesthetic in their practice should be aware of this rare complication and should take prompt steps in preventing and managing the same.

References

- [1]. Malamed S. Handbook of local anesthesia. 5th ed. St Louis. Mosby, 2004.
- [2]. Steenen SA, Dubois L, Saeed P, de Lange J. Ophthalmologic complications after intraoral local anesthesia: case report and review of literature. *Oral Surg Oral Med Oral Pathol Oral Radiol* 2012; 113: e1-5.
- [3]. Boynes SG, Echeverria Z, Abdulwahab M. Ocular complications associated with local anesthesia administration in dentistry. *Dent Clin North Am* 2010; 54: 677-86.
- [4]. Choi EH, Seo JY, Jung BY, Park W. Diplopia after inferior alveolar nerve block anesthesia: report of 2 cases and literature review. *Oral Surg Oral Med Oral Pathol Oral Radiol Endod* 2009; 107: e21-4.
- [5]. *J Dent Anesth Pain Med* 2015;15(2):93-96 Diplopia after inferior alveolar nerve block: case report and related physiology - Tae Min You Department of Advanced General Dentistry, Dankook University, Cheonan, Korea
- [6]. Khoury JN, Mihailidis S, Ghabriel M, Townsend G. Applied anatomy of the pterygomandibular space: improving the success of inferior alveolar nerve blocks. *Aust Dent J* 2011; 56: 112-21.

Dr.R.Karthikeyan. "Diplopia after Local Anaesthesia." *IOSR Journal of Dental and Medical Sciences (IOSR-JDMS)*, vol. 18, no. 04, 2019, pp 43-45.