

A Study on Clinical Presentation, Etiology and Management of Liver Abscess Based On Diagnosis by Radiological Imaging

Dr. R.Vijaya Lakshmi¹, Dr.K.Velmurugan², Dr. S.Santhosh Babu³

¹(Associate professor Department Of General Surgery , Govt Chengalpattu medical college, chengalpattu-India)

²(Assistant professor Department Of General Surgery, Govt Chengalpattu medical college, chengalpattu-India)

³(Post graduate Department Of General Surgery, Govt Chengalpattu medical college, chengalpattu -India)

Corresponding Author: Dr.K.Velmurugan

Abstract

Background : liver abscess was first described as early times of Hippocrates ,earlier laparotomy&drainage was the mainstay, with better imaging modality aspiration & catheter insertion is treatment now a days.

Aim: 1. To study incidence /age & sex distribution

2. To analyze clinical features

3. To throw light on the radiological imaging & plan management accordingly

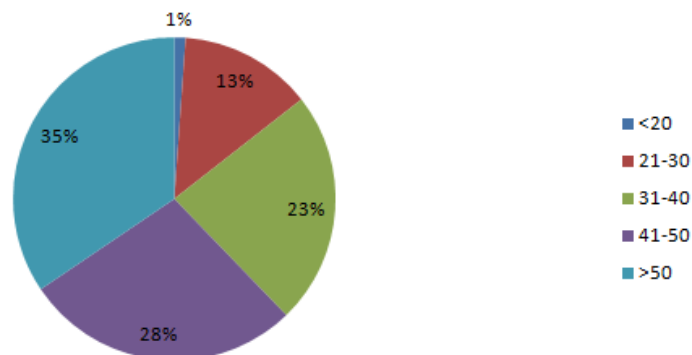
Date of Submission: 15-04-2019

Date of acceptance: 30-04-2019

I. Introduction

In our study peak age incidence was noticed in 5th decade followed by fourth and sixth decade. In our study incidence of liver abscess in males is 85% which also correlates with history of alcoholism present in 80% of cases. As our observation the most common symptom being abdominal pain 93% followed by fever 74%, amongst clinical signs liver enlargement 52% and RUQ tenderness 65%; jaundice 14%. In present study RUQ tenderness is commonest clinical sign accounting to 65%; hepatomegaly 52% and jaundice 15%. In our current study among laboratory values anemia was seen in 67%; leukocytosis in 58% of cases; increased bilirubin in 24% and increased SAP 47%. Most common feature in chest and abdomen radiograph raised dome of diaphragm seen in 49%. Pleural effusion seen in 17% and basal Atelectasis in 12% of cases. Majority of cases ranging in size of abscess cavity from 5 – 10 Cm. About 70% of cases have right lobe involvement as compared to 16% in left lobe. 14% of cases have both lobe involved. Solitary abscess is seen in 66% of cases as compared to multiple abscesses in 34%. All right lobe abscess were diagnosed by clinical enlargement of liver where as such definite lobe enlargement was not seen in left lobe abscess. The highest incidence of right lobe abscess in this study (70%) correlated with previous study. Out of 90 cases studied, for about 35 cases closed needle ultrasound guided aspiration was done. We did aspiration using 14 gauge needle for the patients in whom conservative line of management fails and for abscess of more than 5CM size less than 10CM size. We did percutaneous drainage for 17 cases out of 90 cases which accounts for 19%. Percutaneous catheter insertion was done under ultrasound guidance. We did laparotomy and open drainage for 13 cases which presented as. The most common treatment modality in our study was aspiration 39% followed by conservative management in 28%.

AGE DISTRIBUTION



SEX DISTRIBUTION

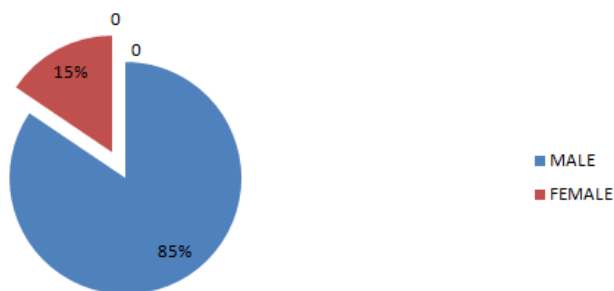


TABLE 1- CLINICAL PRESENTATION

SYMPTOMS	NO OF CASES	PERCENTAGE
Abdominal Pain	84	93.3
Fever	67	74.4
Nausea& vomiting	27	30
Anorexia	32	35.5
Loss of weight	18	20
Dysentery	30	33.3
Cough/ Pleurisy	24	26.6
h/o of alcohol	72	80

TABLE 2 – EXAMINATION FINDINGS

CLINICAL SIGNS	NO OF CASES	PERCENTAGE
Hepatomegaly	47	52.2
RUQ tenderness	58	64.4
Intercostal tenderness	32	35.5
Jaundice	13	14.4
Pleural effusion	03	3.3

TABLE: 3 MODES OF PRESENTATION

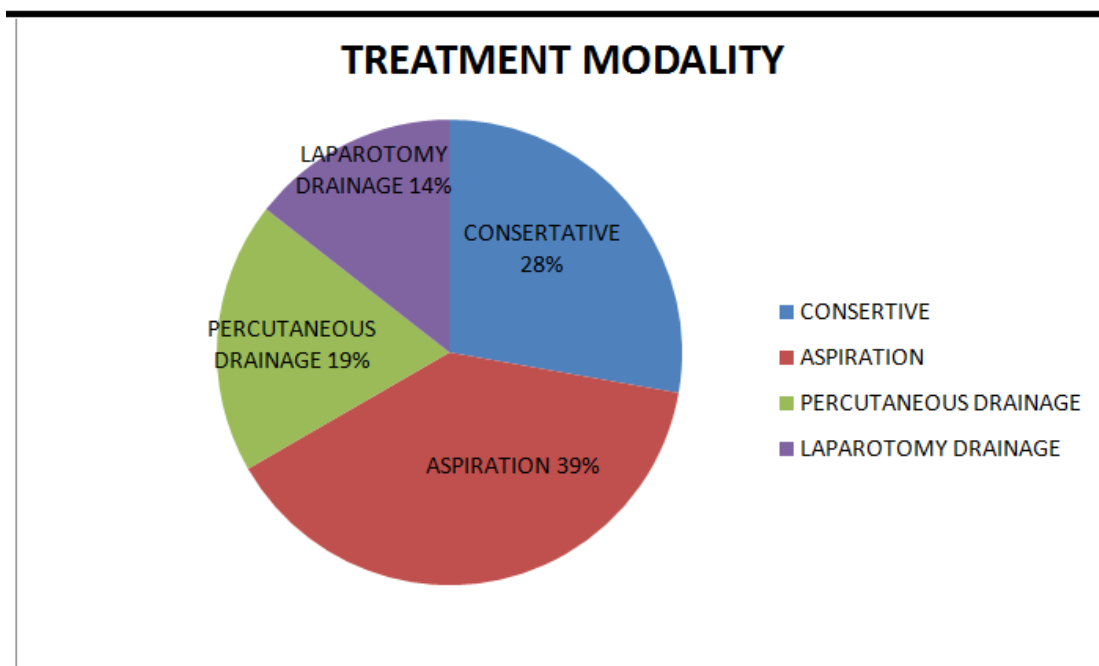
PRESENTATION	NO OF CASES	PERCENTAGE
Classical	70	77.7
Peritonitis	13	14.4
Rupture into thoracic cavity	3	3.3
Silent	4	4.4

TABLE 4 – RADIOLOGICAL INVESTIGATION

RADIOLOGICAL FEATURE	NO OF CASES	PERCENTAGE
Raised dome of diaphragm	44	48.8
Pleural effusion	15	16.6
Basal atelectasis	11	12.2
Enlarged Liver	29	32.2
Ground glass appearance	7	7.7

ULTRASONOGRAM ABDOMEN :-

SIZE IN ABSCESS IN USG	NO OF CASES	PERCENTAGE
<5	17	19
5-10	49	54.4
>10	24	26.6



II. Conclusion

Incidence of liver abscess is 0.8% of total admissions in our hospital. Incidence of Amoebic liver abscess very common in our study. H/O alcoholism was seen in 80% of patients. Male Predominates both in amoebic and Pyogenic liver abscess very common in the ratio of 6:1. Anemias, Leucocytosis were common Accompaniments. Commonest symptom is abdominal pain and fever, sign being Tender hepatomegaly and RUQ Tenderness. Clinical diagnosis of liver abscess is straight forward except for those presenting with complications. E. histolytica was isolated only 13% in stools and 10% of patients in aspirated pus. Ultrasound is the commonest and most useful investigation for diagnosis, treatment as well as follow up.

References

- [1]. Ochner A, Debakay, M. Murray, Pyogenic abscess of the liver. *A.M.J.Surg* 1938:40:292
- [2]. Barnes PF, Decock KM et al. A comparison of Amoebic and pyogenic abscess of the liver. *Medicine* 1987 66:472
- [3]. Dela Rey N.J, Simjee AE, Patel A. Indication for Aspiration of Amoebic liver abscess. *SAfr med.J.* 1989:75:373.
- [4]. Balasegaram M. Management of Hepatic abscess. *CurrSurg* 1981 18:283
- [5]. Bailey and love's short practice of Surgery. 24th Edition.
- [6]. Lamont N.M, and Pooler NR (1958). Hepatic Amoebiasis. *Quart, J.Med* 27:389.
- [7]. Patterson M, Healey, GR. Shabot JM (1980). Serological Testing for Amoebiasis. *Gastroenterology* 78, 136.
- [8]. Essential Surgical practice A. Cuschieri M.D., G.R. Giles MS, A.R. Moosa M.D. 4th Edition.
- [9]. Wilmott AJ. (1962) Clinical Amoebiasis, Blackwell Scientific Publication, Oxford.
- [10]. Lippincott's Color Atlas and Text Book of Diagnostic Micro Biology 5th Edition.
- [11]. Reynolds T.B. Amoebic abscess of liver *Gastroenterology* 60:952-953 1971.

Dr.K.Velmurugan. "A Study on Clinical Presentation, Etiology and Management of Liver Abscess Based On Diagnosis by Radiological Imaging." *IOSR Journal of Dental and Medical Sciences (IOSR-JDMS)*, vol. 18, no. 04, 2019, pp 13-16.