

Recent Advances in Provisional Restorations

Dr J Gandhimathi¹, Dr M Kanmani², Dr S Nasreen³, Dr K Vinayagavel⁴, Dr C Sabarigirinathan⁵, Dr L Srinidhi⁶

1, 2- Assistant professor, TNGDC and hospital, Chennai

4- Professor, TNGDC and hospital, Chennai

5- Professor and HOD, TNGDC and hospital, Chennai

3, 6- PG Students, TNGDC and hospital, Chennai

Corresponding Author: Dr J Gandhimathi

Abstract: Provisional, interim or transitional restoration has been demonstrated to function as an important component in the majority of the various dental disciplines. Provisional FPDs are the prototype on which functional, occlusal & aesthetic adjustments are made to optimize the definitive prosthesis.²

Key words: Provisional restoration, Interim restoration

Date of Submission: 11-04-2019

Date of acceptance: 26-04-2019

I. Introduction

A fixed or removable prosthesis, designed to enhance aesthetics, stabilization and /or function for a limited period of time, after which it is to be replaced by a definitive prosthesis. Often such prosthesis are used to assist in the determination of the therapeutic effectiveness of a specific treatment plan or the form and function of the planned for definitive prosthesis.³ Provisional means established for a time being, pending a permanent arrangement. The term provisional, interim & transitional have been routinely used interchangeably in the literature.⁵

Functions of provisional restoration

Provisional restorations are used in the interim between tooth preparation and filling a definitive restoration. Provisional treatment can also provide an important tool for the psychological management of patients where a mutual understanding of treatment can be identified.

- **Comfort/Tooth vitality:** With crown preparation provisional restorations are generally essential to cover freshly cut dentine and prevent sensitivity, plaque build-up, and subsequent caries and pulp pathology. It also sedate prepared abutments.
- **Occlusion and Positional Stability:** To prevent unwanted tooth movement by the maintenance of interocclusal and proximal contacts. It may be necessary to establish a holding contact on the provisional restorations. Depending on the patient's occlusal scheme, the provisional restoration may need to provide guidance in protrusive and lateral excursions to prevent working and non-working interference. Interproximal contacts also need to be maintained to prevent food packing.
- **Gingival Health and Contour:** To facilitate oral hygiene and prevent gingival overgrowth, provisional restorations require accurate margins and cleansable contour. They can be used in the interim where the level of the gingival margin had yet to stabilize.
- **Aesthetics:** To provide adequate interim appearances provisional restorations should either mimic the tooth just prepared or the final intended restorations.
- **Diagnostic Uses:** Provisional Restoration especially those used for conventional preparations, are invaluable in situations where aesthetics, occlusal or periodontal changes to a patient's dentition are planned.³

Aesthetic Changes: Proposed changes to the shape of anterior teeth are best tried out with provisional restorations to ensure patient acceptance and approval from friends and family, clearly it is easier to trim or add acrylic than it is porcelain. Once happy an alginate is recorded so that the technician can copy the shape into definitive restoration. It is however important to balance the time spent doing this against the advantages of having a diagnostic wax up and matrix made in the laboratory.

Occlusal Changes: A patient's tolerance to changes in anterior guidance or increased occlusal vertical dimension is best tried out with provisional restorations.

Requirements of Provisional Restoration

The properly fabricated provisional restorations must take into account several interrelated factors, which can be classified as biologic, mechanical and esthetic.⁹

Mechanical

- Resist functional load.
- Resist removal forces
- Maintain interabutment alignment.

Biological

- Protect pulp
- Maintain periodontal health.
- Provide occlusal compatibility.
- Maintain tooth position.
- Protect against fracture.

Aesthetics

- Easily contourable.
- Colour compatibility.
- Translucency.
- Colour stability.

Indications of provisional restorations

- Diagnostic: Prior to making the final restoration it may be advisable to determine the prognosis of the pulps and the periodontium of the prepared tooth. The dentist can evaluate the occlusal scheme [axial loading and lateral function], prior to the completion of the final restorations.
- Protective: Cut dentine and associated pulp are protected from salivary, thermal and chemical irritants. The gingival is also protected when restorations are properly formed.
- Restorative: Replacement of teeth, especially immediate anterior replacements.
- Stabilization or Provisional Splinting: Stabilization is of great importance in the treatment of periodontal weakened teeth. Amstar dam described this type of temporary restoration as a provisional splint, he suggested that it will stabilize the weakened teeth and it can be removed to provide access during periodontal surgery.

TYPES OF PROVISIONAL RESTORATION

Provisional restorations can be classified based on the following methods:

1. Method of fabrication
2. Type of material used.
3. Duration of use
4. Techniques for fabrication.

Depending on Method of Fabrication

a) Custom Made: The restoration is fabricated to reproduce original contours of the tooth. An impression of the prepared tooth is made and a cast is poured. The prepared tooth on cast is waxed up & carved to reproduce the original contours.

Advantage:

- Minimum interference
- A wide variety of materials can be used.
- Helpful in evaluating the adequacy of tooth reduction. By measuring the thinness of restoration, the tooth preparation can be altered.

Disadvantage:

- Additional lab procedure involved.
- Time consuming.

b) Preformed Provisional Restoration: - Preformed crowns are commercially available prefabricated crowns. These crowns are available in various sizes. The operator can choose the size and material that would best suit the patient.

Advantage:

- Less time consuming.

Disadvantage:

- Rarely satisfies the requirement of contours. It has to customize with self-cure resin.
- Generally limited to single tooth restoration.

II) Depending on the Type of Material Used¹⁰¹

A) Resin based Provisional Restoration

The various resin-based materials used to make provisional restorations are:

- Cellulose acetate
- Polycarbonate
- Polymethyl methacrylate: chemically activated resin.
- Poly-R-methacrylate: R group could be ethyl or isobutyl form of resin.
- Micro-filled Composite: BISGMA
- Urethane di-methyl acrylate: light-cured resins

B) Metal Provisional Restoration

Metal provisional restorations are usually fabricated using:

- Aluminum
- Nickel – Chromium
- Tin –Silver

III) Depending On Technique of Fabrication¹⁰¹

Based on Technique of fabrication, provisional restorations can be classified:

- a) Provisional Restorations fabricated using direct technique
- b) Provisional Restorations fabricated using indirect technique.
- c) Provisional Restorations fabricated using direct – indirect technique.

IV) Depending On Duration of Use⁶

Based on the duration for which restoration is intended to be used, provisional restorations can be classified:

- a) Short term provisional, for use up to 2 weeks
- b) Long term provisional, for use from 2 weeks to a few weeks

A) Short Term Provisional Restoration

- These are used when prosthesis is to be used for a maximum for 2 weeks.
- They are indicated after tooth preparation in FPDs.
- They are either custom made resin or available as preformed crowns.
- Polycarbonate or aluminum crowns are the most commonly used Short-term provisional restoration

B) Long Term Provisional Restoration

They are mainly made of cast metal. Though their strength is more than average, they have history of frequent breakage.

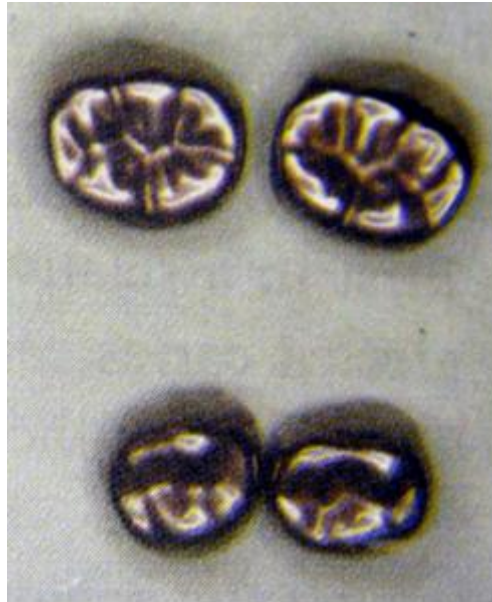Limitations of temporisation

- 1) Lack of Inherent Strength: - Temporaries fracture in long span coverage in patients with bruxism habits or a reduced interocclusal clearance, if the bulk is increased, the patients discomfort is evident.
- 2) Poor Marginal Adaptation: - This inherent deficiency is difficult to improve upon. Temporization infers “adequate” at best.
- 3) Colour Instability: -This is apparent when temporary restorations are placed for an inordinate time.
- 4) Poor Wear Properties: - Teeth will drift or torque if the patient places heavy occlusal stresses upon the interim coverage.
- 5) Detectable Odour Emission: - This is undeniable despite the dentists close attention to sufficient embrasure spaces. Resins are porous.
- 6) Inadequate Bonding Characteristics: - Few types of cement currently secure an adequate interface relationship with resins. Eugenol – bearing sedative cements are notorious for incompatibility with methyl methacrylate resins.
- 7) Poor Tissue Response to Irritation: - Mild or moderate tissue irritations is always present. Certain techniques are merely less irritating than other techniques.

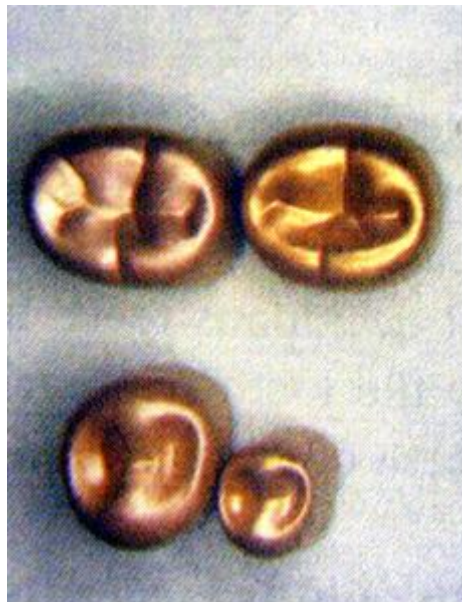II. Conclusion

Interim restorations are a critical component of fixed prosthodontic treatment. In addition to their biologic and biomechanical requirements, interim restorations provide the clinician with valuable diagnostic information. They act as a functional and aesthetic try-in and serve as a blue-print for the design of the definitive prosthesis.

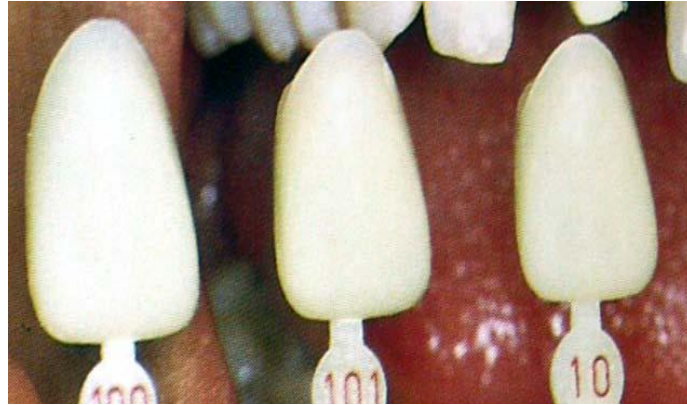
Although provisional restorations are usually intended for a short period of time and then discarded, they can be made to provide pleasing aesthetics, adequate support, and good protection for the teeth.



Silver crowns



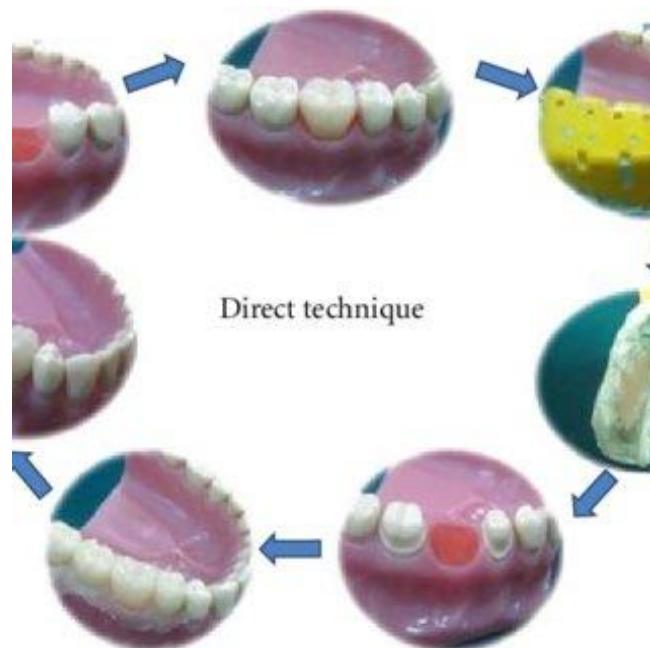
Nickel-Chromium crown



Polycarbonate crowns



Cellulose Acetate crown



Custom made restoration

References

- [1]. Abdullah Samani SI, Harris WT. Provisional restorations for anterior teeth requiring endodontic therapy. *J Endod* 1979; 5:340-3.
- [2]. Adams WK. A temporary fixed partial denture. *J Prosthet Dent* 1970;24:571-2.
- [3]. Appleby DC, Doukoudakis, Doukoudakis A. Improved occlusal surface detail with the vacuum-formed matrix. *J Prosthet Dent* 1994;72:113.
- [4]. Aparicio C. A new method for achieving passive fit for an interim restoration supported by Branemark implant: A technical note. *Int J Oral Maxillofac Implant* 1995;10:614-8.
- [5]. Alfred J. Soletta. A direct technique for fabricating acrylic resin temporary crowns using the Omnivac. *J Prosthet Dent* 1973;29:577-560.
- [6]. Assif D, Himmel R. A technique for improving the marginal fit of temporary acrylic resins crown using injection of self-curing acrylic resin. *Quintessence International* 1986;17:313-315.
- [7]. Amin AE. The effect of poly-aramidefiber reinforcement on the transverse strength of a provisional crown and bridge resin. *Egypt Dent J* 1995;41:1299-304.
- [8]. Amsterdam M. Provisional splinting. Principles and techniques. *Dent Clin North Am* 1959;73-9.
- [9]. Amet EM, Phinney TL. Fixed provisional restorations for extended prosthodontic treatment. *J Oral Implantol* 1995;21 :201-6.
- [10]. Antonoff SJ, Levine Hy. Fabrication on acrylic resin temporary fixed prosthesis for an allergic patient. *J Prosthet Dent* 1981;45:678-9.

Dr J Gandhimathi. "Recent Advances in Provisional Restorations." *IOSR Journal of Dental and Medical Sciences (IOSR-JDMS)*, vol. 18, no. 04, 2019, pp 53-58.