

Importance of MDCT in Evaluation of Pancreatitis

Dr Parveen Chandna¹, Dr Rohtas K Yadav²

Senior Resident¹, Director² Deptt. Of Radio-Diagnosis, Pt.B.D.Sharma Post Graduate Institute Of Medical Sciences , Rohtak, Haryana , India

Corresponding Author: Dr Parveen Chandna

Abstract

Background and Objectives: MDCT is the modality of choice and can be employed for evaluation of both inflammatory and neoplastic conditions of the pancreas. MDCT provides high quality visualization of the parenchymal abnormalities and clearly displays the extrapancreatic spread of disease in inflammatory conditions . MDCT is the modality of choice to correctly image chronic pancreatitis due to better display and viewing of calcifications in more details. To demonstrate usefulness of Toshiba lightning aquilion 16 slice multi detector computerized tomography (MDCT) scan in acute and chronic pancreatitis.

Material And Methods: The study had been carried out in the Department of Radiodiagnosis, PGIMS , Rohtak for a period of 3 months from December 2018 to February 2019. 50 patients were taken into consideration after taking a brief note of properly informed written consent and complete history, thorough clinical examination was done and these patients were subjected to CT scan.

Results: Biliary duct obstruction, Gall stones and alcohol consumption were found to be the most common causative etiological factors in adults. However ,blunt abdominal trauma was a particular cause in pediatric patients.

Conclusion: MDCT has a unique and pioneering role in visualization , detection and firmly establishing calcification, ductal dilatation as well as atrophy of gland especially in chronic pancreatitis. It is considered as the imaging modality of choice in acute pancreatitis which can be further graded as CTSI or MCTSI score which have been found to be equivalent for determining patient's critical condition.

Key words: MDCT (Multidetector computerized tomography), pancreatitis , necrosis, CECT (Contrast enhanced computerized tomography) and calcification

Date of Submission: 04-04-2019

Date of acceptance: 19-04-2019

I. Introduction

MDCT fairly displays the tumor morphology, ductal anatomy, and its relationship to surrounding organs and vascular structures in pancreatic neoplasm. Joint venture of thin-section MDCT with image-processing techniques (multiplanar reconstructions and curved reformations) can furnish qualitative imaging details and can very well depict the pancreatic ductal anatomy. Chronic pancreatitis has been considered as a different entity from acute pancreatitis as a result of which recurrent episodes of acute pancreatitis periodically have a tendency to be converted to chronic pancreatitis. Chronic pancreatitis eventually resulting in atrophy ,irreversible fibrosis and exocrine and endocrine deficiencies of the pancreas which may persist clinically in the form of diabetes and malabsorption as well.5,9,10

MDCT Imaging plays an important role in the diagnosis of acute pancreatitis in clinically suspected patients. Pancreatic calcifications may be parenchymal or ductal in origin. The gland gets atrophied later on.13,15

According to the revised Atlanta classification, contrast enhanced CT is highly important for assessing and staging patients with acute pancreatitis, helping to evaluate complications and corresponding to evoking proper response for treatment depicting that most of the patients with acute pancreatitis need not require contrast enhanced CT imaging.1,2

Furthermore, imaging can be employed to guide and streamline therapeutic interventions. Both CT and MRI are extensively employed and represent the best cross -sectional techniques in accurate management of pancreatitis.

The CT severity index (CTSI) for staging of acute pancreatitis has been considered to take into account the volume of fluid collections and the presence or absence of pancreatic necrosis. The CTSI has a perfect correlation with morbidity and mortality. 3,7

Chronic pancreatitis is an irreversible inflammatory disease of the pancreas converting to fibrosis.

Intermittently ,chronic pancreatitis may give rise to inflammatory pseudomass thus ,producing focal enlargement with fibrosis .4

Contrast-enhanced CT is the modality of choice to detect the presence and extent of pancreatic necrosis as well as peripancreatic inflammation and the presence of fluid collections.^{5,6}

The choice in imaging modality depends on the concrete evidence related to investigation along with clinical symptoms and lab reports. It is pertinent to mention that MRI offers diagnostic capabilities similar to multi-detector computed tomography (MDCT) with added advantage of lack of ionizing radiation and the exquisite soft tissue characterization. However, CECT has also been widely employed modality in the evaluation of acute pancreatitis due to its conventional role in detecting and grading the hazardous disorder.^{4,8}

II. Material And Methods

The study had been carried out in the Department of Radiodiagnosis, PGIMS, Rohtak for a period of 3 months from December 2018 to February 2019. 50 patients were taken into consideration after taking a brief note of properly informed consent and complete history, thorough clinical examination was done and these patients were subjected to CT scan. Both Laboratory findings and USG findings emphasized upon the relevant facts that the patients were prone to pancreatitis. Therefore, Contrast enhanced CT scan was performed later on using 1.5mg/kg of non ionic iodinated contrast media on the patients under study duly administered at a flow rate of 2.5ml/sec in the clinically affected patients with this particular disorder dual phase CT was performed with pancreatic parenchymal phase at 40 sec and portovenous phase at 70 sec in adults whereas single porto venous phase was done in paediatric patients following non contrast scan.

Inclusion Criteria:

- Patients who are diagnosed acute pancreatitis on ultrasonography.
- Patients who are suspected or diagnosed of acute pancreatitis based on clinical and laboratory findings with raised serum amylase & serum lipase.
- Serum Creatinine \leq 1.5 mg/dl.
- Patients who present as acute on chronic pancreatitis.

Exclusion Criteria:

- Patients with renal insufficiency
- Patients allergic to contrast media.
- Pancreatitis due to trauma.
- Serum Creatinine $>$ 1.5 mg/dl
- Congenital pancreatic lesion.
- Pancreatic carcinoma and metastasis.

III. Results

Increased serum amylase level had been observed in majority of cases relating to acute pancreatitis. Dilated main pancreatic duct was found to be in consonance with calcification in pancreatic parenchyma. However, diffuse gland atrophy was slightly less in chronic pancreatitis. Vascular complications, groove pancreatitis, Portal hypertension, fistula and pseudoaneurysm were found to be the least complications of chronic pancreatitis.

Biliary duct obstruction, Gall stones and alcohol consumption were found to be the most common causative etiological factors in adults. However, blunt abdominal trauma was a particular cause in pediatric patients.

Out of 50 patients 40 were diagnosed as patients of acute pancreatitis and only 10 patients suffering from chronic pancreatitis. 5 patients had acute on chronic pancreatitis, so included in both acute and chronic pancreatitis.

Vascular complications, groove pancreatitis, portal hypertension, fistula and pseudoaneurysm were the least noticed findings of chronic pancreatitis on MDCT.

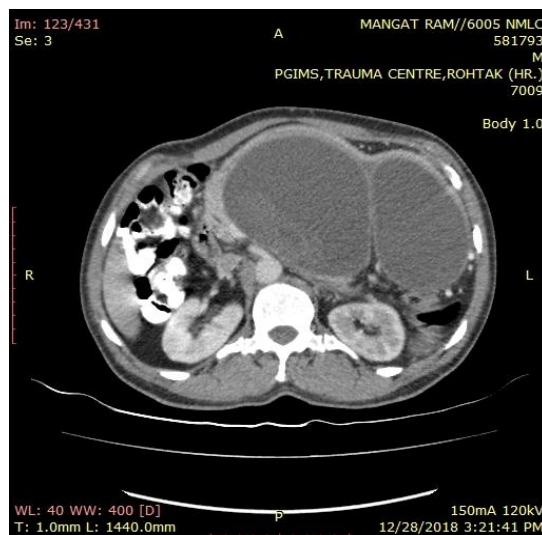
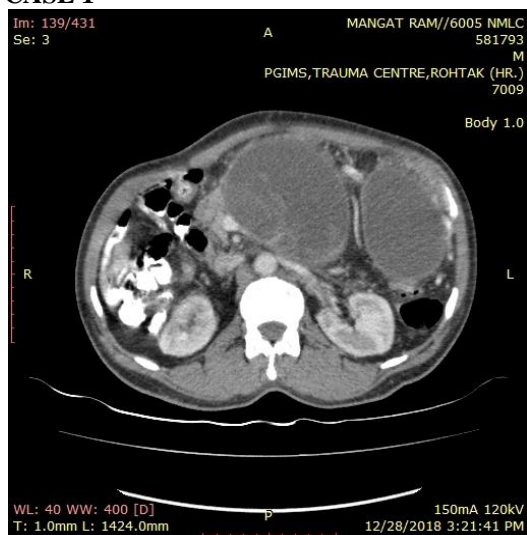
Calcification in pancreatic parenchyma was noticed in 8 patients (80%); Dilated main pancreatic duct was noticed in 8 patients (80%); Diffuse gland atrophy was detected in 7 patients (70%) and Mass formation was noticed in 6 patients (60%).

These were the most prevalent findings especially when compared to other findings as findings were common in most of the patients of chronic pancreatitis on MDCT revealed in the table as under:

MDCT findings in chronic pancreatitis (Total 10 patients)

Imaging findings	No of patients
Vascular complication	1 (10%)
Groove pancreatitis	1 (10%)
Double duct sign (CBD + PANCREATIC DUCT DILATATION)	4 (40%)
Duct penetrating sign	4 (40%)
Portal hypertension	1(10%)
Mass formation	6 (60%)
Acute on chronic pancreatitis	4 (40%)
Free fluid in abdomen	4 (40%)
Diffuse gland atrophy	7 (70%)
Fistula	1(10%)
Pseudoaneurysm	1(10%)
Gastrointestinal tract complication	4 (40%)
Calcification in pancreatic parenchyma	8(80%)
Dilated main pancreatic duct	8(80%)

CASE 1



A. Well defined thick enhancing wall septated hypodense collection noted in lesser sac region f/s/o Pseudocyst of pancreas B. Pancreatic parenchyma could not be appreciated.

CASE 2

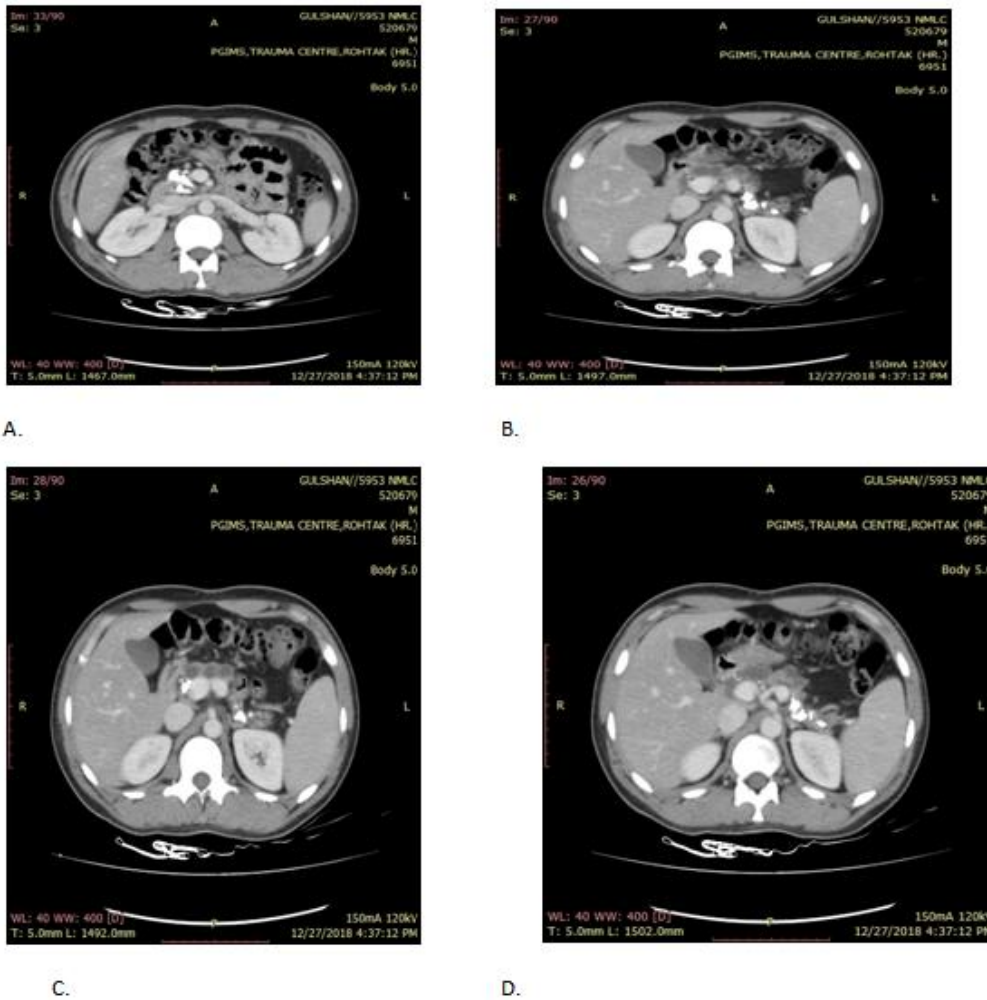


FIGURE 2 CECT (A-D) SEQUELAE OF CHRONIC PANCREATITIS A. Calcification in the head of pancreas. B and C. Dilated main pancreatic duct D. Multiple foci of calcification in tail region .

CASE 3

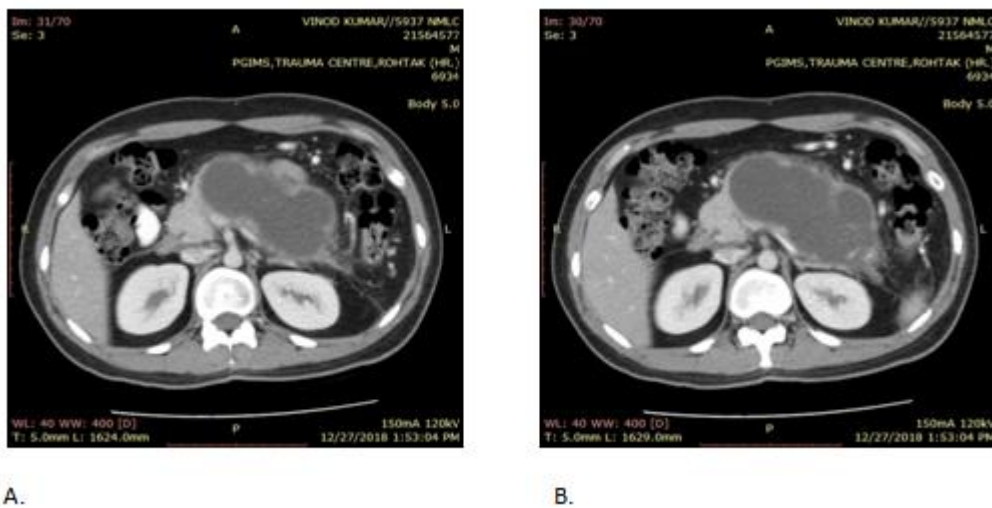
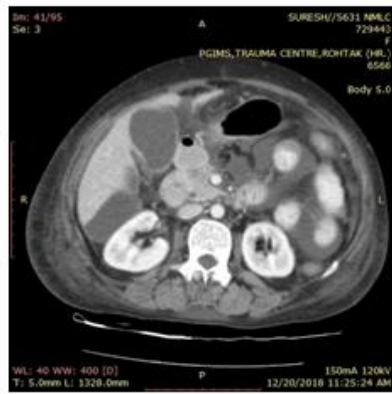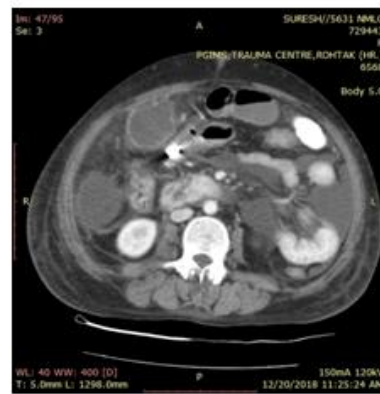


FIGURE 3 CECT (A-B) ACUTE PANCREATITIS WITH PSEUDOCYST FORMATION : A. Thick enhancing wall of the hypodense collection in lesser sac region F/S/O Pseudocyst of pancreas B. Bulky pancreatic head with non visualization of body and tail due to mass affect of pseudocyst.

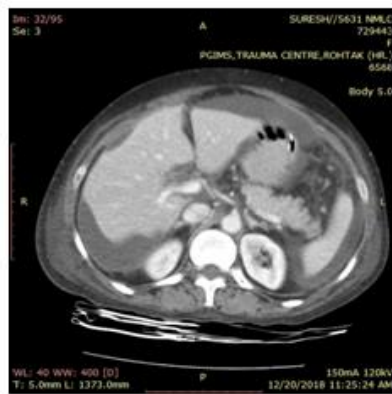CASE 4



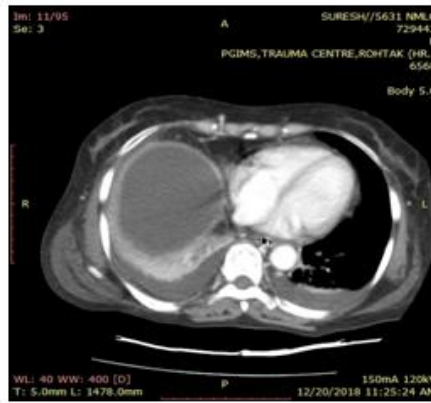A.



B.



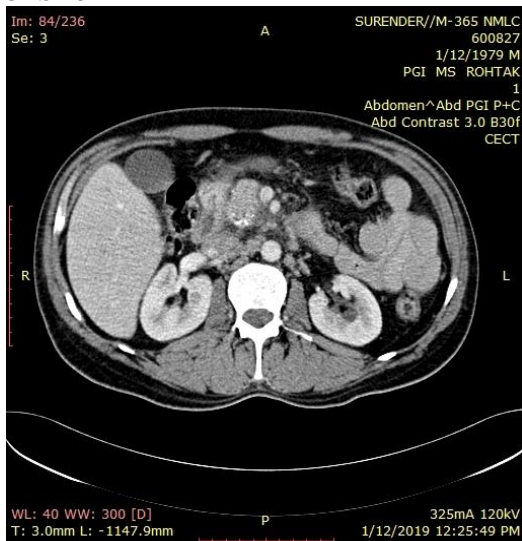
C.



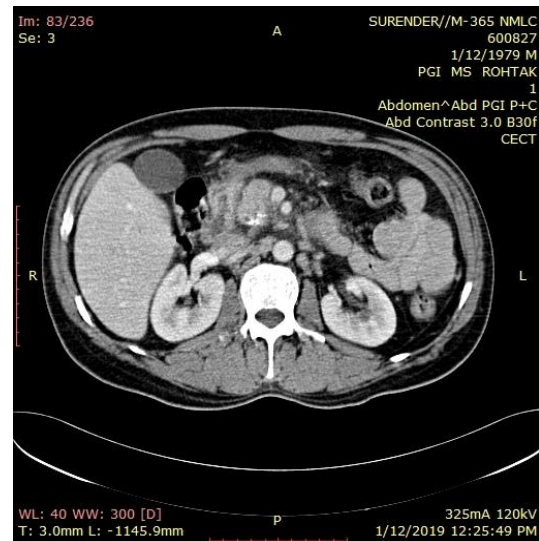
D.

Figure 4 CECT (A-D) K/C/O ACUTE PANCREATITIS: A. Heterogeneous head of pancreas B. Multiple collection in peritoneal cavity. C. Bulky body and tail of pancreas. Fluid collection in the subcapsular region. D. Bilateral pleural effusion

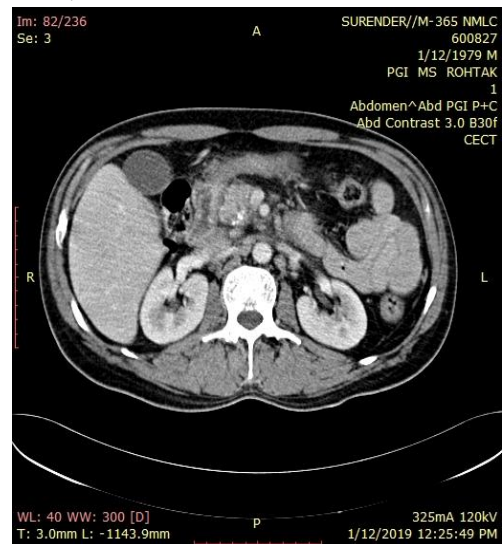
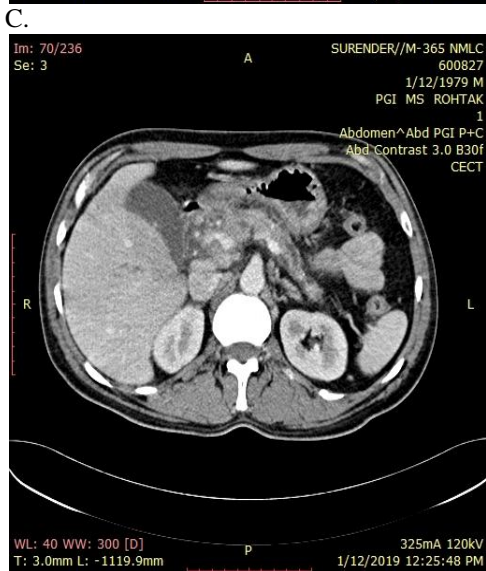
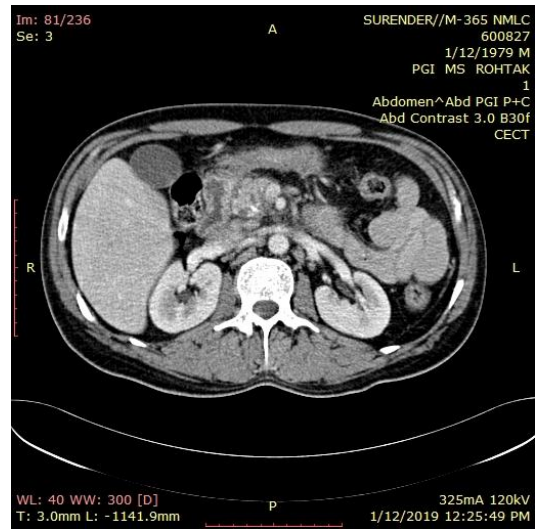
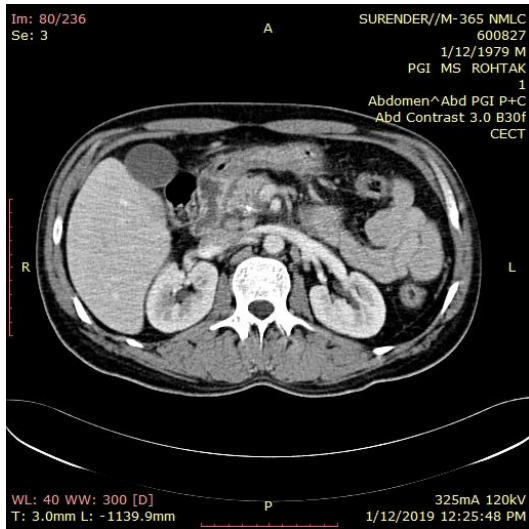
CASE 5



A.

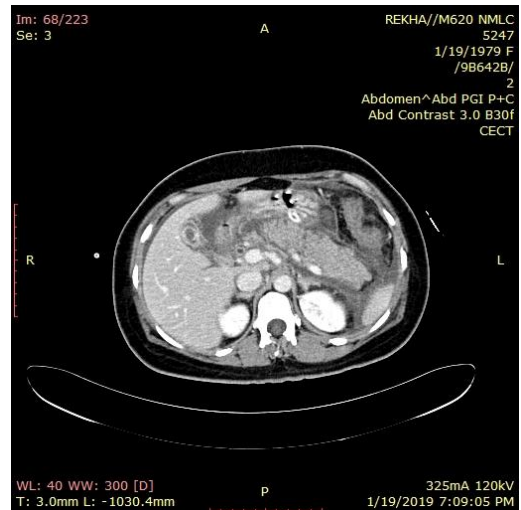
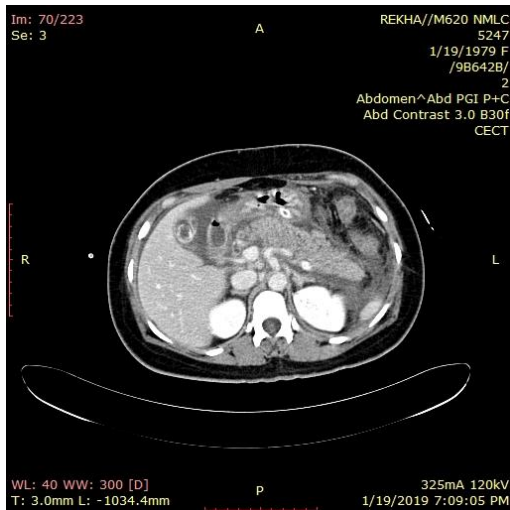


B.

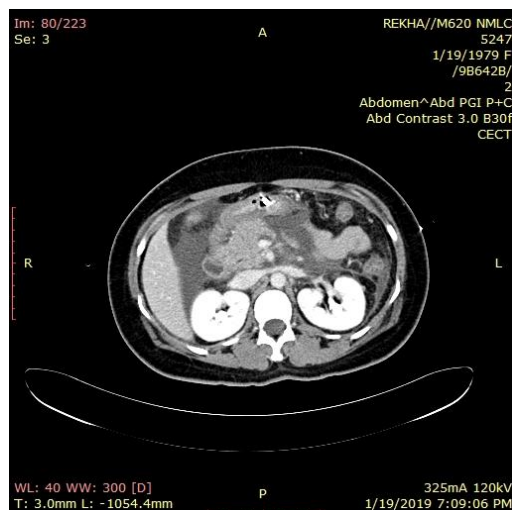
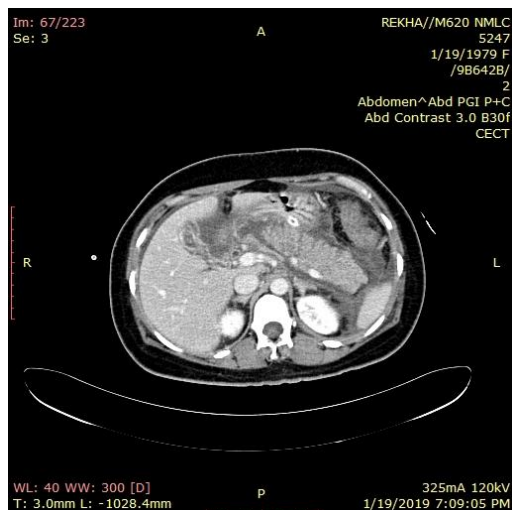


E. **F.**
FIGURE 5 CECT (A-F) ACUTE ON CHRONIC PANCREATITIS : Pancreatic head appears bulky with surrounding peripancreatic fat stranding noted. Foci of calcification noted in relation to head of pancreas with body and tail portion appears atrophied, Main pancreatic duct dilated (measuring 3.3 mm)

CASE 6

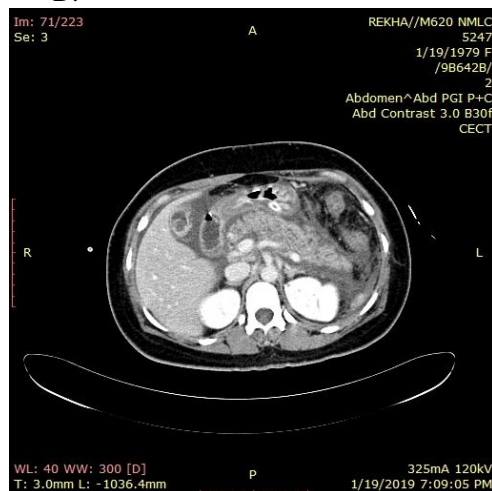
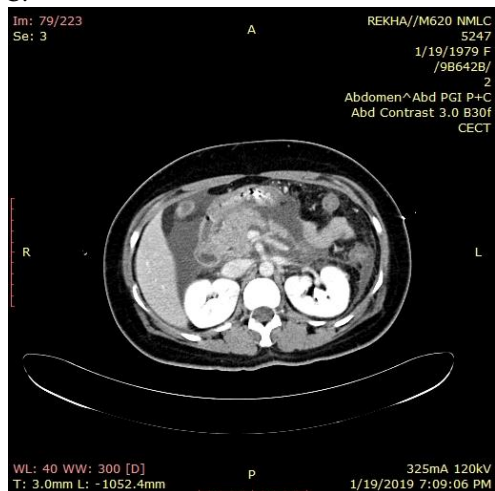


A. **B.**



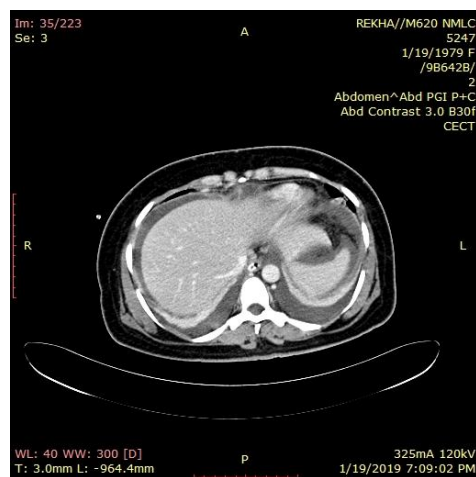
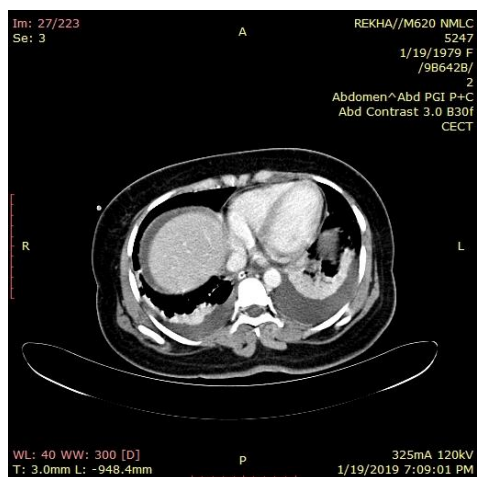
C.

D.



E.

F.

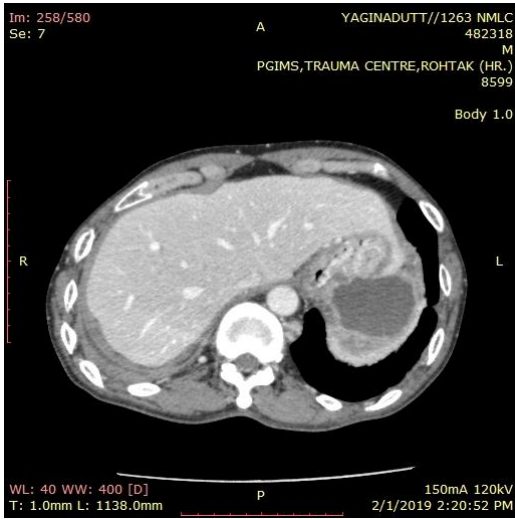


G.

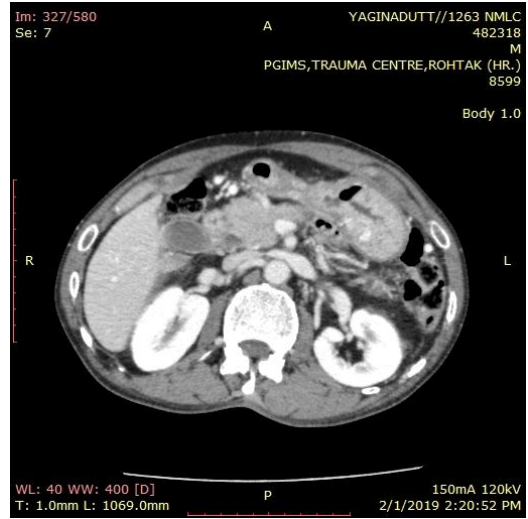
H.

FIGURE 6 CECT (A-F) K/C/O ACUTE PANCREATITIS: (A-F) Pancreas is diffusely bulky in the head, body and tail of pancreas with non-enhancing hypodensities in body region. Multiple collection in peritoneal cavity f/s/o acute necrotizing pancreatitis (G-H) Bilateral pleural effusion

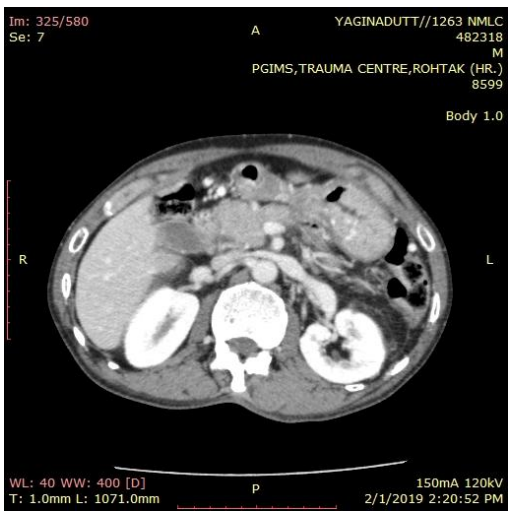
CASE 7



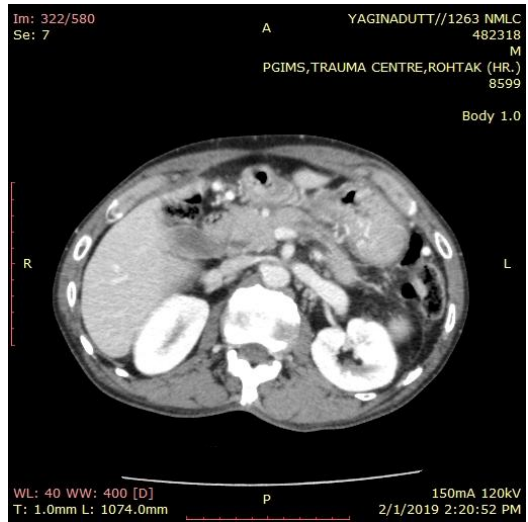
A.



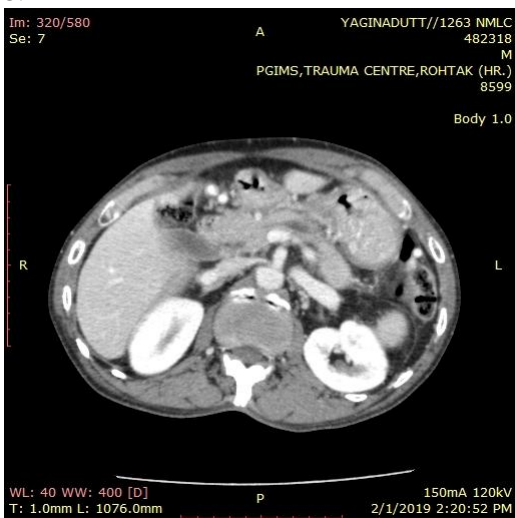
B.



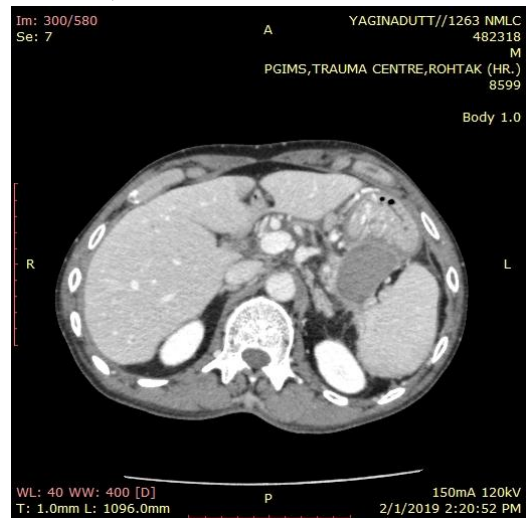
C.



D.



E.



F.

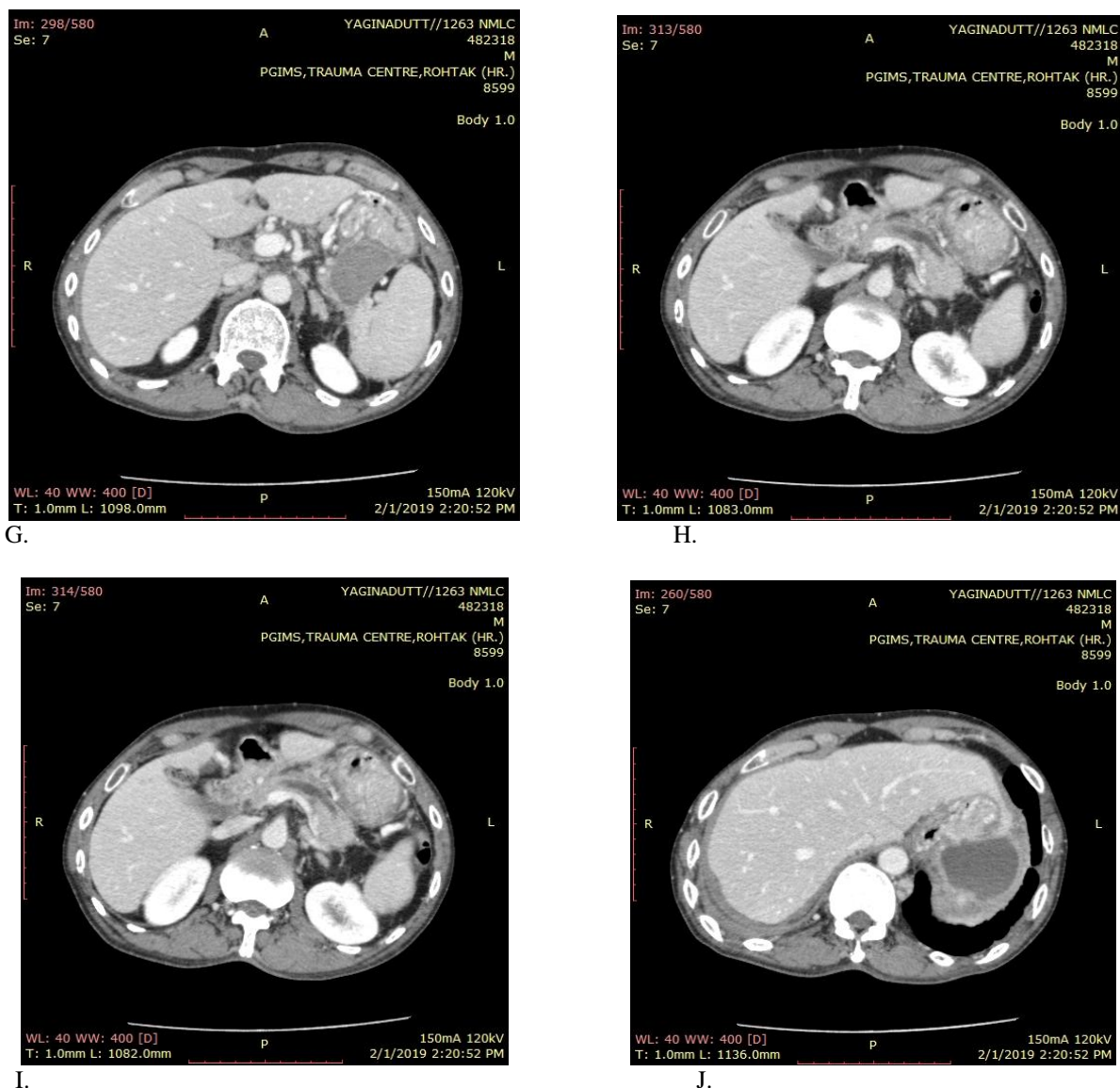


FIGURE 7 CECT (A-J) ACUTE ON CHRONIC PANCREATITIS WITH WON FORMATION
 :Pancreas is mildly bulky and dilated main pancreatic duct in body and tail region. Multiloculated walled off collections noted in pancreatic tail region. Collection with peripherally enhancing wall noted in left sub diaphragmatic region.

IV. Discussion

MDCT Imaging has a key role in determining parenchymal and ductal disorders in chronic pancreatitis and lead to early differentiation from advanced phases to a extreme extent; which further necessitates the treatment as well as management of the patients.1,4

Consequently imaging plays a significant role in the diagnosis and staging of acute and chronic pancreatitis. It is of immense use in grading the severity of the disease and confirming pancreatic or peripancreatic complications. 8,12,15

Availability of MDCT in every nook and corner of the world associated with distinct image quality makes MDCT the most preferred imaging technique. It assists to determine the causes of pancreatitis: biliary duct obstruction ,gallstones or structural abnormalities. Pancreatic ductal dilatation with a beaded appearance is a unique characteristic in chronic pancreatitis.10,11

In many cases concrete and relevant diagnosis of the patients with a remarked history of heavy intake of liquor, upper abdominal pain and hyper amylasemia or enhanced plasma lipase revealed significant alterations in the pancreatic gland . In 2008, an international group of experts in the field of pancreatitis, led by the Acute Pancreatitis Classification Group concluded and confirmed iterative web-based consultation . This practice was further headed by a group of experts undergoing this particular assignment and looking upon the

real facts further revised the Atlanta classification system with an effort to improve clinical diagnosis and management of acute pancreatitis.¹⁴

V. conclusion

MDCT has a unique and pioneering role in visualization, detection and firmly establishing calcification, ductal dilatation as well as atrophy of gland especially in chronic pancreatitis. It is considered as the imaging modality of choice in acute pancreatitis which can be further graded as CTSI or MCTSI score which have been found to be equivalent for determining patient's critical condition.

Perfection can be achieved based on concrete findings of CT scan on the patients with acute pancreatitis which remarkably present as an acute condition associated with abdominal pain and enhanced pancreatic enzymes level in the blood and urine. Gravity and severity of the disease reveal peripancreatic inflammation, pancreatic edema and fluid collections. Individual laboratory index is preferable marker of pancreatic injury and of inflammatory responses. However, promising results have not yet been obtained ascertaining clinical acceptance.

Acknowledgement

No words can ever express my deep sense of gratitude for my parents & my younger brother, for their affections, endurance, inspiration, support, unending blessings, innumerable sacrifices and unceasing encouragement that has moulded me into the person I am today. The expression of my gratitude's will remain incomplete if I fail to register my deep sense of indebtedness to my family members without whose perseverance and affection it would have not been possible for me to undertake this arduous assignment.

Funding : No funding sources.

Conflict of interest: None declared.

Ethical approval: The study was approved by the Institutional Ethics Committee.

Bibliography

- [1]. Wolfgang Schima. E. Jane Adam, Robert A. Morgan. The pancreas Chapter -33, In: Grainger and Allison's Diagnostic Radiology – A text book of medical imaging. Andreas Adam, Adrian K. Dixon, Jonathan H. Gillard, Cornelia M. Schaefer-Prokop ed. 6th ed., Elsevier; 2015 .p.806-813.
- [2]. Andreas Adam, Adrian K. Dixon, R.G. Grainger, DJ Allison. Edt. Pancreas. Chapter 3.8, In : Grainger and Allison's Diagnostic Radiology Essentials. Elsevier; 2013 .p.372.
- [3]. Balthazar EJ, Robinson DL, Megibow AJ, Ransson JH. Acute pancreatitis: Value of CT in establishing prognosis. *Radiology*. 1990;174:331-336.
- [4]. Balthazar EJ. Acute pancreatitis: Assessment of severity with clinical and CT Evaluation. *Radiology*.2002;223:603-613.
- [5]. Manfredi R, Brizi MG, Canade A, Vecchioli A, Marano P. Imaging of acute pancreatitis. *Rays*.2001;26:135-42.
- [6]. Morteale KJ, Zou KH, Banks PA, Silverman SG. A modified CT severity index for evaluating acute pancreatitis: improved correlation with patient outcome. *Pancreas*. 2004;29(4):363.
- [7]. Shyu JY, Sainani NI, Sahni VA, Chick JF, Chauhan NR, Conwell DL, et al. Necrotizing pancreatitis: diagnosis, imaging, and intervention. *Radiographics*. 2014;34(5):1218-39.
- [8]. Bollen TL, Singh VK, Maurer R, Repas K, van Es HW, Banks PA, Morteale KJ. Comparative evaluation of the modified CT severity index and CT severity index in assessing severity of acute pancreatitis. *AJR Am J Roentgenol*.2011 Aug; 197(2):386-92.
- [9]. Koo BC, Chinogureyi A, Shaw AS. Imaging acute pancreatitis. *Br J Radiol*.2010 Feb; 83(986):104-12.
- [10]. Casas JD, Diaz R, Valderas G, Mariscal A, Cuadras P. Prognostic value of in the early assessment of patients with acute pancreatitis. *AJR Am J Roentgenol*. 2004 Mar; 182(3): 569-74.
- [11]. Chishty IA, Bari V, Pasha S, Burhan D, Haider Z, Rafique Z. Role of Computed tomography in acute pancreatitis and its complications among age groups. *Pak Med Assoc*. 2005 Oct;55(10):431-5.
- [12]. Chaudhary V, Bano S. Imaging of Pancreas: Recent advances. *Indian J Endocr Metab* 2011; 15:S25-32.
- [13]. Chopra S ,P.Joshi , S K Kochhar, G Balarangaiah “ Pictorial assay:CT spectrum of pancreatitis -- an overview” *Ind J RadiolImag* 1997;7(2):91-96.
- [14]. Lawson T. L “ Acute Pancreatitis and its complications – CT and Sonography” *Radio Clin N Am* 1983;21(3):495-513.
- [15]. Raifat Masud , Akhtar Waheed , Aurangzeb , Fakhar Ilyas Malik , Atif Mian “ Role of radiology in pancreatic disorder” 2009.

Dr Parveen Chandna. “Importance of MDCT in Evaluation of Pancreatitis.” *IOSR Journal of Dental and Medical Sciences (IOSR-JDMS)*, vol. 18, no. 04, 2019, pp 74-83.