

Comparative Growth of the Upper and Lower Limb In the Fetal Period

Dr. Yanglem Elizabeth Devi¹, Prof. N. Damayanti Devi²

¹(Department of Anatomy, Regional Institute of Medical Sciences, Manipur, India)

²(Department of Anatomy, Regional Institute of Medical Sciences, Manipur, India)

Corresponding Author: Dr. Yanglem Elizabeth Devi

Abstract: Intrauterine growth of the fetus is mainly due to the growth and lengthening of the two limbs; Forelimb and Hindlimb. Each limb has a segment; proximal and distal segment with hand and foot being the most extreme part.

This study is the re – evaluation of the relative growth of these components in fetus of different age periods. Forty fetuses of different age periods from 13 weeks to term were collected, length of these segments of upper and lower limbs measured. In adults, length of lower limb is more than that of upper limb. In our study, length of upper limb similar to that of lower limb in early fetal period.

Date of Submission: 07-04-2019

Date of acceptance: 22-04-2019

I. Introduction

The upper limb of humans is built for prehension. The hand is a grasping mechanism, with four fingers flexing against an opposed thumb. The hand is furthermore the main tactile organ, with a rich nerve supply. In grasping, the thumb is equal in functional value to other four fingers, loss of the thumb is as disabling as loss of all four fingers. In order to be able to grasp in any position the forearm is provided with a range of about 140° of pronation and supination, and at the elbow has a range of flexion and extension of like amount. The human lower limb is built for support and propulsion.¹

The limbs develop via a continued series of complex epithelial /mesenchymal interactions initiated in the lateral body walls. The proliferating somatopleuric mesenchyme forms a ridge externally, ventrolateral to the somites, which extends caudally from the sixth pharyngeal arch.² At the end of the fourth week of development, limb buds become visible as outpocketings from the ventrolateral body wall. The forelimb appears first followed by the hind limb 1 to 2 days later. Initially, the limb buds consists of a mesenchymal core derived from the parietal (somatic) layer of lateral plate mesoderm that will form the bones and connective tissues of the limbs, covered by a cuboidal ectoderm.³

The upper limb buds are visible by day 26 or 27, and the lower limb buds appear 1 or 2 days later. The upper limb buds develop opposite the caudal cervical segments, and the lower limb buds form opposite the lumbar and upper sacral segments. Although there is extensive literature on embryogenesis of early weeks of fetus, there is only few literatures regarding the development in later stages of fetal life. Measurement of limb length especially length of femur is an important tool for estimation of gestational age as well as for early diagnosis of any congenital malformation. As a result this study was done to observe the changes in the lengths of upper and lower limb during later weeks of fetal life.

II. Materials And Methods

This study was conducted in the Department of Anatomy, Regional Institute of Medical Sciences, Imphal for two years i.e from 2011 to 2012 after taking permission from the Ethical Committee of the Institute. To study the comparative growth of these components, forty fetuses of different age periods from 13 weeks to full term without any gross congenital anomaly were collected from the Department of Obstetrics and Gynaecology, Regional Institute of Medical Sciences, Imphal. Fetuses were products of Medical Termination of Pregnancy Act, 1971. They were preserved in 10% formalin immediately after abortion. Gestational ages were calculated using crown rump length, obstetrical history and gross physical examination. Lengths of upper and lower limbs were measured using measuring tape and calipers. Length of upper limb was measured from the tip of acromion to the styloid process of radius and lower limb length was measured from anterior superior iliac spine to the medial malleolus. These measurements of each individual limb were presented in tabular form as well plotted against gestational age for analysis of the result.

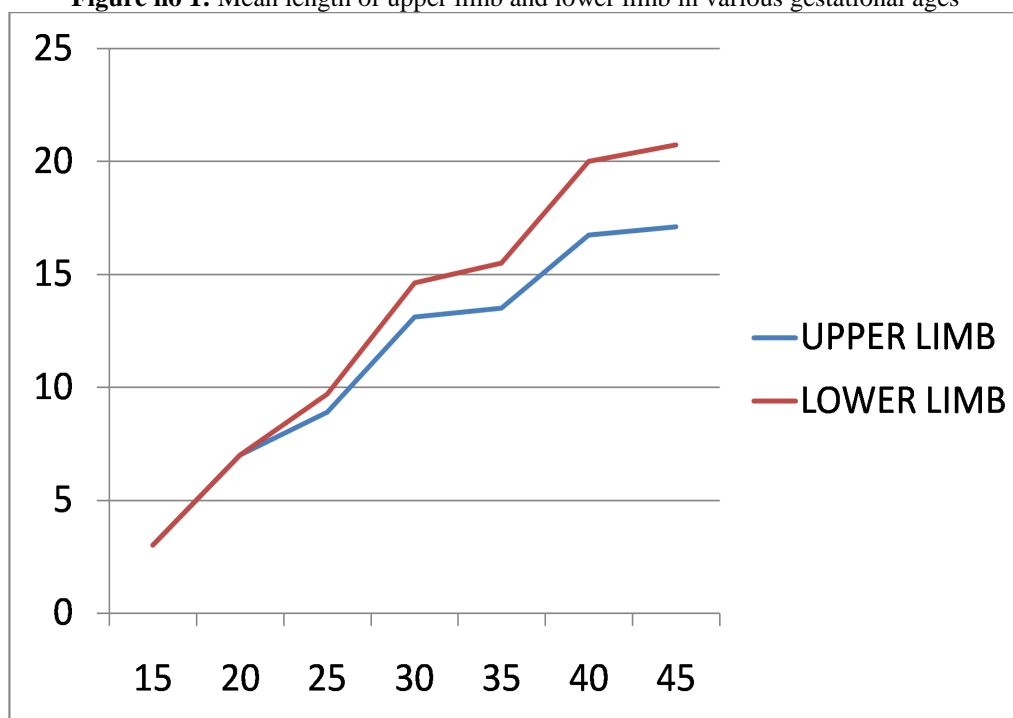
III. Result And Observation

There was progressive increase in the length of both upper and lower limbs with increase in the gestational age. This increase in length was most marked during 25 to 30 weeks of gestational age and again during 35 to 40 weeks of gestational age. But during early fetal weeks (15 to 20 weeks), lengths of upper and lower limb are almost similar. The difference between the length of upper and lower limb become pronounced as the fetus reached 25 to 30 weeks.

Table no. 1: Mean lengths of upper and lower limb in various gestational weeks

Gestational age (in weeks)	Mean upper limb length (cm)	Mean lower limb length (cm)
10-15	3.0	3.0
15-20	7.0	7.0
20-25	8.9	9.70
25-30	13.12	14.62
30-35	13.5	15.5
35-40	16.75	20.0
40-45	17.12	20.74

Figure no 1: Mean length of upper limb and lower limb in various gestational ages



X AXIS - GESTATIONAL AGE IN WEEKS

Y AXIS - MEAN LENGTH IN CM

IV. Discussion And Conclusion

There is significant difference between the lengths of upper limb and lower limb in adults where the ratio of the lengths of lower limb to upper limb is around 1:0.65 while it is almost similar during early fetal life. The differences become pronounced as the fetus reached 25 to 30 weeks.

By the end of 12th week, upper limbs reached their final relative length but the lower limbs have not.⁵ Early fetal development is characterized by accelerated growth of the upper limbs, while postnatal growth is characterized by accelerated growth of lower limbs.⁶

References

- [1]. Sinnatamby CS. Last's Anatomy – regional and applied. 11th ed. Edinburgh: Churchill Livingstone; 2006.
- [2]. Collins P. Embryology and Development. In: Williams, Bannister, Berry, Collins, Dyson, Dussek, et al, editors. Gray's Anatomy. 38thed. New York: Churchill Livingstone; 1995.
- [3]. Sadler TW. Langman's Medical Embryology. 10th ed. Philadelphia: Lippincott Williams and Wilkins; 2006.
- [4]. Moore KL, PersaudTVN. The Developing Human. 8th ed. Philadelphia: Saunders Elsevier; 2008.
- [5]. Embryology Lecture Notes – IU School of Medicine – Terre Haute. Available from: terrehaute.medicine.iu.edu/index.php/download-file/view/24/ Accessed date:14-01-13.
- [6]. Khan Z, Faruqi NA. Determination of Gestational Age of Human FoetusesFromDiaphysial Lengths of Long Bones – A Radiological Study J AnatSoc India 2006; 55(1): 67-71.

Dr.Yanglem Elizabeth Devi. "Comparative Growth of The Upper and Lower Limb In The Fetal Period." IOSR Journal of Dental and Medical Sciences (IOSR-JDMS), vol. 18, no. 04, 2019, pp 23-25.