

Efficacy of Injection Histoglob in Treatment of Chronic Urticaria-A Prospective Study.

Dr.Surya mangadevi. Thota¹

¹ post graduate student, Department of DVL, Siddhartha medical college, Vijayawada, A.P, India.

Corresponding Author: Dr.T.V.Narasimha Rao,

Professor and HOD, Department of DVL,SMC,Vijayawada.A.P,India.

Abstract: Objectives: To assess the efficacy of injection Histoglob in treatment of chronic urticaria.

Materials and methods: Thirty five patients with chronic urticaria(CU) were enrolled into this prospective clinical study. Injection histoglob was given as a weekly dose of 1ml subcutaneously for 8 consecutive weeks.Tab Levocetrizine 5mg was permitted as and required not exceeding the recommended permitted dose. The efficacy of the drug was assessed using urticaria activity score(UAS) which has a maximum score of 6/day. The assessment was done at every weekly visit and at 24th week which was the final assessment.

Results: Out of thirty five patients enrolled ,twenty six patients had completed the entire schedule of dosage of 8 weeks and final follow-up at 24th week. The mean basal UAS was 5.1 at the time of enrollment to the study and it reduced to 1.01 with a reduction of 80.2%.At the end of 24 weeks 17 patients out of 35 (48.5%) attained complete remission .There was also a remarkable drop in the usage of antihistaminics. No adverse effects were observed in the study group.

Conclusion: Histagloblin was found to be effective in producing long-term remission and it reduced the antihistamine requirement as well. Thus, it can serve as an effective alternative to existing treatment modalities.

Keywords: Anti-histamines, chronic urticaria, injection histoglob, urticaria activity score.

Date of Submission: 25-02-2019

Date of acceptance:11-03-2019

I. Introduction

Chronic urticaria (CU) is defined as urticaria persisting daily or almost daily for more than 6 weeks.[1] The exact prevalence of CU is unknown. About 0.1–3% of the population are affected by this condition.[2]

Various therapeutic options are available for the treatment of CU. First in the treatment ladder are non-sedative antihistamines, which are initially started at a low dose. Escalation of the dosage of these agents and adding a leukotriene antagonist are the next strategies in the management. The use of immunomodulators such as cyclosporin, methotrexate, omalizumab, and dapsone is the last resort in treating this condition.[3]

Ordinary CU has a fluctuating course and often a poor response to drug treatment. It can be challenging to determine the appropriate medication to suit the patient. The need for long-term and daily intake of these agents leads to frustration and non-compliance. Treatment options which increase the duration of remission and those which address the key factors involved in the disease pathogenesis are the need of the hour. In this context, we assessed the effectiveness of injection histoglob, a complex of histamine and human immunoglobulin, in producing relief in patients with CU.

II. Materials and Method

This prospective clinical study was carried out in the DVL out-patient department in our institute from April 2017 to July 2018 after obtaining the approval from the college Ethics Committee.

Patient Selection:

Chronic spontaneous urticaria was diagnosed if the patient had a history of daily or almost daily occurrence of widespread, itchy, spontaneous wheals for a period of 6 weeks or more, with individual lesions lasting <24 h. Patients younger than 18 years, pregnant and lactating mothers, patients on long-term immunosuppressants for CU, and those with any other co-morbidity were excluded from the study. Possible physical urticaria such as cold-induced, pressure, heat-contact, solar, dermographic, vibratory, aquagenic, cholinergic, and drug-induced urticaria were excluded from the study.

Sample Size

35 patients were enrolled in the study depending on the symptoms of chronic urticaria and the urticaria activity score (UAS) was calculated based on the Godse KV. Urticaria meter[4].

Baseline Evaluation

Informed consent was obtained from the patients and baseline evaluation was done. This comprised a detailed history regarding the duration, severity, diurnal variation of lesions, any systemic co-morbidities, such as thyroid disorders, diabetes mellitus, or hypertension, and any concomitant drug use by the patient, and a history suggestive of any physical form of urticaria or urticarial vasculitis. Female patients' status on pregnancy or lactation was also noted. This was followed by a clinical examination of the patient. The baseline UAS was calculated, and the number and type of oral antihistamine the patient was taking in the past week were noted. Routine investigations such as complete blood count with differential count, urine routine examination, stool examination for ova and cysts, thyroid profile, and renal and liver function tests, were done for subjects. An autologous serum skin test (ASST) was then performed as per the standard procedure,[5] accordingly patients were divided into subgroups as ASST +ve patients and ASST -ve patients.

Treatment Schedule and Follow-up

Histoglob:

The patients were administered a subcutaneous injection of 1 ml histoglob (HISTOGLOB[®] manufactured by Bharat Serums and Vaccines Ltd, Maharashtra, India), which is a combination of human normal immunoglobulin (12 mg) and histamine dihydrochloride (0.15 mcg).[6] The recruited patients were administered 1 ml of histoglob subcutaneously over the arm, weekly for 8 consecutive weeks. Patients were also prescribed rescue medication (tablet levocetirizine 5 mg) to be taken when required, not exceeding the permitted daily dosage. During each weekly visit, the response to treatment was assessed using UAS. The number of rescue medications taken in the past week was also noted. Final assessment was done at 24th week of starting the therapy.

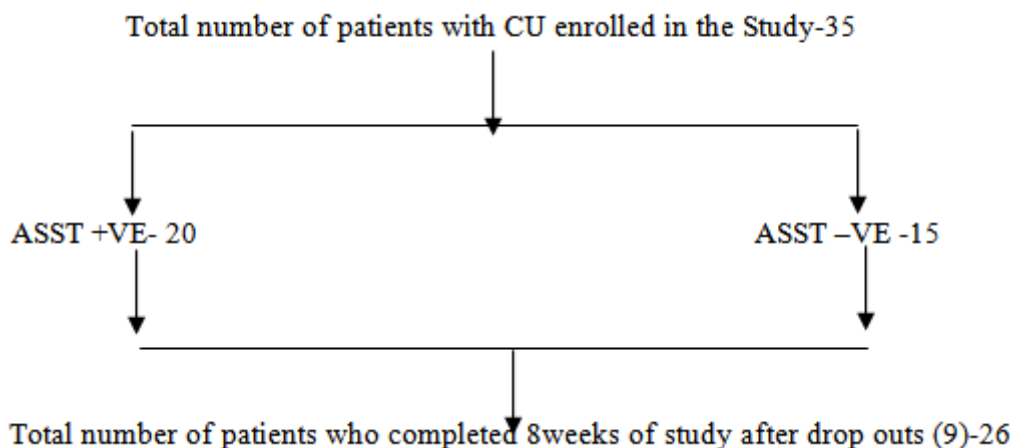
Urticaria activity score

The UAS used by Godse KV et al was used, which assessed the severity of urticaria.[4] It measures two symptoms-number of wheals and intensity of itching-each on a 0-3 scale each day. Wheals measured:0-none,1-mild(<20/24hrs),2-moderate(20-50/24hr),3-intense(>50/24hr or large confluent areas of wheals);severity of itch was scored :0-none,1-mild, 2-moderate, and 3-severe. The sum of the scores was calculated and the maximum score would be 6/day. Each patient was provided with an urticaria daily sheet. Patients were instructed to make entries on a daily basis to be reviewed at each weekly visit. The UAS was assessed weekly and subcutaneous injection procedure was repeated for a period of 8 weeks. At the end of 8 weeks of therapy, patients were instructed to review in the OPD if symptoms reappear. The patient was reviewed again at 24th week. Usage of anti-histamine was also noted.

III. Results

Study Population

35 patients were included in the study. Of them, 26 patients completed the stipulated 8 weeks of treatment. 9 out of 35 patients dropped out from the study in the course of the study due to unknown reasons.[Figure 1].



Among 35 patients enrolled, 25 were female and 10 were male (male: female = 1:2.5). The mean age of patients was 32.6years. Mean duration of the disease was 16.7 months. Basal ASST was negative in 15 patients (42.8%) and positive in 20 patients (57.2%). The mean basal UAS recorded at the time of screening visit was 5.1. The baseline UAS was higher among the ASST-positive patients (5.4) when compared to ASST-negative patients (4.8).Mean number of antihistamines taken per week by patients at baseline evaluation was 7.8 [Table 1].

Table 1

Baseline demographic and clinical characteristics of the subjects

| <u>Characteristic</u> | <u>Baseline Value</u> |
|--|-----------------------|
| Mean age (years) | 32.6 |
| Female:Male | 2.5:01 |
| Mean duration of Urticaria | 16.7 Months |
| ASST +Ve | 20 |
| ASST -Ve | 15 |
| Mean baseline UAS | 5.1 |
| Mean number of antihistamines taken per week | 7.8 |
| Dropouts | 9 |

Efficacy:

Urticaria activity score

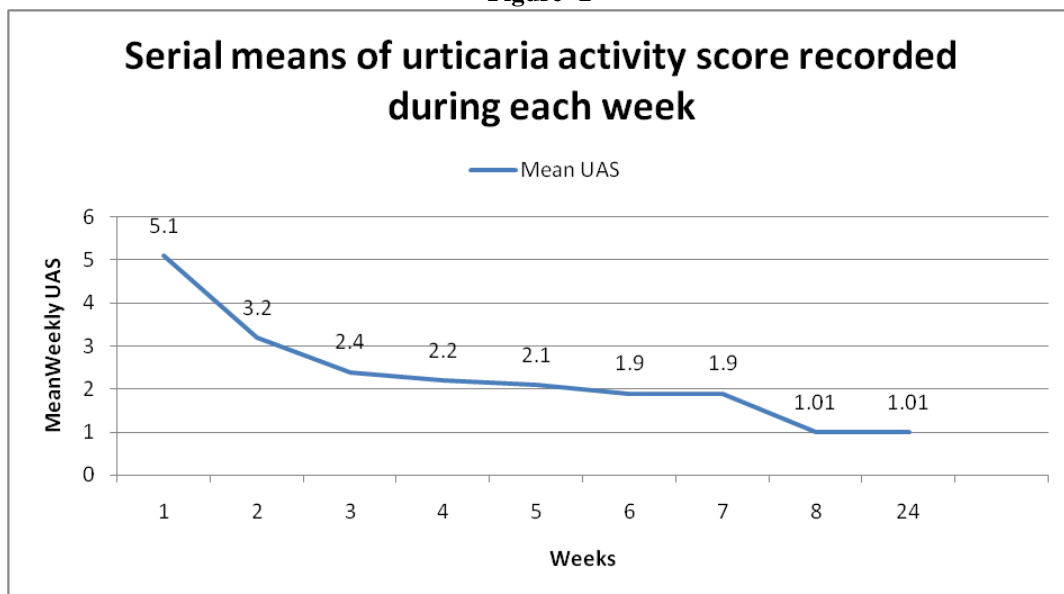
Mean UAS value reduced from 5.1 to 1.01 (80.2% reduction) by 8 weeks. By 24 weeks of starting the therapy, 17 patients (46.2%) had attained complete remission out of 35 patients.

Table 2

Weekly reduction in urticaria activity score during the study period

| <u>UAS</u> | <u>Mean</u> | <u>Number of patients</u> |
|------------------------------|-------------|---------------------------|
| UAS at 1 st Week | 5.1 | 35 |
| UAS at 2 nd Week | 3.2 | 35 |
| UAS at 3 rd Week | 2.4 | 32 |
| UAS at 4 th Week | 2.2 | 31 |
| UAS at 5 th Week | 2.1 | 28 |
| UAS at 6 th Week | 1.9 | 28 |
| UAS at 7 th Week | 1.9 | 26 |
| UAS at 8 th Week | 1.01 | 26 |
| UAS at 24 th Week | 1.01 | 26 |

Figure -2



Among ASST-positive patients, the mean UAS reduced from 5.4 to 1.02 (81.11% reduction) and among ASST-negative patients, it reduced from 4.8 to 1 (79.16% reduction). The difference in response between these two groups was not statistically significant. The mean number of antihistamine tablets required per week reduced from 7.8 at the start to 1.5 after 8 weeks ($P < 0.001$). At 24 weeks, 17 patients were completely off from antihistamines. The summary of all end points is given in [Table 3](#).

Table 3

Summary of end points

| <i>Treatment end point</i> | <i>Before treatment</i> | <i>After treatment</i> | <i>% Reduction</i> | <i>pValue</i> |
|----------------------------|-------------------------|------------------------|--------------------|---------------|
| Mean UAS | 5.1 | 1.01 | 80.2 | <0.001 |
| UAS in ASST +Ve | 5.4 | 1.02 | 81.1 | <0.001 |
| UAS in ASST –Ve | 4.8 | 1.00 | 79.2 | <0.001 |
| Rescue Medication | 7.8 | 1.50 | 80.8 | <0.001 |

None of the patients reported any adverse effect either during or after the treatment.

IV. Discussion

CU is a perennial health problem that affects the quality of life of patients. Non sedating antihistamines remain the main stay of treatment of CU.[3,7,8,9] Although it provides immediate relief from symptoms, it does not alter the immunopathogenesis or the natural course of the disease. There remains a challenge to find a drug which provides long-term benefit by acting on early steps in the immunological cascade, thereby preventing the attacks of urticaria.

Various immunological agents that are being used are oral corticosteroids, cyclosporine, methotrexate, intravenous immunoglobulin, omalizumab, tacrolimus, etc., Studies supporting the use of these drugs are limited, and the side effect profile of all these drugs is also not favourable.[8]

Immunotherapies such as allergen-specific immunotherapy, autologous serum therapy, and autologous whole blood therapy have also been used with moderate success. Generation of anti-idiotypic antibodies to various mast cell degranulating agents has been proposed as the mechanism of action of immunotherapy.[4,10,11]

In this study, histoglob, a sterile preparation of histamine dihydrochloride coupled to active protein fraction extracted from human blood (gamma globulin) in strictly defined proportions was used. Gamma globulin used in HISTOGLOB® is tested negative for hepatitis b surface antigen, HIV-1, 2 antibodies, and hepatitis C virus-ribonucleic acid by polymerase chain reaction as declared by the manufacturer.[6]

The exact mechanism of action of histaglobulin is poorly understood. Histaglobulin is capable of eliciting an immunological response with the production of highly potent antihistaminic antibodies. The anti-histamine antibodies formed will neutralize the released histamine and eliminate urticaria effectively. Repeated doses of histaglobulin increase the antibody titer, for which it is recommended to administer doses every 6 months to maintain optimal titer of antibody.[6,12] Patients may have to take 6 monthly injections till complete clinical remission is achieved. requirement of such doses. Histoglobulin act preferentially by suppressing eosinophil chemotaxis, by inducing apoptosis of eosinophils, by selectively inhibiting late antigen-4, vascular cell adhesion molecule, or both, and by suppressing maturation of eosinophils in bone marrow.[13]

Histaglobulin has been widely used in the treatment of allergic rhinitis. It is also used in various allergic disorders such as asthma, atopic dermatitis, CU, erythema multiforme, and cutaneous drug allergy.[14] There is a lack of well-designed studies on its efficacy in CU. Gushchin *et al.* reported positive results among forty patients with CU after administering six subcutaneous injections of histaglobulin.[15]

The role of corticosteroids in CU is limited. However, for acute exacerbation of chronic spontaneous urticaria, a short course of corticosteroids (3–7 days) was found to be helpful.[7,8,16] As per the recent European Academy of Allergy and Clinical Immunology (EACCI) guidelines, the strength of recommendation for steroids is weak. It is also limited by various dose- and time-dependent side effects.[9]

Cyclosporin has a better risk-benefit ratio compared to steroids. It is recommended only for patients with severe disease refractory to any dose of antihistamines.[9] Various studies have established the effectiveness of low-dose cyclosporin.[17] Yet its serious side effects (nephrotoxicity and hypertension) and the requirement to monitor the blood pressure, renal function, and electrolytes precludes its use as the standard treatment for CU.[7]

Efficacy and tolerance of omalizumab have been well demonstrated in various randomized control trials (RCTs).[18] One such trial conducted by Maurer *et al.* demonstrated good efficacy at monthly doses of 150 mg and 300 mg over a 12-week period with low toxicity.[19] However, the quality of evidence is very low and the strength of recommendation for this drug is also weak, as per the EACCI guidelines.[9]

There are no RCTs published on the usage of methotrexate. A retrospective analysis conducted by Perez *et al.* concluded that it can be used in chronic steroid-dependent urticaria and should be considered as an alternative to other third-line drugs, such as cyclosporin.[20]

There are two studies from India which demonstrated the efficacy of autologous serum therapy in reducing the severity of urticaria and the number of antihistamines required.[10,21] Another study by Majid *et al.* did not show favorable results.[22] Table 4 compares the effectiveness of various immunological agents from various studies.

Summary of features of other drugs from various studies in comparison with the present study

| Study | Intervention | Duration of Treatment | Treatment Response | Follow-up Duration (weeks) | Side effects |
|---------------------------------|---|------------------------|--|----------------------------|--|
| Maurer <i>et al.</i> [19] | injection Omalizumab 75 mg 150 mg 300 mg-once in 4 weeks | 12 Weeks | Dose-dependent. UAS reduced by 44% in 300mg group.53% showed remission | 16 | Diarrhoea, Infections, cough, epistaxis |
| Grattan <i>et al.</i> [23] | Tab-cyclosporine 4mg/kg/day | 4 weeks | 65% were responders | 24 | GI upset, headache,flu-like Symptoms,leg Cramps,URI, Hypertrichosis Headache,flu-like symptoms, phlebitis |
| O'Donnell <i>et al.</i> [24] | IVIg 0.4 mg/kg/ day | 5 days | 7/10 patients responded; UAS reduced by 68% | 24 | Headache,flu-like symptoms, phlebitis |
| Perez <i>et al.</i> [20] | Tab methotrexate 5-0mg/week | 3Weeks to >6 months | 12/16 responded; UAS reduced by 70% | NA | Hair thinning, fatigue |
| Tseng <i>et al.</i> [4] | Autologous Whole blood-weekly Subcutaneous Injections | 8 Weeks | 11/20 patients responded | 24 | Nil |
| Debbarman <i>et al.</i> [10] | autologous serum therapy-weekly IM injections | 9 Weeks | UAS reduced by 83% | 24 | Nil |
| Present study | Injection Histaglobulin Subcutaneous Weekly | 8 Weeks | UAS reduced by 80.2% 48% showed complete Remission | 24 | Nil |

IVIg=Intravenous immunoglobulin, NA, Not available, UAS= Urticaria activity score, IM=intramuscular,

GI=Gastrointestinal

This study proves the effectiveness of weekly histaglobulin injection in producing long-term relief among patients with CU. The drug produced 80.2% reduction in the disease activity by 8 weeks. Complete long-term remission was achieved in 48.5% of patients who were enrolled into the study. The drug had its onset of action from the 1st week onward while about 50% reduction in disease activity was observed by the 2nd week of follow-up. The overall weekly requirement of oral antihistamine reduced to <2/week and the effect of histaglobulin persisted even after 4 months of stopping the therapy.

V. Conclusions

Patients of CU perceived a significant improvement in symptoms during the treatment period and it produced long-term remission too. No adverse effects were observed with the drug. Histaglobulin may thus be a viable alternative to the existing treatment modalities.

Financial Support and Sponsorship

Nil

Conflicts of Interest

There are no conflicts of interest.

References

- [1]. Goh CL, Tan KT. Chronic autoimmune urticaria: Where we stand? *Indian J Dermatol.* 2009;54:269–74.
- [2]. Yadav S, Upadhyay A, Bajaj AK. Chronic urticaria: An overview. *Indian J Dermatol.* 2006;51:171–7.
- [3]. Powell RJ, Leech SC, Till S, Huber PA, Nasser SM, Clark AT. BSACI guideline for the management of chronic urticaria and angioedema. *Clin Exp Allergy.* 2015;45:547–65. [PubMed]
- [4]. Godse KV. Urticaria meter. *Indian J Dermatology.* 2012;57/5/410/100510.
- [5]. Konstantinou GN, Asero R, Maurer M, Sabroe RA, Schmid-Grendelmeier P, Grattan CE. EAACI/GA (2) LEN task force consensus report: The autologous serum skin test in urticaria. *Allergy.* 2009;64:1256–68. [PubMed]
- [6]. HISTOGLOB (Histaglobulin) Ambernath, India: Bharat Serums and Vaccines Limited; 2012.
- [7]. Kaplan AP. Treatment of chronic spontaneous urticaria. *Allergy Asthma Immunol Res.* 2012;4:326–31. [PubMed]
- [8]. Jurakic Toncic R, Lipozencic J, Marinovic B. Treatment of chronic urticaria. *Acta Dermatovenerol Croat.* 2009;17:305–22. [PubMed]
- [9]. Zuberbier T, Asero R, Bindslev-Jensen C, Walter Canonica G, Church MK, Giménez-Arnau AM, et al. EAACI/GA (2) LEN/EDF/WAO guideline: Management of urticaria. *Allergy.* 2009;64:1427–43. [PubMed]
- [10]. Debbarman P, Sil A, Datta PK, Bandyopadhyay D, Das NK. Autologous serum therapy in chronic urticaria: A promising complement to antihistamines. *Indian J Dermatol.* 2014;59:375–82. [PMC free article] [PubMed]
- [11]. Shi C, Li Y, Luo Y, Shi C, Yan X, Yang K, et al. IgE-mediated allergy: A rare cause of chronic spontaneous urticarial with allergen-specific immunotherapy as treatment option – A systematic review with meta-analysis from China. *J Eur Acad Dermatol Venereol.* 2012;26:533–44. [PubMed]
- [12]. Mohanty M, Mohapatra S, Pattnaik KP, Swain TR. Prevention of multiple drug allergy by histaglobulin. *Indian J Pharmacol.* 2006;38:68–9.
- [13]. Yoshii H, Fukata-Yamazaki Y, Yamamoto K, Yago H, Yanagihara Y, Okudaira H. A complex of histamine/mouse gamma-globulin preferentially inhibits allergen-induced peritoneal accumulation of eosinophils, but not neutrophils, in mice. *J Allergy Clin Immunol.* 1997;100(6 Pt 1):809–16. [PubMed]
- [14]. Narayana J, Shanthi T, Bharadwaj S. Efficacy of histaglobulin on allergic rhinitis. *Indian J Otolaryngol Head Neck Surg.* 1997;49:77–9. [PMC free article] [PubMed]
- [15]. Gushchin IS, Luss LV, Il'ina NI, Larina ON, Pakhomova LA. Therapeutic effectiveness of histaglobin preparations in patients with allergic rhinitis and chronic urticaria. *Ter Arkh.* 1999;71:57–62. [PubMed]
- [16]. Asero R, Tedeschi A. Usefulness of a short course of oral prednisone in antihistamine-resistant chronic urticaria: A retrospective analysis. *J Investig Allergol Clin Immunol.* 2010;20:386–90. [PubMed]
- [17]. Toubi E, Blant A, Kessel A, Golan TD. Low-dose cyclosporin A in the treatment of severe chronic idiopathic urticaria. *Allergy.* 1997;52:312–6. [PubMed]
- [18]. Cooke A, Bulkhi A, Casale TB. Biologics: Targets and therapy role of biologics in intractable urticaria. *Biol Targets Ther.* 2015;9:25–33. [PMC free article] [PubMed]
- [19]. Maurer M, Rosén K, Hsieh HJ, Saini S, Grattan C, Giménez-Arnau A, et al. Omalizumab for the treatment of chronic idiopathic or spontaneous urticaria. *N Engl J Med.* 2013;368:924–35. [PubMed]
- [20]. Perez A, Woods A, Grattan CE. Methotrexate: A useful steroid-sparing agent in recalcitrant chronic urticaria. *Br J Dermatol.* 2010;162:191–4. [PubMed]
- [21]. Bajaj AK, Saraswat A, Upadhyay A, Damisetty R, Dhar S. Autologous serum therapy in chronic urticaria: Old wine in a new bottle. *Indian J Dermatol Venereol Leprol.* 2008;74:109–13. [PubMed]
- [22]. Majid I, Shah S, Hassan A, Aleem S, Aziz K. How effective is autologous serum therapy in chronic autoimmune urticaria. *Indian J Dermatol.* 2015;60:102. [PMC free article] [PubMed]
- [23]. Grattan CE, O'Donnell BF, Francis DM, Niimi N, Barlow RJ, Seed PT, et al. Randomized double-blind study of cyclosporin in chronic 'idiopathic' urticaria. *Br J Dermatol.* 2000;143:365–72. [PubMed]
- [24]. O'Donnell BF, Barr RM, Black AK, Francis DM, Kermani F, Niimi N, et al. Intravenous immunoglobulin in autoimmune chronic urticaria. *Br J Dermatol.* 1998;138:101–6. [PubMed]

Dr.Surya mangadevi. "Efficacy of Injection Histoglob in Treatment Of Chronic Urticaria-A Prospective Study." *IOSR Journal of Dental and Medical Sciences (IOSR-JDMS)*, vol. 18, no. 3, 2019, pp 57-62.