

## A Simplified Method for Fabrication of Interim Prosthesis for Maryland Bridge

Dr Prateek Mishra<sup>1</sup>, Dr Lakshita Singh<sup>2</sup>

<sup>1</sup> Tutor, ESIC Dental College and Hospital, Rohini Sector 15, Delhi, India

<sup>2</sup> Intern, ESIC Dental College and Hospital, Rohini Sector 15, Delhi, India

Corresponding Author: Dr Prateek Mishra

---

**Abstract:** An edentulous space in the mandibular anterior region can produce a psychological impact on the young patient and is one of the most difficult esthetic challenges in dentistry. With the advent of resin cements, Maryland bridge are highly effective treatment option in these situations resulting in high levels of patient satisfaction. Provisional restorations are not much documented for Maryland bridge and needs its due consideration while treatment planning. This clinical report describes an efficient and simplified technique for provisionalisation of Maryland bridge.

**Key words:** Maryland Bridge, Provisional Restoration, Interim prosthesis .

---

Date of Submission: 20-02-2019

Date of acceptance: 06-03-2019

---

### I. Introduction

There are various treatment options available for the replacement of the missing mandibular anterior incisors such as implant, removable partial denture and fixed partial denture. At certain circumstances like insufficient quantity and quality of bone for implants, presence of large pulp chambers and unavailability of sufficient enamel for full veneer crowns, a more conservative and less invasive resin bonded prosthesis may be an alternative treatment to replace the missing tooth as well as preserve the remaining alveolar ridge and soft tissue.

Resin bonded or resin retained bridges (RBBs/RRBs) were first described in the 1973 when the natural extracted tooth of the patient was cemented directly to the etched enamel surface with composite resin for a limited time period to provide esthetics.<sup>1</sup> The 'Maryland Bridge' was developed at the University of Maryland used non-precious alloys that can be etched to provide micromechanical retention for resin cement.<sup>2</sup> Provisional restorations in fixed prosthodontic rehabilitation are important treatment procedures, particularly if the restorations are expected to function for extended periods of time or when additional therapy is required before completion of the rehabilitation.<sup>3</sup> However, there are not much documentation about provisional restoration during the fabrication of Maryland bridge. The case report entails the clinical and lab procedure of fabricating an interim prosthesis after abutment preparation for Maryland bridge.

### II. Case Report

A 26yrs old female patient reported to the Department of prosthodontics, ESIC Dental College & Hospital, Delhi with the chief complaint of poor appearance due to missing mandibular central incisors. Patient had undergone extraction with the tooth two months back due to trauma. Replacement of the missing teeth with implants needed bone augmentation procedure to provide stability of the implants. The patient did not agree to the proposed surgical treatment plan. Moreover, radiographic examination, revealed large pulp chambers of abutment tooth with high chances of accidental exposure during full veneer crown preparation. A conservative and minimally invasive adhesive bridge was planned to restore the missing mandibular central incisors.

Minimal tooth preparation of the abutments (#32, #33, #42 and #43) was performed on the lingual surfaces not extending beyond the linguo-proximal line angles on the abutments. Lingual preparation ended 1mm from the incisal edge and a light chamfer finish line was prepared 1 mm supragingivally. Parallel retentive grooves were made in each preparation on the surface facing the edentulous space. (Fig. 1)

Impression were made with addition silicone (Express XT, 3M ESPE, Germany) and two sets of cast were poured in die stone (Kalabhai Ultrarock Die Stone, Bangalore). One set is sent to lab for metal framework fabrication and the other was employed for fabrication of interim prosthesis. Orthodontic wire 21 gauge (Jaypee SS Wire Hard 200gm, Delhi) were adapted on the lingual surface of the abutment tooth making sure that sufficient space is available for the acrylic tooth. (Fig. 2) After securing the wire framework to the abutment, the cast was lubricated with separating media (Cold Mould Seal, Pyrax Polymer, Roorkee, Utrakhnad). Auto polymerizing tooth colored acrylic (Artiplus Dentsply International, Inc., York, PA, USA) was mixed as per the

manufacturer's instruction and adapted over the lingual surface of abutment tooth while the acrylic denture tooth were secured at the edentulous space. After the acrylic resin has polymerized, the interim prosthesis is finished and polished. The provisional restoration kept paper thin and correctly contoured, precisely following the gingival margins on the cast. The restoration was cemented in place using Non Eugenol based cement (Tempocem Ne Automix Refill, Dmg America), occlusion was verified in centric and eccentric mandibular positions and it was made sure that there was no interferences. (Fig. 3) Post cementation instructions were given and patient was followed up after 24 hours. Patient was satisfied with the appearance and speech after interim prosthesis cementation. (Fig. 4)

### III. Discussion

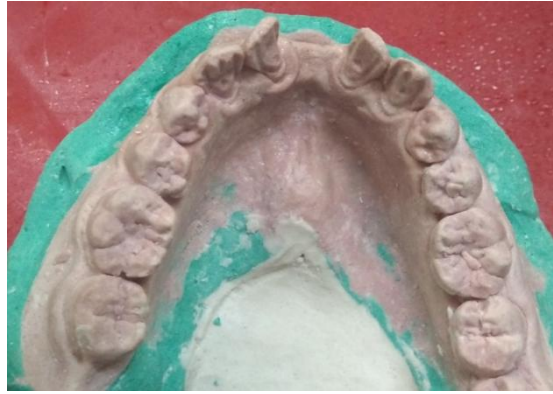Replacement of missing teeth with conventional fixed partial denture is generally the first preference for a practitioner but at times large pulp chambers in the abutments, expected transition in the position of the gingiva and age of the patient were factors that precludes the use of conventional fixed prostheses. With the same very reasons Maryland bridge was considered for this case. While Maryland bridge have compromised retention and corresponding life spans, newer self-etch adhesive systems helps to ensure that such restorations are retained for reasonably long periods of time<sup>4,5,6</sup>. The new self-etch universal resin cement systems are valuable tools in ensuring longevity of such restorations that allow them to be in service for the intended period. The three most common complications associated with resin-bonded prosthesis is debonding (21%), tooth discoloration (18%) and caries (7%).<sup>7,8</sup> Fabrication of provisional restorations is an important procedure in fixed prosthodontics as they serves the functions of pulpal protection, positional stability, occlusal function, and esthetics.<sup>9</sup> In this case report, Orthodontic SS wire 21 gauge was adapted over abutment tooth to provide strength to the interim prosthesis. Indirect technique was employed for the fabrication of prosthesis. This technique has several advantages over the direct procedures like there is no contact of free monomer with the prepared teeth or gingival which might cause tissue damage and an allergic reaction or sensitization. The technique avoids subjecting prepared tooth to the heat evolved from the polymerizing resin. Indirect technique produces restoration with a superior marginal fit and as an auxiliary is involved in fabricating the restoration in the lab, it frees the patient and dentist for considerable amount of time.<sup>9</sup> The design for the Maryland bridge allowed for a single path of insertion of the interim prosthesis thus avoiding displacement of the prosthesis along any other path except the path of insertion of the prosthesis. Temporary cement further improved the bond between the provisional and the tooth structure, thus increasing the overall retention.

### IV. Conclusion

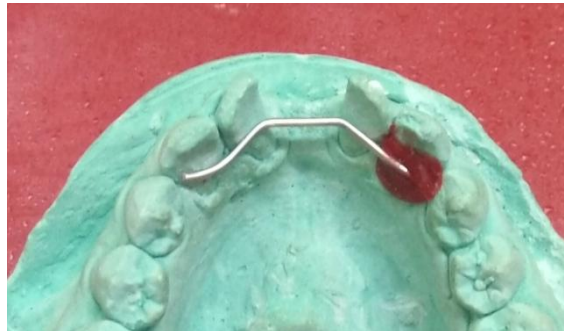One of the most important aspects of dental profession is to provide a predictable outcome to any oral rehabilitation, and the use of the provisional restoration is a critical phase in the treatment. The use of interim prosthesis in Maryland bridge, maintains health and contour of the underlying and surrounding tissues, and ensures the patient's comfort and satisfaction.

### References

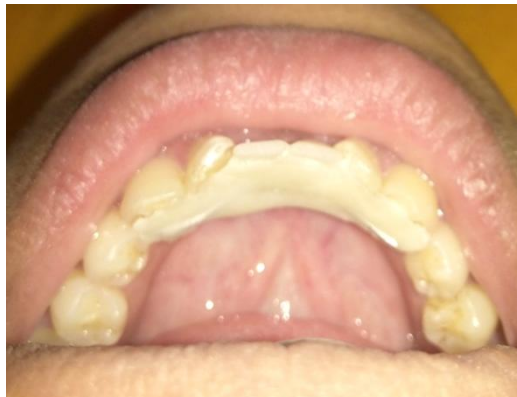- [1]. Howe DF, Denehy GE (1977) Anterior fixed partial dentures utilizing the acid-etch technique and a cast metal framework. *J Prosthet Dent* 37: 28-31.
- [2]. St George G, Hemmings K, Patel K (2002) Resin-retained bridges re-visited. Part 1. History and indications. *Prim Dent Care* 9: 87-91
- [3]. D. R. Federick (1975) "The provisional fixed partial denture," *J Prosthet Dent* 34 : 520-526.
- [4]. Stolpa JB (1975) An adhesive technique for small anterior fixed partial dentures. *J Prosthet Dent* 34: 513-519.
- [5]. Shillingburg HT, Hobo S (1997) Fundamentals of fixed prosthodontics, 3<sup>rd</sup> edition, Quintessence Publishing Co Inc, IL, USA.
- [6]. Jenkins CB (1985) The bond strength of new adhesive recommended for resin-bonded bridges. *J Dent Res* 64: 664.
- [7]. Pratyusha P, Jyoti S, Kaul RB, Sethi N (2011) Maryland bridge: An interim prosthesis for tooth replacement in adolescents. *Int J Clin Pediatr Dent* 4: 135-138.
- [8]. Goodacre CJ, Bernal G, Rungcharassaeng K, YK Kan J (2003) Clinical complications in fixed prosthodontics. *J Prosthet Dent* 90: 31-41.
- [9]. H. B. Dumbrigue (2003) Composite indirect-direct method for fabricating multiple-unit provisional restorations, *J Prosthet Dent* 89: 86-88.




**Figure 1 :** Diagnostic cast of Prepared Abutment



**Figure 2 :** Orthodontic wire adapted on the lingual surface of the abutment tooth



**Figure 3:** Final cementation of Interim Prosthesis



**Figure 4 :** Pre and Post Cementation Frontal Profile of Patient

Dr Prateek Mishra. "A Simplified Method for Fabrication of Interim Prosthesis for Maryland Bridge."  
IOSR Journal of Dental and Medical Sciences (IOSR-JDMS), vol. 18, no. 3, 2019, pp 81-83.