

## Vanek's Tumor – An Unusual Cause Of Intussusception – A Case Report And Review Of Literature

Dr Ann Rhoda Abraham, Prof Dr G Muthu Kumaran

<sup>1</sup>Post Graduate in General Surgery Saveetha Medical Hospital and College Saveetha Nagar, Thandalam  
Chennai – 602 105 India

<sup>2</sup>Professor Department of General Surgery Saveetha Medical Hospital and College  
Saveetha Nagar, Thandalam Chennai – 602 105 India

Corresponding Author: Dr Ann Rhoda Abraham

---

**Abstract:** Intussusception of the bowel in an adult is a rare surgical emergency. Diagnosis is quite simple as the patient presents with features of intestinal obstruction. The causes are varied with adults and infants. Vanek's tumor is an inflammatory fibroid polyp with high eosinophilic infiltration. Vanek's tumour is a rare cause of intussusception in an adult. Here we present a case of a 40-year-old male who presented with abdominal pain of 3 days onset was diagnosed to have sub-acute intestinal obstruction. On further imaging, he was diagnosed to have intussusception and was taken up for emergency laparotomy. Intraoperatively the intussusception was relieved and the cause was found to be a hard intra-luminal mass. Resection of the mass with 5 cm clearance was done with end to end anastomosis. Histo-pathology revealed an inflammatory fibroid polyp.

**Keywords:** Intussusception, Vanek's tumor, inflammatory fibroid polyp, benign tumour

---

Date of Submission: 20-02-2019

Date of acceptance: 06-03-2019

---

### I. Introduction:

Inflammatory fibroid polyp is a benign tumour of the gastro-intestinal tract. It is of mesenchymal origin. Incidence being 0.1-2%. It was first described by Vanek in 1949, hence also known as "Vanek's Tumor" [1], polypoid fibroma, polypoid eosinophilic granuloma, inflammatory pseudo-tumour. It is a submucosal proliferation with vascularized fibromuscular tissue with high eosinophilic inflammatory infiltration. It most frequently arises in the gastric antrum 66-75% > small bowel 18-20% > colorectal region 4-7% > gall bladder 1%, esophagus 1% duodenum 1%. Rarely it reaches more than 6cm. But the ileal segment is more commonly prone for undergoing intussusception due to the polyp.

### II. Case Presentation

40-year-old male came with complaints of abdominal pain, vomiting and constipation for the past three days. Pain was generalised, intermittent, colicky, with no aggravating or relieving factors. No history of fever, jaundice or bleeding per rectum. He was not a smoker or alcoholic with no co-morbid history.

On admission, the vitals were stable. Examination revealed diffuse abdominal tenderness with mild distension, no guarding or rigidity. No mass palpable. No evidence of free fluid in the abdomen and bowel sounds were sluggish. Complete blood count, liver and kidney function tests were within normal limits. X-ray abdomen erect and ultrasound abdomen revealed few dilated bowel loops. CECT abdomen suggested ileo-ileal intussusception and a fluid dense lesion with telescoping of soft tissue causing near total luminal obstruction. Patient was planned for emergency laparotomy.

Intra-operatively, intussusception was found almost 40cm proximal to the ileo-caecal junction. It was reduced and a firm intra-luminal mass 4x3cm was palpated at the site of intussusception. The intussuscepted bowel segment was resected and end to end anastomosis was done. The intra-luminal mass was sent for histopathology and it revealed Inflammatory Fibroid Polyp.

Post-operatively patient recovered well and was discharged after 7 days. The patient was then reviewed one month later and was found to be recovering well.

### III. Conclusion

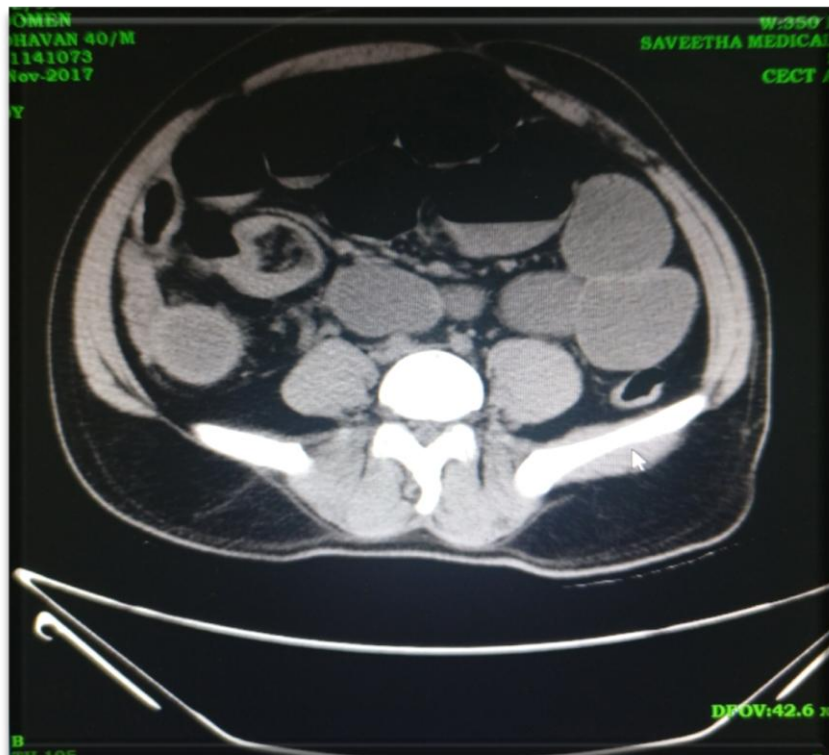
Intussusception is the telescoping of one bowel segment into the lumen of the distal segment. It can occur with the cause due to a lead point or without a lead point [2]. A lead point is a lesion or a variation in the intestine that is trapped by peristalsis and dragged into the lumen of the distal segment. Lead points are

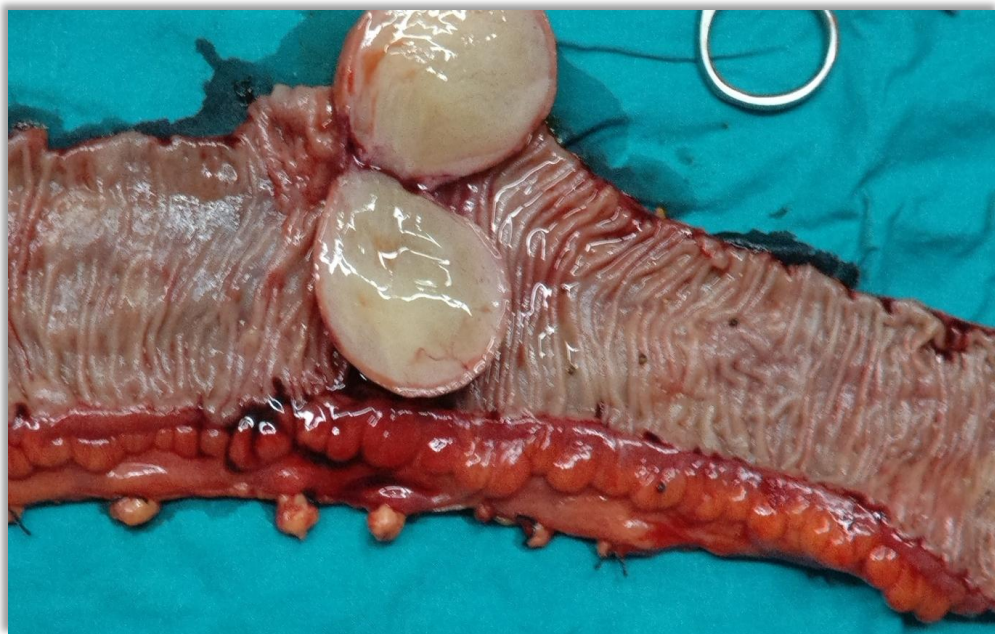
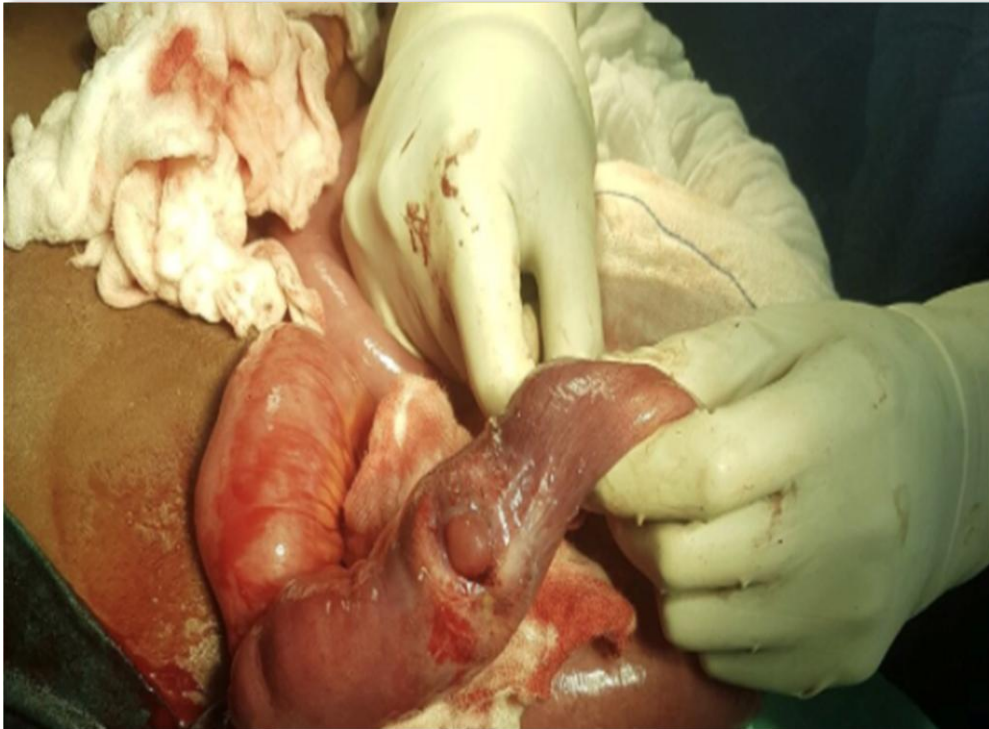
identified in about 90% of adult cases and are rare in children with intussusception. Incidence is 1 to 4 per 1000 live births. The male to female ratio of intussusception is 3:2. The peak age is 5-10 months. Some of the causes in children are: 1) lymphoid hyperplasia, 2) Meckel's diverticulum, 3) polyp, 4) purpura etc. and in adults: 1) Celiac disease, 2) Scleroderma, 3) Whipple's disease, 4) polyp, 5) foreign body, 6) benign or malignant tumours. The classical triad of intermittent abdominal pain, vomiting and right upper quadrant mass with occult rectal bleeding is found in less than 20% of intussusception cases. Absence of bowel in the right lower quadrant is called Dance sign. Ileo-colic type of intussusception is the most common followed by ileo-ileal and ileo-ileo-colic and colo-colic. Bowel enema is the gold standard of choice with signs of filling defect and crescent sign. CT is the modality of choice in adults which shows the "bowel-in-bowel" configuration. The segment that prolapses into the other is the intussusceptum and the part that receives it is called intussusceptiens.

Inflammatory fibroid polyps are non-neoplastic lesions found in the alimentary tract. They are most commonly found in the antrum of the stomach and ileum, but can occur throughout the gastro-intestinal tract[3]. In the stomach, when they reach a significant size, they can cause gastric outlet obstruction – "ball – valve syndrome"[4]. They present in the 5<sup>th</sup> – 7<sup>th</sup> decade and can involve both the sexes. When symptomatic, they present with abdominal pain, weight loss, bleeding, dyspepsia, iron deficiency anemia[5]. Though the etiology is unknown, it has been proposed to be due to either chronic irritation and inflammation or reaction of the body to any kind of intestinal trauma[6]. Cut section reveals whorled, concentric, "onion" skin pattern. Histologically, vascular and fibroblastic proliferation with inflammatory cells, particularly eosinophils is seen. Immunohistologically it is positive for CD34 and Vimentin. Recent studies show expression and mutation in PDGFRA and familial occurrence, suggesting a possible neoplastic factor in the aetiology. An ileal inflammatory fibroid polyp causing chronic ileocolic intussusception can mimic a caecal carcinoma. IFPs are a rare cause of intestinal obstruction in adults. The mainstay of treatment is surgical excision.

Intussusception in adults is a rare occurrence and inflammatory fibroid polyp being the cause of intussusception is also rare. Hence a good understanding about the condition and prompt diagnosis and intervention can prevent complications.

- 1) <http://www.msjonline.org/index.php/ijrms/article/view/958>
- 2) <https://bestpractice.bmj.com/topics/en-us/679>
- 3) <https://www.karger.com/Article/PDF/103326>
- 4) [http://scielo.isciii.es/scielo.php?script=sci\\_arttext&pid=S1130-01082017000300025](http://scielo.isciii.es/scielo.php?script=sci_arttext&pid=S1130-01082017000300025)
- 5) <https://www.ncbi.nlm.nih.gov/pmc/articles/PMC2740047/>
- 6) [http://jcdr.net/article\\_fulltext.asp?issn=0973-709x&year=2013&month=December&volume=7&issue=12&page=2994&id=3821](http://jcdr.net/article_fulltext.asp?issn=0973-709x&year=2013&month=December&volume=7&issue=12&page=2994&id=3821)





Dr Ann Rhoda Abraham. "Vanek's Tumor – An Unusual Cause Of Intussusception – A Case Report And Review Of Literature." IOSR Journal of Dental and Medical Sciences (IOSR-JDMS), vol. 18, no. 3, 2019, pp 14-16.