

## A Case Study on Assessment of the Role of Different MRI Sequences and Contrast in Determining Tumor Margins in Musculoskeletal Tumors

<sup>1</sup>Dr Ramzi Shamsuddeen <sup>2</sup>Dr Praveen John <sup>3</sup>Dr Jini P Abraham

<sup>4</sup>Dr Meera Varghese <sup>5</sup>Dr Abdul Wahab

<sup>1</sup>Post Graduate Student, Department of Radio-diagnosis, A.J. Institute of Medical Sciences and Research Centre, Mangaluru, Karnataka

<sup>2</sup>Associate Professor, Department of Radio-diagnosis, A.J. Institute of Medical Sciences and Research Centre, Mangaluru, Karnataka

<sup>3</sup>Post Graduate Student, Department of Radio-diagnosis, A.J. Institute of Medical Sciences and Research Centre, Mangaluru, Karnataka

<sup>4</sup>Post Graduate Student, Department of Radio-diagnosis, A.J. Institute of Medical Sciences and Research Centre, Mangaluru, Karnataka

<sup>5</sup>Post Graduate Student, Department of Radio-diagnosis, A.J. Institute of Medical Sciences and Research Centre, Mangaluru, Karnataka

---

**Abstract:** MRI is the most useful investigation following plain x-rays in the detection and further evaluation of both bone and soft tissue sarcomas. The multiplanar capability, combined with the excellent soft tissue contrast and anatomical detail, mean that even small soft tissue or bony lesions can be detected with accuracy.

The MRI appearance of some tissues is characteristic, so that the diagnosis may be apparent or the differential diagnoses narrowed following the MRI scan. Tissues that have a characteristic appearance on MRI include fat and hyaline cartilage. Some vascular lesions are also typical, such as arteriovenous malformations that exhibit flow voids due to rapid blood flow and venous malformations with bright slow flowing or stagnant blood. Other tissues may have an appearance that, while not diagnostic, may be suggestive of a few tissue types, for example fibrous tissue, haemorrhagic tissue or calcification

---

Date of Submission: 12-03-2019

Date of acceptance: 28-03-2019

---

### I. Introduction

Bone and soft tissue sarcomas are a rare form of carcinoma warrants further in- depth exploration of the existing diagnostic modalities to extract more sensitive and accurate imaging data for musculoskeletal malignancy and metastasis (1).

According to the World Health Organization (WHO) classification, the musculoskeletal tumors into two categories, primary and secondary depending on their site of occurrence (2). The most common types of malignant bone tumors are osteosarcoma, chondrosarcoma, and Ewing's sarcoma, however, in children account for 5% of all the malignancies (3). Studies have shown that a striking age-specific incidence rate of the bone tumors occurs among all the cases reported. Some precancerous conditions including Paget's disease, previous history of radiation therapy and cartilaginous dysplasias also lead to the development of bone sarcomas (4,5).

Following the plain radiographic analysis, further evaluation of the suspected tumors can be done by using computed tomography scans (CT) or magnetic resonance imaging (MRI)- informative in delineating the extent of the tumor within the bone and the soft tissue involvement (6). Recently, positron emission tomography (PET) is successfully being used as an imaging modality for osteosarcoma patients(1).

### II. Aims and Objectives

The study aims to study with the aid of MRI suspected cases of bone tumors and to determine the MRI characteristics of different primary bone tumors, co-relate imaging findings with surgical outcome and histopathological diagnosis and evaluate the accuracy of MRI in detecting various lesions by statistical analysis.

### III. Methods

This study was conducted in a group of 30 patients, who underwent MRI of suspected musculoskeletal tumours at A. J. Institute of Medical Sciences and Research Centre. MRI was performed using SIEMENS MAGNETOM AVANTO MR Machine with a 1.5 Tesla scanner. After MR images were acquired, study was done in cases of bone tumor to determine the MRI characteristics of different primary bone tumors and to co-relate imaging findings with surgical findings and histopathology.

### IV. Discussion

Musculoskeletal tumours constitute cutaneous and subcutaneous tissues, lymphatic tissue, vascular structure, musculo-aponeurotic tissue, adipose tissue, neurological tissue and connective tissues. Embryologically, most of them are derived from mesoderm; with an exception to it is neuroectodermal contribution in the case of peripheral nerves.

---

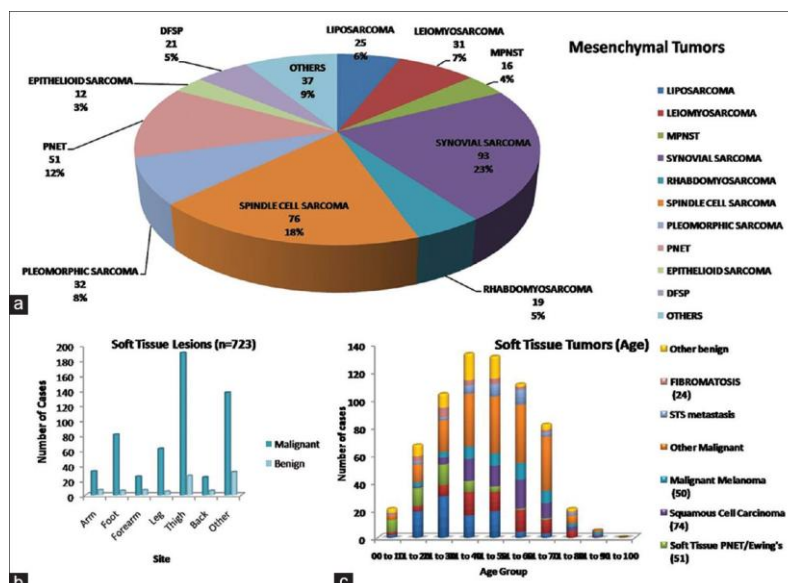


Figure 1: Soft tissue lesions (a) mesenchymal tumours incidence, (b) site distribution, and (c) age distribution

Resection of a soft tissue sarcoma involving the extremity is technically easy, but becomes more challenging if it involves adjoining vital structures. For proximate tumours local control is quite easy in comparison to the distally located tumours. Retroperitoneal sarcomas typically have poor prognosis, have a higher predilection for local repetition and for intra-abdominal distribution.

The style of repetition is generally calculable and most of the tumours are ordained to recur within two to three years. Additional radiotherapy following resection can minimize local recurrences, but its ability to enhance the comprehensive chances of survival is not assured. Additional chemotherapy may minimize the risk to high-grade tumours reasonably because of reduction in the size of tumour and an increase in the reactive zone, but this conception is argumentative.

According to *Malawer, M. M. and Sugarbaker, P. H. (2001)*; intralesional, marginal, en bloc or wide and radical excision are the four basic types of resection based on the association of resection plane to the tumour and its pseudocapsule (7): . A marginal excision can be opted for benign tumours and wide margins can be opted for limb salvage surgery in case of high-grade osteosarcoma (8,9).

There are different methods of reporting the value of resection margin namely the American Joint Committee on Cancer (AJCC) R system, Musculoskeletal Tumour Society (MSTS) system, and margin distance method. Strict numerical value for safe resection margin cannot be assigned; however, intralesional margins should be avoided. In absence of any numerical cut-off for resection margin, the analyses from existing literature become extremely difficult. The treatment should be rather personalized i.e. patient specific surgical procedure should be opted irrespective of tumour type.

Evaluation of the musculoskeletal tumour involves multimodality approach that includes the cross-sectional imaging and characterization of osseous neoplasm. The radiologic workup of musculoskeletal tumours initially involves the plain radiological imaging. Radiographs provide critical information regarding the lesion location, information of margin, matrix mineralization if any, cortical involvement and adjacent periosteal reaction of the tumour (10)(11).

For the delineation of the tumour margins surgeons now depends solely on the magnetic resonance imaging (MRI) before they plan the surgery. The excellent contrast provided by the MRI lead to improved evaluation of marrow involvement, surrounding muscle and tissue involvement and presence of any tissue necrosis and haemorrhage (12).

### Significance of surgical margin

As discussed above the choice of types of excision and above that the margin of clearance is a highly significant factor in controlling the local recurrence and metastasis. There has been an intense debate in the clinical community about the optimum margin of clearance required for successful removal of osteosarcoma.

Historically, the study by *Enneking et al (1980)* was the first study to assign a grading system for osteosarcoma based on surgical grade (G), the local extent (T), and the presence or absence of regional or distant metastases (M). In their study, they emphasized on prognostic factor that defines the progressive risk of the disease and progressive stages of disease that indicates surgical treatment. Moreover, they mentioned that a staging system for sarcoma should also delineate the guideline for adjunctive therapy. They defined high grade (G1) and Low grade (G2) tumours according to surgical grade and intracompartmental (T1), extracompartmental (T2) according to surgical compartment and presence and absence of metastasis (M0 and M1) as three pillars of staging. Authors have also mentioned that the use of type of resection (marginal, wide or radical) should be a part of surgical planning. However, definition of marginal or wide resection is not subjective but can be decided by the surgeon and the surgical team depending on situation (9).

*Kawaguchi et al. (2004)* established that in absence of preoperative treatment such as in case of high-grade sarcoma, a resection margin wider than 3 cm is required. In other situations, a 2 cm wide margin may suffice. For recurrent sarcoma, irrespective of grade, accurate method with adequately wide margin is required. However, the clinical community is yet to reach a consensus about the correct numerical value for safe resection margin (13).

*Li et al. (2012)* showed the frequency of local recurrence is insignificant reported for the choice of either wide

(>5mm) 2 margins or close (<5mm) margins (14).

On the other hand, **Betrand et al. (2015)** stressed on achieving a negative surgical margin. They described the surgical margin to be a significant risk factor for local recurrence. They showed for high grade non-metastatic osteosarcoma of extremities, a positive surgical margin is associated with poor prognosis. The study revealed that a negative margin of >1mm gives sufficiently better outcome than a positive margin (15).

MR imaging offers several advantages over other techniques such as higher resolution, high tissue contrast and multiplanar mode of imaging. However, compared to the conventional MR imaging various other advanced techniques are used now for demonstrating the morphological parameters such as margin, size, and tumour biological extent. Diffusion weighted imaging (DWI) technique has been used widely for the delineation of the tumour margin. DWI exploits the random motion of the water molecules in the human body. In biological tissue this water motion is restricted due to presence of macromolecules and cellular membranes. This property of the cellular tissues are used in DWI imaging for getting qualitative and quantitative information about the musculoskeletal tumours (16).

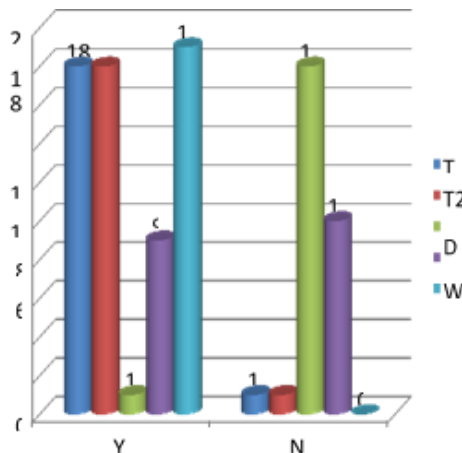
The role of DWI imaging in tumour cellularity monitoring was also been shown. It was reported that apparent diffusion coefficient correlated well with the tumour cellularity. A linear relationship was reported between ADC and tumour cellularity. A Pearson correlation of -0.88 indicated a significant correlation between the DWI data and tumour cellularity (17).

Studies have also shown that compared with the conventional MRI, STIR sequence can predict accurately the detection of bone tumours, soft tissue involvement and intramedullary extent definition (18).

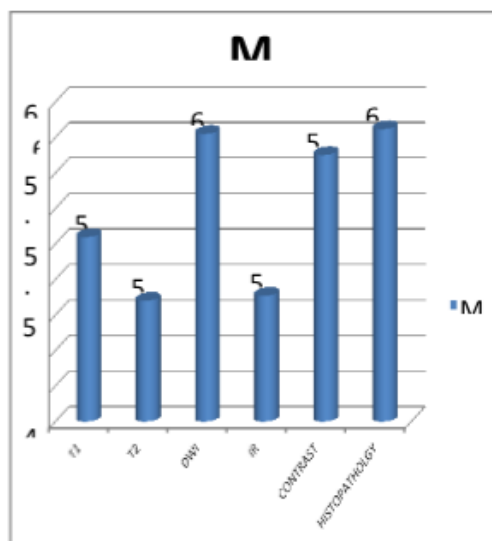
**V. Results and Conclusion**

Out of the 30 patients ,19(63.3%) showed soft tissue distribution,16(53.3%) showed joint involvement,8(26.6%) showed neurovascular bundle involvement,17(56.7%) showed epiphyseal involvement.All the 30 patients were included and surgical correlation was done with histopathology and correlated with each MRI sequences for accuracy.

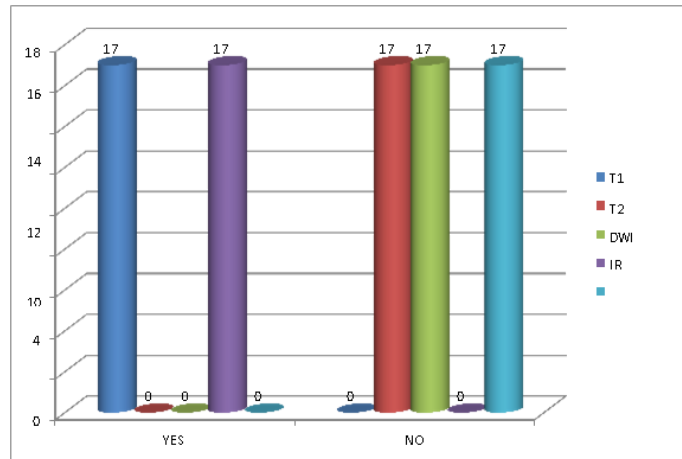
Among 30 patients 16 patients (53.3%) showed joint involvement in MRI, whereas, in 14 patients (46.7%) no such involvement was reported.T1 MRI was able to detect joint involvement in the entire patient population who were at first suspected to have joint involvement.



**Fig2:** soft tissue results distribution base on T1, T2, DWI IR, contrast results

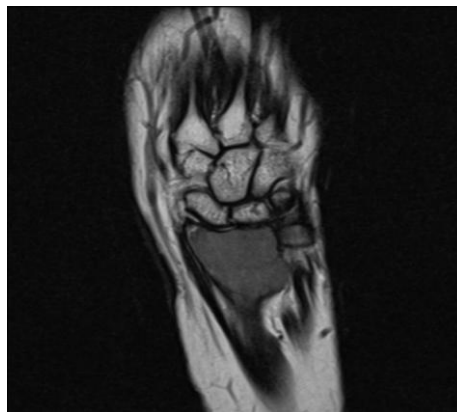


**Fig 3:** Graphical representation of mean value of T1, T2, DWI, IR, contrast and histopathology



**Fig 4:** Graph for EP results distribution base on T1, T2, DWI, IR, contrast results

Among total 16 patients who underwent T2 imaging, no joint involvement was detected. Therefore, it can be concluded that T2 imaging cannot predict the joint involvement in musculoskeletal tumor patients. In 6.3% of the patients, contrast-enhanced imaging helped in the detection of the joint involvement.

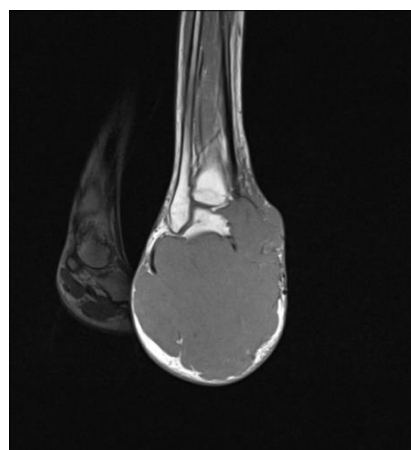


**Fig 5** Expansile lesion in subarticular region of radius with cortical erosion in ventral and dorsomedial aspect with soft tissue component.

Whereas, in 93.8% of patients contrast-enhanced imaging was unable to detect such changes in patients. T1 imaging was not able to detect neurovascular bundle involvement in all the patients.

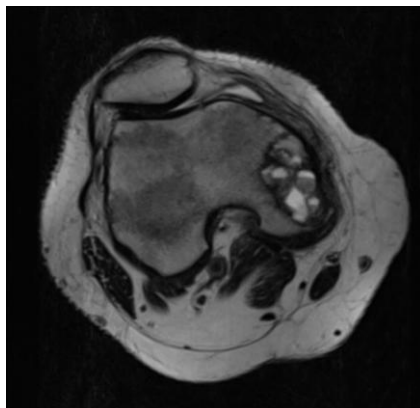
Among 7 (87.5%) patients T2 imaging was successful in detecting the neurovascular bundle involvement. In 1 patient T2 imaging was unable to detect any neurovascular bundle involvement.

The result showed that DWI was more accurate to determine the tumor margin when compared with the histopathological finding, on histopathological examination the average tumor margin came to be 6.0483 cm. DWI correctly predicted the tumor margin when compared with T1 (5.44 cm), T2 (5.08 cm), IR (5.10 cm) and Contrast (5.9cm)



**Fig 6** T1 Coronal showing well defined mass lesion replacing calcaneum with extension into soft tissue of plantar aspects and encasing tendons.

From this study, we conclude that T1, T2 and IR imaging (P-value=0 (P< 0.05). remains the best sequence to access the tumor margin compared with the DWI and contrast-enhanced imaging sequences. T1 has also accurately predicted the joint involvement, epiphyseal tumor extension and soft tissue abnormality in the study population. However, in predicting the neurovascular bundle involvement T1 was proved to be less accurate than the T2 imaging. For the epiphyseal involvement prediction, T1 and IR can be combined together while for joint involvement T1 can be combined with the contrast-enhanced imaging. However, this result should be confirmed with a prospective study with a larger sample size.



*Fig 7:T2 axial showing well defined eccentric multiseptated epimetaphyseal lesion in medial condyle of femur.*

Moreover, it was also observed in this study that compared with the histopathological evaluation which is still considered as the gold standard MRI can provide substantial information about the soft tissue involvement present in the musculoskeletal tumor. MRI may not replace the pathological evaluation but can provide quick information about the margins and can act as a tool to help the pathologist to identify the doubtful areas. This could be helpful in lessening the time required for specimen analysis.

#### **Conflict of Interests:**

All the authors declare about no conflicts in their interests regarding the study.

#### **References**

- [1]. Rajani R, Gibbs CP. Treatment of Bone Tumors. Surg Pathol Clin. 2012 Mar 1;5(1):301-18.
- [2]. Maria A, Gabriela L, Ileana C, Fabian R, Folescu R, Motoc A. On the Bone Tumours: Overview, Classification, Incidence, Histopathological Issues, Behavior and Review Using Literature Data. In: Poblet E, editor. Histopathology - Reviews and Recent Advances [Internet]. InTech; 2012 [cited 2018 Oct25].
- [3]. Unni KK, Inwards CY, Bridge JA, Kindblom LG, Wold LE. Tumors of the bones and joints (Atlas of Tumor Pathology series IV). Wash DC Am Regist Pathol. 2005;324-330.
- [4]. Hameetman L, Bovée JV, Taminiau AH, Kroon HM, Hogendoorn PC. Multiple osteochondromas: clinicopathological and genetic spectrum and suggestions for clinical management. Hered Cancer Clin Pract. 2004 Nov15;2(4):161-73.
- [5]. Verbeke SLJ, Bovée JVMG. Primary vascular tumors of bone: a spectrum of entities? Int J Clin Exp Pathol. 2011 Aug15;4(6):541-51.
- [6]. Ofluoglu O, Boriani S, Gasbarrini A, De Iure F, Donthineni R. Diagnosis and Planning in the Management of Musculoskeletal Tumors: Surgical Perspective. Semin Interv Radiol. 2010Jun;27(2):185-90.
- [7]. Malawer MM, Sugarbaker PH. Musculoskeletal cancer surgery: treatment of sarcomas and allied diseases. Springer Science & Business Media;2001.
- [8]. Yang Q, Zhao B, Zhang Z, Dong Y, Pan Y, Du X. Short-term outcomes of en bloc resection of solitary bone metastases in limbs. Med Sci Monit Int Med J Exp Clin Res. 2012Nov;18(11):CR648-655.
- [9]. Enneking WF, Spanier SS, Goodman MA. A system for the surgical staging of musculoskeletal sarcoma. Clin Orthop. 1980Dec;(153):106-20.
- [10]. Daniel A, Ullah E, Wahab S, Kumar V. Relevance of MRI in prediction of malignancy of musculoskeletal system-A prospective evaluation. BMC Musculoskelet Disord. 2009 Oct8;10(1):125.
- [11]. Bhuyan MH, Bhuyan RK. How accurate is MRI in prediction of musculoskeletal tumours -A prospective evaluation. Int J Biomed Res. 2015 Dec30;6(12):942-6
- [12]. Putta T, Gibikote S, Madhuri V, Walter N. Accuracy of Various MRI Sequences in Determining the Tumour Margin in Musculoskeletal Tumours. Pol J Radiol. 2016 Nov16;81:540-8.
- [13]. Kawaguchi N, Ahmed AR, Matsumoto S, Manabe J, Matsushita Y. The concept of curative margin in surgery for bone and soft tissue sarcoma. Clin Orthop. 2004Feb;(419):165-72.
- [14]. Li X, Moretti VM, Ashana AO, Lackman RD. Impact of close surgical margin on local recurrence and survival in osteosarcoma. Int Orthop. 2012 Jan;36(1):131-7.
- [15]. Bertrand TE, Cruz A, Binitie O, Cheong D, Letson GD. Do Surgical Margins Affect Local Recurrence and Survival in Extremity, Nonmetastatic, High-grade Osteosarcoma? Clin Orthop Relat Res. 2016 Mar;474(3):677-83.
- [16]. Costa FM, Ferreira EC, Vianna EM. Diffusion-Weighted Magnetic Resonance Imaging for the Evaluation of Musculoskeletal Tumours. Magn Reson Imaging Clin N Am. 2011Feb;19(1):159-80.
- [17]. SchnapauffD,ZeileM,NiederhagenMB,FleigeB,TunnP-U,HammB,etal.
- [18]. Diffusion-weighted echo-planar magnetic resonance imaging for the assessment of tumour cellularity in patients with soft-tissue sarcomas. J Magn Reson Imaging. 2009 Jun1;29(6):1355-9.
- [19]. Panuel M, Gentet JC, Scheiner C, Jouve JL, Bollini G, Petit P, et al. Physeal and epiphyseal extent of primary malignant bone tumours in childhood. Correlation of preoperative MRI and the pathologic examination. Pediatr Radiol.1993;23(6):421-4.

Dr Ramzi Shamsuddeen. "A Case Study on Assessment of the Role of Different MRI Sequences and Contrast in Determining Tumor Margins in Musculoskeletal Tumors." IOSR Journal of Dental and Medical Sciences (IOSR-JDMS), vol. 18, no. 3, 2019, pp 75-79.