

## Comparison of two distraction rate of periosteal distraction osteogenesis: An experimental study in the rabbits

Ahmad Al Nashar<sup>1</sup>, Hekmat yakoob<sup>2</sup>, Elias boutrous<sup>3</sup>

<sup>1,2,3</sup> (DDS, PhD, Department of Oral and Maxillofacial Surgery, Faculty of Dentistry,  
Al-Andalus University for Medical Sciences,  
Syrian Arab Republic)

Corresponding Author: Ahmad Al Nashar

---

**Abstract :** The aim of the present study was to evaluate the influence of two distraction rate of periosteal distraction on bone. A custom-made dynamic periosteal distraction device consisted of titanium perforated plate fixed to the lateral surface of the mandible in 12 adult rabbits. After an initial healing period of 7 days, the device was activated at a rate of 0.25 mm every 12 hours for 6 days in 6 animals (group 1), and at rate 0.5mm every 12 hours for 3 days in 6 animals (group 2). The animals were sacrificed after of 8 weeks of consolidation period. The specimens were then fixed, decalcified, and stained with hematoxylin and eosin. The histological evaluation showed a various amount of new bone formation with large spaces between bone trabeculae in the two groups. Although, the amount of new bone was greater in the group 2. The results of the present study showed that reducing the distraction rate increases bone formation.

**Keywords:** distraction rate, osteogenesis, periosteal distraction, periosteum

---

Date of Submission: 28-02-2019

Date of acceptance:18-03-2019

---

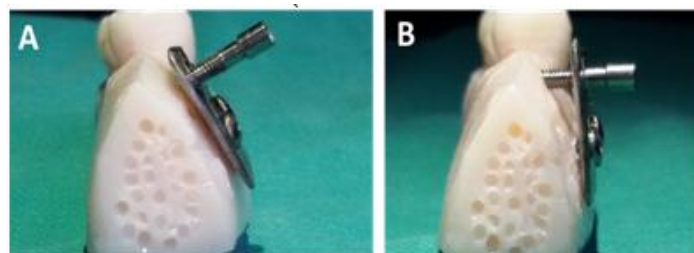
### I. Introduction

Dynamic periosteal distraction osteogenesis (PDO) is a relatively new technique, and its potential for producing new bone was first reported by Schmidt et al [1]. It is an alternative method that uses a biological process in which new bone formation occurs between segments that are gradually separated. [2,3] in other words this technique combines aspects of distraction osteogenesis (DO) and Guided Bone Regeneration (GBR). [4-6] Distraction osteogenesis consists of 5 sequential periods: osteotomy, latency, distraction, consolidation, and remodeling. [7] Studies of periosteal distraction with different protocols have been reported; however, optimal activation conditions have not yet been clarified [2]. Sencimen et al [8] reported dominance of adipose tissue under the periosteum in the PDO. This study clearly demonstrated that the quality of the newly formed bone depended on the distraction speed. Slowest speed produced bone of thicker trabeculae and less connective tissue and radiopacity closer to original bone. Other study clarified that the newly formed bone in PDO can be sustained and matured if it receives appropriate level of mechanical stress. [9] The aim of the present study was to evaluate the influence of two distraction rate of periosteal distraction on bone.

### II. Materials and methods

**1.1 Experimental animals:** Twelve adult male rabbits with a mean weight of  $2.5 \pm 0.25$  kg were used as the animal model. Experimental protocols were approved by University of Al Andalus University Committee of Animal Research. The animals were equally divided into two groups. After an initial healing period of 7 days, the device was activated at a rate of 0.25 mm every 12 hours for 6 days in group 1, and at rate 0.5mm every 12 hours for 3 days in group 2.

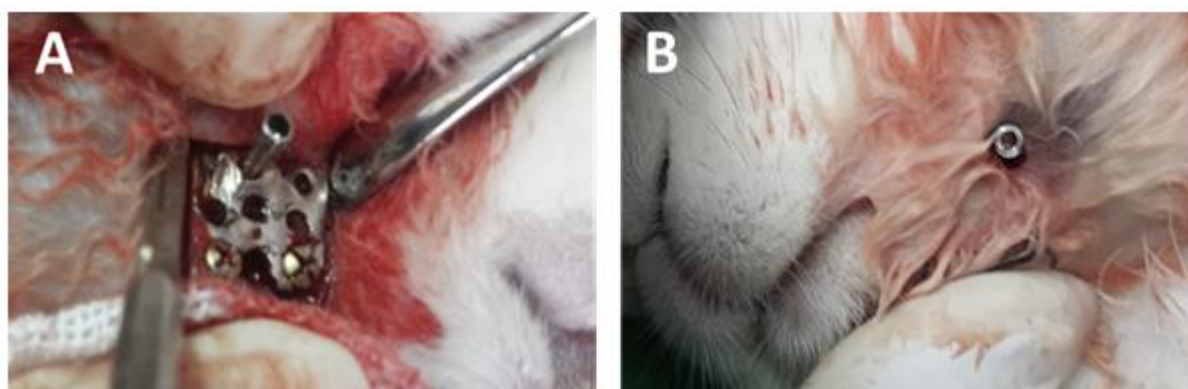
**1.2 Device description:** The device is consisted of a titanium perforated plate. The lower part of the plate has two holes for fixation screws (3mm length and 1mm diameter mini-screws) and the upper part has one serrated hole for distraction screw (titanium elevation screw with 10 mm length and 2 mm in diameter). Figure 1



**Figure1.** The periosteal distraction device, A: before activation 1, B: at the end of activation.

**1.3 Surgical procedure:** All surgical procedures were performed under general anesthesia with a combination of 35 mg/kg intramuscular ketamine and 5 mg/kg subcutaneous xylazine. Local anesthesia, consisting of 2% lidocaine with 1:100,000 epinephrine was infiltrated into the lateral surface of the mandibular body. The surgical site was shaved, prepared with 10% povidone-iodine solution, and draped to maintain aseptic conditions. A 1.5-cm-long incision in the skin was made along the inferior border of the mandible, and dissection was performed through the subcutaneous and muscle layers. The periosteum was carefully elevated to expose the lateral aspect of the mandibular body and the buccal cortex was porously perforated by drilling with fissure bur. The device was placed over the perforated area and then fixed to the bone surface from one end by 2 mini screws then the periosteum was sutured covering the whole plate finally the skin flaps were sutured with 4-0 silk. Soft tissue incision of 2mm in length was made over the activation screw and then the screw was rotated 360° to elevate the plate 1mm. Postoperative analgesics included ketorolac (0.5 mg/kg by mouth) and buprenorphine (0.3 mg intramuscular). After latency period of 7 days the screw was activated to elevate the periosteal. Figure2

**1.4 Specimens preparation:** After healing periods of 8 weeks, animals were sacrificed by an intravenous overdose of pentobarbital sodium. The mandibular distraction areas, including peripheral soft tissues, and distraction devices were carefully removed. All resection materials were kept in a 10% neutral buffered formalin solution for at least 3 days. Next, each distraction device was removed. The specimens were then decalcified in the formic acid solution. When sufficiently soft, tissue samples were processed and embedded in paraffin for histological examination. Standard 4–5-mm sections were prepared and transferred onto slides for each block of tissue. All slides were stained with hematoxylin and eosin and evaluated using a light microscope.



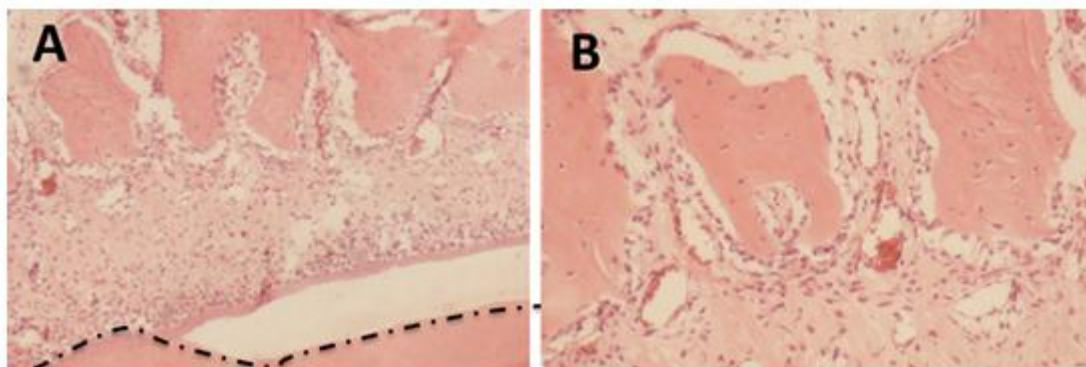
**Figure2.** Intraoperative photograph, A: distraction device, B: group distraction screw

### III. Results

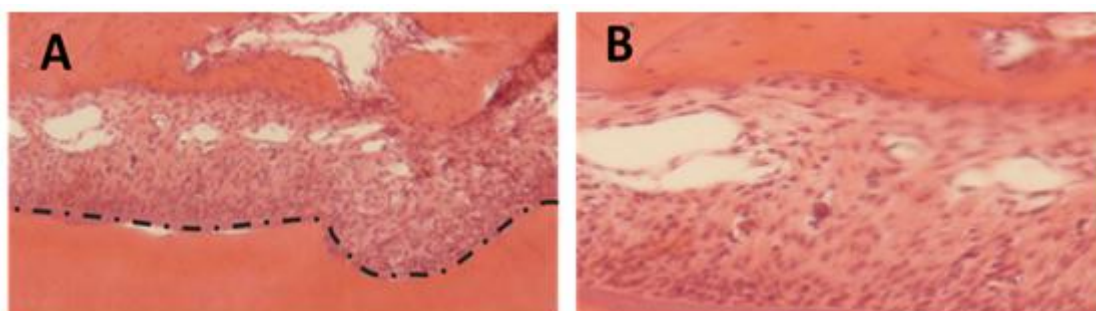
All animals resumed normal dietary habits during the first 24 hours after the operation, and none of the animals had a weight loss during the experimental study.

The histological evaluation showed after 8 weeks of consolidation a various amount of new bone formation with large spaces between bone trabeculae in the two groups. Although, the amount of new bone was greater in the group 2.

The bone islands were covered by a lining of osteoblasts. The majority of new formed bone located under the plate and separated from the original bone by a thick connective tissue which is rich in cells, new collagen, new blood vessels and layer of periosteal proliferation.



**Figure 3.** Histologic analyses of 8 weeks biopsy sample of group 1: A: (H&E staining, X 40), B: (H&E staining, X 100)



**Figure 4.** Histologic analyses of 8 weeks biopsy sample of group 2: A: (H&E staining, X 40), B: (H&E staining, X 100)

#### IV. Discussion

The aim of the present study was to evaluate the influence of two distraction rate of periosteal distraction on bone. In previous periosteal distraction studies, the distraction rates varied from 0.25 –1 mm/day, distraction period ranged from 5–15 days and latency period ranged from 1–14 days, whereas consolidation period ranged from 7 to 60 days. [10] This study compared between of 0.25 mm and 0.5 mm of distraction rate every 12 hours and the histological results showed a greater amount of new bone at the rate of 0.25 mm. Zakarai et al, [9] suggested that the optimal distraction speed is 0.33 mm/d or less which showed the least connective tissue interference, this rate is less than the optimum osteogenic distraction speed (0.5 to 1 mm/d or more) [11,12]in osteogenic distraction. This can be explained because cell and nutrition supplies come from both ends of the bone and the surrounding periosteum in osteogenic distraction; whereas, those supplies originate only from basal bone and periosteum in PDO. [13] Sencimen et al, [8] reported dominance of adipose tissue under the periosteum in the PDO. This study clearly demonstrated that the quality of the newly formed bone depended on the distraction speed, Slowest speed produced bone. Recently, Saulacic et al, [14] evaluated the influence of two protocols of periosteal distraction, 0.25 and 0.5 mm/24 h for 10 days, on bone formation. They concluded that, the two protocols of periosteal distraction resulted in moderate differences in terms of bone formation.

#### V. Conclusion

The results of the present study showed that reducing the distraction rate increases bone formation.

#### References

- [1]. BL Schmidt, L Kung, C Jones, N Casap, Induced osteogenesis by periosteal distraction, *J Oral Maxillofac*, 60, 2002, 1170-5.
- [2]. M Chin, BA Toth, Distraction osteogenesis in maxillofacial surgery using internal devices: Review of five cases, *J Oral Maxillofac Surg*, 54, 1996, 45–53
- [3]. T Takahashi, K Funaki, H Shintani, T Haruoka, Use of horizontal alveolar distraction osteogenesis for implant placement in a narrow alveolar ridge: A case report, *Int J Oral Maxillofac Implants* 19, 2004, 291–294.
- [4]. C Bosch, B Melsen, K Vargervik, Guided bone regeneration in calvarial bone defects using polytetrafluoroethylene membranes. *Cleft Palate Craniofac*, 32, 1995, 311–317.
- [5]. J Wiltfang, H-A Merten, J-H Peters, Comparative study of guided bone regeneration using absorbable and permanent barrier membranes: a histological report. *JOMI* 13, 1998, 416–422.

- [6]. C Tudor , L Bumiller, T Birkholz, P Stockmann, J Wiltfang, P Kessler, Static and dynamic periosteal elevation: a pilot study in a pig model. *Int J Oral Maxillofac Surg*, 39(9), 2010, 897-903.
- [7]. JB Cope, ML Samchukov, DE Muirhead. Distraction osteogenesis and histogenesis in beagle dogs: the effect of gradual mandibular osteodistraction on bone and gingiva, *J Periodontol*, 73, 2002, 271-82.
- [8]. M Sencimen, YS Aydintug, K Ortakoglu, Y Karlioglu, O Gunhan, Y Gunaydin, Histomorphometrical analysis of new bone obtained by distraction osteogenesis and osteogenesis by periosteal distraction in rabbits, *Int J Oral Maxillofac Surg*, 36, 2007, 235–242.
- [9]. O Zakaria , K Kon, S Kasugai, Evaluation of a biodegradable novel periosteal distractor, *J Biomed Mater Res B Appl Biomater*. 2012; 100(3):882-9.
- [10]. A Al Nashar, H Yakoob, E Boutres, Induced Osteogenesis by Periosteal distraction in Cranio-maxillofacial region: A systematic review. *International Journal of Current Research*, 8(06), 201632707-32714.
- [11]. GA Ilizarov, The tension-stress effect on the genesis and growth of tissues: Part II, The influence of the rate and frequency of distraction, *Clin Orthop*, 239, 1989, 263-85
- [12]. P Kessler, FW Neukam, J Wiltfang, Effects of distraction forces and frequency of distraction on bony regeneration, *Br J Oral Maxillofac Surg*, 43, 2005, 392–398
- [13]. HA Altug, YS Aydintug, M Sencimen, et al, Histomorphometric analysis of different latency periods effect on new bone obtained by periosteal distraction: an experimental study in the rabbit model, *Oral Surg Oral Med Oral Pathol Oral Radiol Endod*, 111, 2011, 539–46.
- [14]. N Saulacic, K Nakahara, T Iizuka, M Haga-Tsujimura, W Hofstetter, P Scolozzi, . Comparison of two protocols of periosteal distraction osteogenesis in a rabbit calvaria model. *J Biomed Mater Res B Appl Biomater*, 104(6), 2016, 1121-31

Ahmad Al Nashar. "Comparison of two distraction rate of periosteal distraction osteogenesis: An experimental study in the rabbits." *OSR Journal of Dental and Medical Sciences (IOSR-JDMS)*, vol. 18, no. 3, 2019, pp 84-87.