

Intra-Oral Molluscum Contagiosum with Post Radiotherapy Low Grade Soft Tissue Tumor in an Old Operated Case of Intra-Oral Malignancy

Shweta Joshi-Warpe¹, Bhushan M. Warpe^{2*}, V.D. Dombale, R.H. Deshpande

1 : Assistant Professor, Department of Pathology, B.K.L.W.R.M.C.

2* : Associate Professor, Department of Pathology, B.K.L.W.R.M.C.

3,4: Professor, Department of Pathology, B.K.L.W.R.M.C.

Corresponding author: Dr. Bhushan M. Warpe, Associate Professor, Department of Pathology, B.K.L. Walawalkar rural medical college, Shree-kshetra Dervan, At post-Sawarde, Tal. Chiplun, Dist. Ratnagiri, Pincode - 415606, Maharashtra state, India.

Abstract: Molluscum contagiosum (MC) is a self-limiting wart, resulting from pox-virus infection. The disease is generally seen on the skin of children or in the ano-rectal region of adults. This lesion is rare on the lips or in the oral cavity and if it does occur, then it is due to immuno-compromised status. MC generally produces a dome-shaped nodule that can be umbilicated. We report a rare case of a 52-year old leucopenic man with intra-oral MC infection and post radiotherapy low grade soft tissue tumor in an old operated case of intra-oral malignancy. This patient had an atypical ulcero-proliferative tumor-like growth in his right gum.

Key Words: Molluscum contagiosum (MC), post radiotherapy, low grade soft tissue tumor

Date of Submission: 28-02-2019

Date of acceptance: 18-03-2019

I. Introduction

MC can be spread by direct patient contact, flies, fomites, self-inoculation. Face, extremities and trunk are common sites of paediatric lesions, whereas in adults the ano-rectal area and adjacent areas are the most involved. Apart from sexual spread in adults, the non-sexual spread occurs through history of earlier trauma or previous other skin lesions ⁽¹⁾.

MC is self-limiting infection and generally complete recovery occurs within 18 months. If at all these lesions persist then; curettage, electro-cautery, popular incisions, liquid-nitrogen based cryo-therapy are the treatment modalities ⁽²⁾.

This is a rare case of a 52-year old leucopenic man with intra-oral MC infection and post radiotherapy low grade soft tissue tumor in an old operated case of intra-oral malignancy. This patient had an atypical ulcero-proliferative tumor-like growth in the right gingiva.

II. Case Report

A 52-year-old frail gentleman, of 45-kg body was a known operated case of Ca-mandible in 2011. He was provided post-surgical chemo-radiotherapy cycles in 2011. In 2012, he underwent maxillofacial reconstruction surgery with free fibula osteo-cutaneous flap. In the later part of 2012, he was re-operated for plate exposure with properly placed fibula flap. In 2015, the surgeon removed this plate.

Since last six months, the patient started developing ulcero-proliferative lesion measuring 2 x 2 cm in right gum (Fig. 1). He complained of anorexia since 10 days. No similar lesion was detected on the skin at time of presentation. He denied any sexual abuse, past skin infection or diabetes. His blood tests at presentation showed mild leucopenia with rest of the normal CBC parameters. His HIV-I & II was non-reactive. His HBsAg was negative.

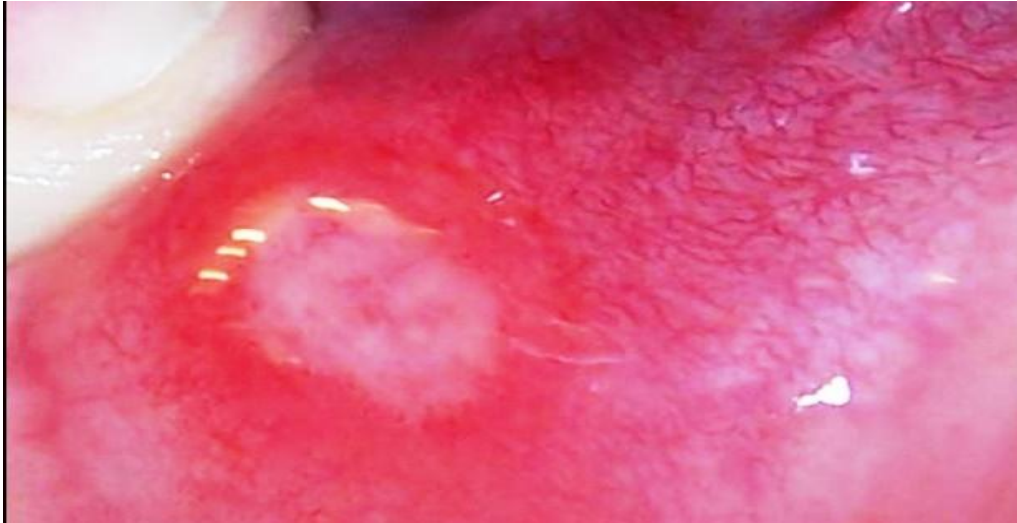


Fig.1: Clinical photograph: Right gum ulcer, measuring 2 x 2 cm.

Suspecting recurrence of prior malignancy (squamous cell carcinoma recurrence) and due to non-compliance to frequent follow-ups, patient gave permission for excisional biopsy of gum lesion, rather than incisional biopsy. The fragmented oral biopsy revealed acanthotic, partly ulcerated, non-keratinized stratified squamous lining which showed many intra-cytoplasmic eosinophilic inclusion bodies (Fig. 2). These molluscum (Handerson-Patterson) contagiosum bodies (MCB) are thought to be the collection of MC viral particles.

MCB were noted in the cytoplasm of superficial portions of the epithelium which lead to ulceration of epithelium at places. The sub-epithelial stroma revealed spindled tumour in partly necrotic background arranged in bundles, nodules with elongated, moderately pleomorphic, hyperchromatic nuclei (Fig. 3). Some nuclei showed atypical mitosis with prominent nucleoli. The histological diagnosis was intra-oral molluscum contagiosum with post radiotherapy low grade soft tissue tumour. The patient was advised Immunohistochemistry (IHC) but refrained from doing the same due to high cost.

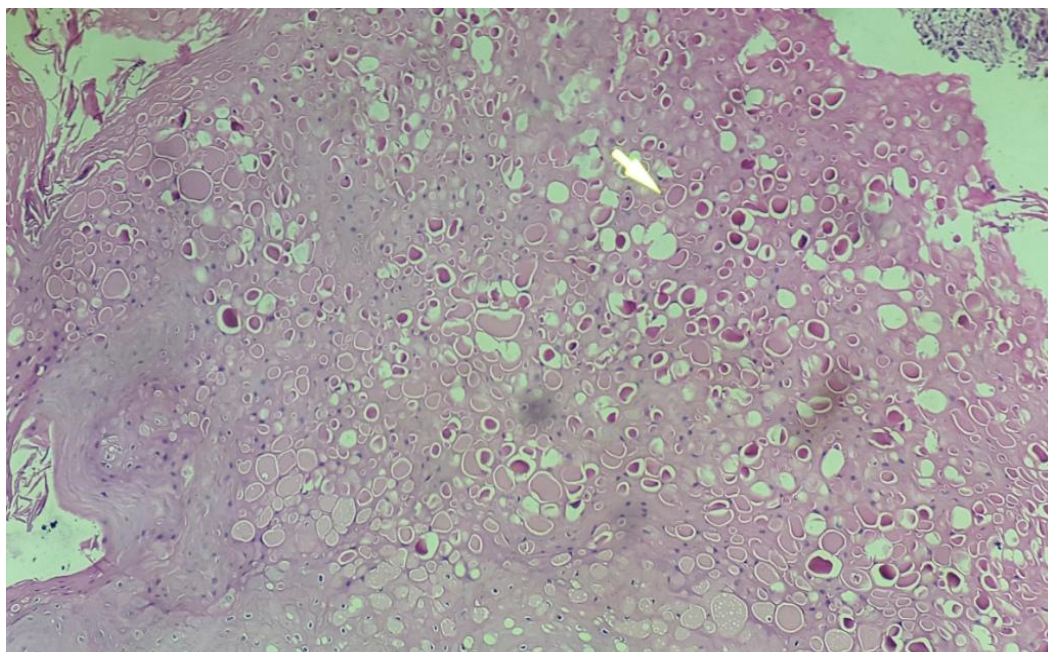


Fig.2: Micro-photograph-Gum biopsy shows acanthotic, partly ulcerated stratified squamous epithelial lining with many intra-cytoplasmic, eosinophilic inclusion bodies/ MC bodies [arrow] (H&E, x400).

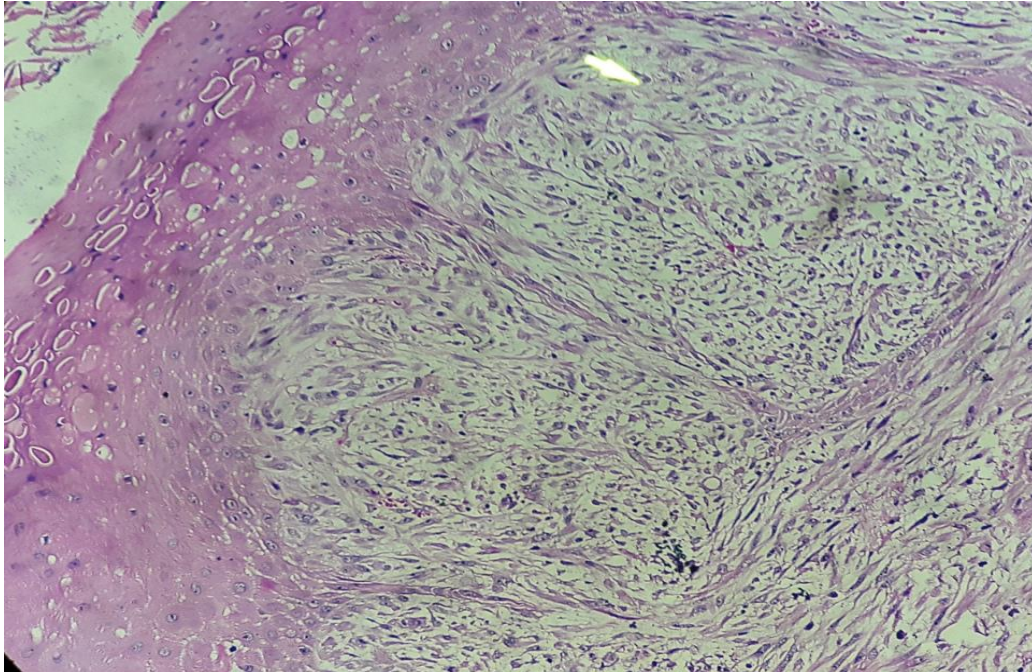


Fig.3: Micro-photograph-Gum biopsy shows acanthotic, partly ulcerated stratified squamous epithelial lining with MC bodies and post-radiation change of sub-epithelial spindled soft tissue tumor [arrow] (H&E, x400).

III. Discussion

MC is common skin infection by pox-virus group that measures 300 nm in its greatest diameter⁽³⁾. It rarely involves unusual sites like gum, as this leucopenic case with sub-epithelial post-radiation soft tissue tumour.

According to Scherer et al. (2009), the clinical features of MC in immunocompromised (IC) individuals differ from those seen in immunocompetent patients. The MC infective lesions in IC cases are not only more in number but also are not amenable for spontaneous resolution compared to those in immunocompetent patients⁽⁴⁾.

The breach in the oral epithelium and leucopenia must have prompted this pox-virus infection in this case. The viral particles stimulate mitotic activity of the basal germinal layers of lining oral epithelium. The MC virus proliferates in the prickle and granular layers of infected oral squamous layers causing acanthosis. MC bodies formed contain the virus and start as intra-cytoplasmic eosinophilic bodies above the basal layer and increase in size as they reach the surface of oral lining epithelium. Clinically a depression is formed generally late in the infection due to release of these virions from the breached/ ulcerated stratum corneum/epithelium^(3,5-7). We instead had an atypical ulcero-proliferative growth in the gum.

MC infection produces an incubation period that ranges from two weeks to three months. Though most lesions are asymptomatic and are seen as elevated papules, they seldom develop central crater-like depression filled with desquamated keratin. Complications that can arise from these MC lesions include secondary bacterial infection, foreign-body reactions^(1,3). Our case had no such complication. However we had an atypical ulcero-proliferative MC lesion with post-radiation sub-epithelial soft tissue tumour in prior operated case of intra-oral malignancy which makes our case unique [Table 1].

Table 1: Cases of ‘intra-oral’ molluscum contagiosum : reported in literature

Reference with no.	Year	Age(y)/Sex	Intraoral location	Skin involvement	Condition associated	Treatment
Schiff ⁽⁸⁾	1958	43/F	Labial mucosa	No	Normal	Not reported
Laskaris and Sklavounou ⁽⁵⁾	1984	27/M	Buccal mucosa	Trunk	Normal	Excisional biopsy
Svirsky et al. ⁽⁹⁾	1985	32/M	Lower labial mucosa	No	Normal	Excisional biopsy + spontaneous involution
Whitaker et al. ⁽³⁾	1991	52/M	Hard palate	Supra-pubic	Normal	Excisional biopsy + spontaneous involution
Fornatora et al. ⁽¹⁰⁾	2001	52/M	Maxillary gingiva	No	HIV+	Excisional biopsy
Scherer et al. ⁽⁴⁾	2009	70/F	Retromolar region	No	Normal	Excisional biopsy
Carvalho et al. ⁽¹⁾	2011	13/F	Lower labial mucosa	No	Normal	Excisional biopsy
<i>Present case *</i>	2018	52/M	Right gingiva (mandibular)	No	Intra-oral post-radiation soft tissue tumor	Excisional biopsy

Financial support and sponsorship: Nil.

Conflicts of interest: There are no conflicts of interest.

Acknowledgment: Our rising sun / son, Vihaan Bhushan Warpe for his selfless love, as we wrote this report.

References

- [1]. de Carvalho CH, de Andrade AL, de Oliveira DH, Lima Ed, da Silveira EJ, de Medeiros AM. Intraoral molluscum contagiosum in a young immunocompetent patient. *Oral Surg Oral Med Oral Pathol Oral Radiol.* 2012;114(1):e57-60.
- [2]. Sanfilippo AM, Barrio V, Kulp-Shorten C, Callen JP. Common pediatric and adolescent skin conditions. *J Pediatr Adolesc Gynecol* 2003;16:269-83.
- [3]. Whitaker SB, Wiegand SE, Budnick SD. Intraoral molluscum contagiosum. *Oral Surg Oral Med Oral Pathol* 1991;72:334-6.
- [4]. Scherer P, Fries J, Mischkowski RA, Neugebauer J, Scheer M, Zöller JE. Intraoral molluscum contagiosum imitating a squamous-cell carcinoma in an immunocompetent person—case report and review of the literature. *Int J Oral Maxillofac Surg* 2009;38:802-5.
- [5]. Laskaris G, Sklavounou A. Molluscum contagiosum of the oral mucosa. *Oral Surg Oral Med Oral Pathol* 1984;58:688-91.
- [6]. Ficarra G, Cortis S, Rubino I, Romagnoli P. Facial and perioral molluscum contagiosum in patients with HIV infection. *Oral surg oral Medicine J Oral Pathol* 1994;78:621-6.
- [7]. Neville BW, Damm DD, Allen CM, Bouquot JE. Epithelial pathology and viral infections. In: Neville BW, Damm DD, Allen CM, Bouquot JE, editors. *Oral and maxillofacial pathology.* 3rd ed. Philadelphia: Saunders; 2008.
- [8]. Schiff B. Molluscum contagiosum of the buccal mucosa. *Arch Dermatol* 1958;78:90.
- [9]. Svirsky JA, Sawyer DR, Page DG. Molluscum contagiosum of the lower lip. *Int J Dermatol* 1985;24:668-9.
- [10]. Fornatora ML, Reich RF, Gray RG, Freedman PD. Intraoral molluscum contagiosum: a report of a case and a review of the literature. *Oral Surg Oral Med Oral Pathol Oral Radiol Endod* 2001;92:318-20.

Bhushan M. Warpe. "Intra-Oral Molluscum Contagiosum with Post Radiotherapy Low Grade Soft Tissue Tumor in An Old Operated Case Of Intra-Oral Malignancy." *IOSR Journal of Dental and Medical Sciences (IOSR-JDMS)*, vol. 18, no. 3, 2019, pp 04-07.