

Diverse Presentations of Cutaneous Metastasis of Breast Carcinoma – A Case Series

Srinu Chandra Tiragati¹, V. Nivedita Devi²

¹(Department of Dermatology venereology and leprosy, Rangaraya Medical College/ N.T.R. University, India)

²(Department of Dermatology venereology and leprosy, Rangaraya Medical College/ N.T.R. University, India)

Corresponding Author: Srinu Chandra Tiragati

Abstract: Cutaneous metastasis of internal malignancy may herald the onset, dissemination or recurrence of malignancy. Breast carcinoma is encountered by dermatologists which presents in various morphological and histological forms. Here, we present 3 cases of cutaneous metastasis of breast carcinoma with different presentations.

Key Words: Carcinoma Erysipeloides, Breast Carcinoma, Cutaneous Metastasis

Date of Submission: 29-01-2019

Date of acceptance: 14-02-2019

I. Introduction

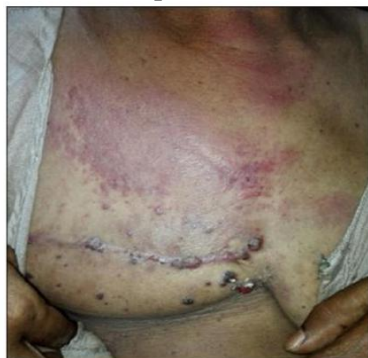Cutaneous metastases account for 0.7- 9% of all metastases¹. They may be the first evidence of internal malignancy or a sign of recurrence. The clinical diagnosis must be substantiated by histopathological examination. Always a high degree of suspicion should be present to the dermatologist because of varied morphological presentations of cutaneous metastases.

II. Case Presentations

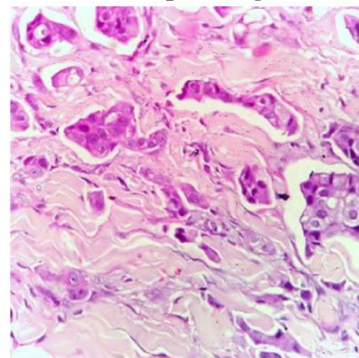
Case Report-1:

- History: A 55-year-old female presented with painful red rash over right breast since 15 days. She underwent modified radical mastectomy for Ductal Carcinoma of breast 1 year back and received 3 cycles of chemotherapy and radiotherapy.
- On examination: A tender erythematous plaque of size 15x10cms is present over right mammary region and multiple erythematous papules and nodules along mastectomy scar.
- Clinical differential diagnosis: Carcinoma Erysipeloides, Erysipelas, Radiation dermatitis.
- Histopathology: Epidermis showed presence of lymphocytes focally. Dermis showed clusters of round to oval cells with Pleomorphism, high Nuclear: Cytoplasmic ratio showing attempted glandular pattern. There is plugging of dermal lymphatics by aggregates of carcinoma cells representing malignant deposits of Adenocarcinomatous nature and features suggestive of Carcinoma Erysipeloides.

Clinical picture



Histopathological

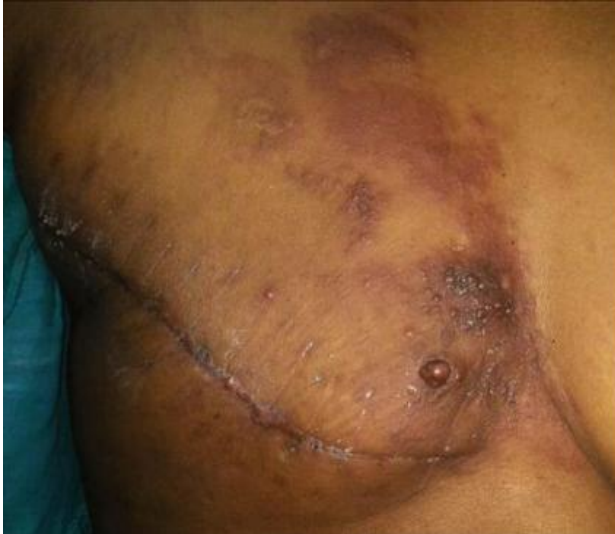

Case Report-2:

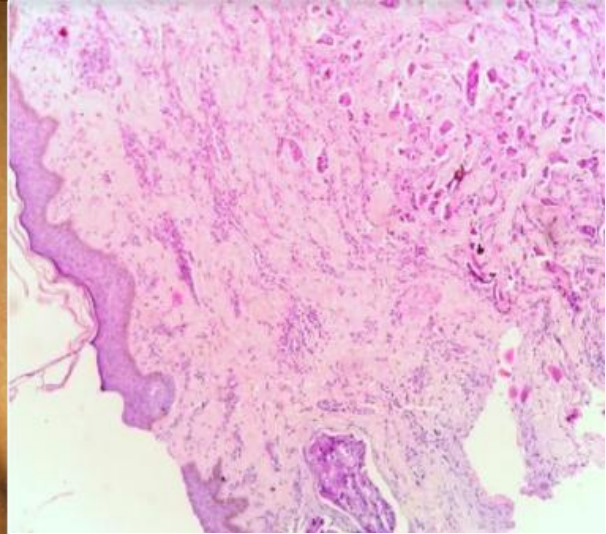
- History: A 65-year-old female presented with asymptomatic raised hard lesions over mastectomised region since 1 month. She had undergone modified radical mastectomy 9 months back for invasive duct cell carcinoma of breast.

- On examination: Multiple erythematous to hyper pigmented hard nodules present over right mammary region.
- Clinical diagnosis: Nodular cutaneous metastases.
- Histopathology: Suggestive of nodular metastasis from Duct cell carcinoma.

Clinical picture



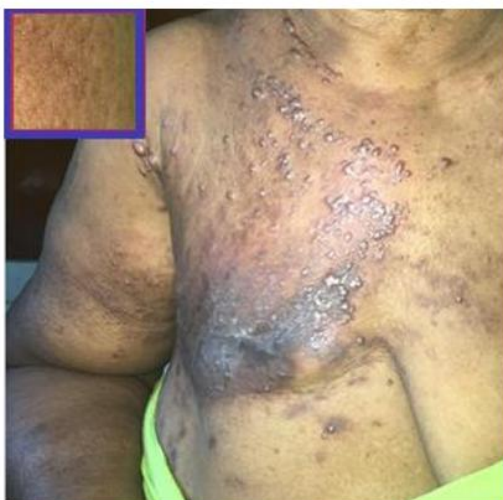Histopathological



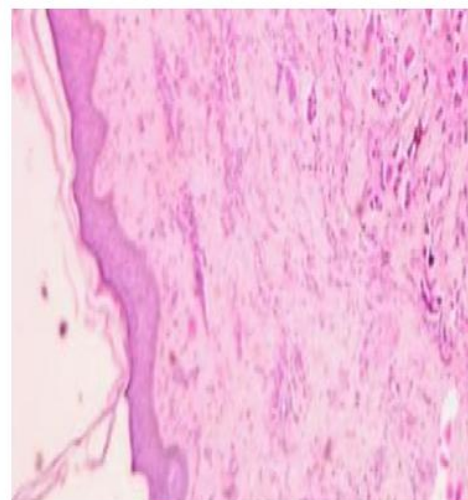
Case Report-3:

- History: A 50-year-old female presented with asymptomatic raised lesions over mastectomised region since 2 months and increase in size of right upper limb since 1 month. She had undergone modified radical mastectomy 1 year back for invasive ductal carcinoma.
- On examination: Multiple erythematous papules and nodules over right mammary area and enlarged right upper arm with Peau D'Orange appearance is present.
- Clinical diagnosis: Papulonodular metastasis with lymphedema of right arm.
- Histopathology: Malignant epithelial cells arranged in clusters, sheets and focal tubular pattern, foci show lymphatic permeation which is consistent with cutaneous metastasis from duct cell carcinoma.

Clinical picture



Histopathological



III. Discussion

Metastasis to the skin is not as common as metastasis to liver, lung or bone contributing to less than 1% of total metastases. About 0.5–1% a metastasis is the presenting feature of internal cancer. Of patients with metastatic cancer, 10% have cutaneous metastases. The most common sources of cutaneous metastases are, in generally accepted order of frequency: breast, (melanoma), lung, colon, stomach, upper aero-digestive tract, uterus and kidney. There are many patterns of involvement of skin in cutaneous metastases of breast carcinoma.

They are a) Nodular (most common variant), b) Sclerotic (Carcinoma en Cuirasse), c) Telangiectatic (Carcinoma Telangiectodes), d) Infiltrating (Peau D'Orange appearance), e) Alopecia neoplastica, f) Erysipelas like (Carcinoma Erysipeloides – rarer variant among all)². An unusual cutaneous manifestation of breast and ovarian malignancy is carcinoma erysipeloides, which presents with features of cellulitis and is due to metastases within the skin^{3,4}. The clinical progression usually involves rapid enlargement of the affected area without skin ulceration⁵. It is important to differentiate it from erysipelas, which is an infection commonly due to Group A-hemolytic streptococci because of the difference in management and implications. Prompt recognition of skin metastases allows for earlier intervention in treating the systemic spread of the disease⁶. Histologically there is plugging of dermal lymphatics at all levels by aggregates of carcinoma cells². Clinical diagnosis of metastases is substantiated by histopathological examination. Direct invasion of the skin from a deeper tumour usually causes papular, nodular infiltration and ulceration.

IV. Conclusion

Although the most common carcinoma to metastasize to the skin is melanoma, followed by breast carcinoma, cutaneous metastases from breast carcinoma are commonly encountered in clinical practice and hence dermatologists should have a high index of suspicion. Here, with these case reports, we want to highlight a point that though short duration of onset and tender erythematous plaque presentation in carcinoma erysipeloides may mimic infective origin, we have to keep metastases as first possible differential diagnosis.

References

- [1]. Naser AM, Zaki MS, Brunner M, Wollina V, Zouboulis CC. Cutaneous metastasis in internal malignancy. *Egypt Dermatol Online J.* 2007;3:1.
- [2]. Rooks text book of dermatology 9th edition, Cutaneous metastases from carcinoma breast: The common and the rare, Smitha Prabhu, Sathish B Pai, Year: 2009 | Volume: 75 | Issue : 5 | Page : 499-502.
- [3]. Lever LR, Holt PJ. Carcinoma erysipeloides. *British journal of dermatology.* 1991 Mar;124(3):279-82.
- [4]. Nambi R, Tharakaram S. Carcinoma erysipeloides as a presenting feature of breast carcinoma. *International journal of dermatology.* 1999 May;38(5):367-8.
- [5]. Homler HJ, Goetz CS, Weisenburger DD. Lymphangitic cutaneous metastases from lung cancer mimicking cellulitis. *Carcinoma erysipeloides.* *Western Journal of Medicine.* 1986 May;144(5):610.
- [6]. Nava G, Greer K, Patterson J, Y Lin K. Metastatic cutaneous breast carcinoma: a case report and review of the literature. *Canadian Journal of Plastic Surgery.* 2009 Mar;17(1):25-8.

Srinu Chandra Tiragati. "Diverse Presentations of Cutaneous Metastasis of Breast Carcinoma – A Case Series." *IOSR Journal of Dental and Medical Sciences (IOSR-JDMS)*, vol. 18, no. 2, 2019, pp 41-43.