

“A Study of Surgical Management of Intra Articular Fractures of Distal Humerus in Adults”

Dr.P.Kiran kumar¹, Dr.Ramana.S.S.V², Dr.S.Tulasiram yashaswi³,

Assistant Professor, Department of Orthopaedics, Guntur medical college, Guntur, Andhra Pradesh, India

Professor, Department of Orthopaedics, Guntur medical college, Guntur, Andhra Pradesh, India

Consultant Orthopaedic surgeon, Yashaswi Hospitals, Guntur

Corresponding Author: Dr.P.Kiran kumar

AIM: The aim of the study was to evaluate the functional results of surgical management of distal humerus fractures in adults involving the articular surface.

PATIENTS AND METHODS: This is a prospective study of 30 cases of distal humerus fractures in adults involving the articular surface who are admitted to Guntur government hospital between November 2012 and September 2014. Cases were taken according to inclusion and exclusion criteria.

RESULTS: In our study 30 cases were treated. 25 were males and 5 patients were females. The mean age was 35 years. 63.33% of the fractures were road traffic accidents and 36.67% were due to trivial fall with right side being more commonly affected. Riseborough and Radin Type 3 fractures accounted for 53.33% of cases and type 4 accounted for 46.67%. Out of 30 cases Excellent to Good results were seen in 80% of cases in our study according to Mayo Elbow score.

CONCLUSION: From our study we conclude that for a successful internal fixation of distal humerus fractures, it is necessary to maintain anatomic and stable reconstruction of the articular surface and of both humeral columns using two parallel or 90-90° plates.

Date of Submission: 26-01-2019

Date of acceptance: 09-02-2019

I. Introduction

Distal humerus fractures are uncommon injuries that account for fewer than 2% of all adult fractures. The complex shape of the elbow joint, the adjacent neurovascular architecture, and the sparse soft tissue envelope combine to make these fractures difficult to treat. Acceptable results have been reported in a majority of patients treated by open reduction and internal fixation.

Restoration of painless and satisfactory elbow function after a fracture of the distal humerus requires anatomic reconstruction of the articular surface, restitution of the overall geometry of the distal humerus, and stable fixation of the fractured fragments to allow early and full rehabilitation.

Depending upon the amount of comminution and displacement, open reduction and internal fixation with Y plate, 1/3 tubular plate, reconstruction plate, cancellous screws, K wire and double tension band wiring can be done individually or in combination.

The aim of the present study is to evaluate the functional outcome of surgical management of distal humerus with intra articular extension in adults.

AIMS AND OBJECTIVES:

Assessment of the functional results of surgical management of distal humerus fractures in adults involving the articular surface.

II. Methodology

Source of Data:

Adult patients having Distal humerus fractures involving articular surface who are admitted to Guntur government hospital attached to Guntur Medical College will be taken up for study after obtaining their informed written consent. This is a prospective study from November 2012 and September 2014.

Method of collection of Data:

Collection of data for patients presenting with fracture of Distal humerus are as follows:-

- History by Verbal communication
- Clinical examination, both local and systemic.
- Radiological examination routine and other imaging modalities
- Investigation baseline and others
- Fracture anatomy assessed with X-rays
- Diagnosis—Clinical and radiological
- Informed written consent will be taken for surgical procedure
- Surgery –open reduction and internal fixation
- Post operative treatment:-
- Routine antibiotic and analgesic.
- evaluation by Xrays- AP view
- Assessment at 6weeks,12weeks and 6months by radiological assessment and clinical union and functional ability of the elbow using Mayo elbow performance score.

Inclusion criteria:

- Male and female adult patients with closed Distal humerus fracture involving the articular surface who have given their consent for the procedure.
- Patients who are medically fit for surgery.

Exclusion criteria:

- Patients medically unfit for surgery
- Patients not willing for surgery
- Patients below 18 years of age
- Compound fractures are not included.

Pre-Operative Planning:

- Consent of the patient or relative was taken prior to surgery
- A dose of tetanus toxoid and antibiotic were given preoperatively
- Preparation of part was done before a day of surgery
- The injured elbow was immobilized in slab during preoperative period
- Instruments to be used were checked before hand and sterilized

Position:

Pneumatic tourniquet is recommended Patient in lateral position with arm supported and forearm hanging In all patients a posterior trans-olecranon approach was used to give better exposure of the articular surface.

Operative procedure:

The distal end of humerus was approached using trans-olecranon approach Elbow was exposed posteriorly through an incision beginning 5cm distal to the tip of the olecranon and extending proximally midline of the arm 8cm above the tip of the olecranon Reflected the skin and subcutaneous tissue to either side carefully to expose the olecranon and triceps tendon. The ulnar nerve is isolated and fascia over the flexor carpi ulnaris is longitudinally split over 6cm to enhance the nerve mobility. Then gently retracted from its bed with a moist tape.

Distal end of humerus is exposed through Transolecranon approach Prior to performing the olecranon osteotomy the proximal ulna was predrilled with 3.2mm bit and then partially tapped for a 6.5mm AO cancellous bone screw. An intra-articular olecranon osteotomy was made in a shallow V or Chevron fashion in the centre of the olecranon sulcus that is 2cm from tip of olecranon.

The location was best identified by elevation of anconeus muscle on the olecranon to directly visualize the articular surface. A sponge was placed from lateral to medial and used as a countertraction of osteotomy created with thin bladed oscillating saw and completed with a thin bladed osteotome.

The osteotomized olecranon fragment was elevated proximally leaving a margin of triceps tendon on either side to suture upon completion of the surgery

Fragments of the humerus were assembled in 3steps:

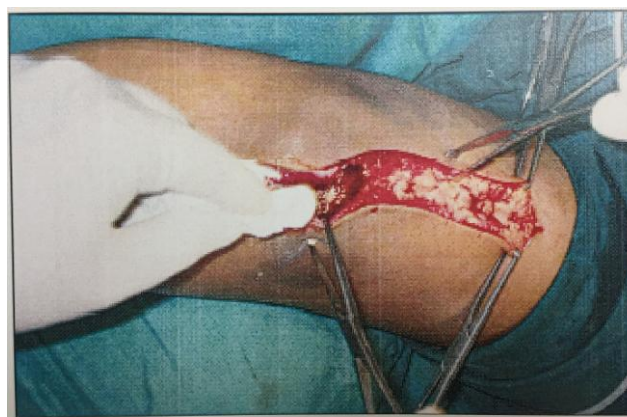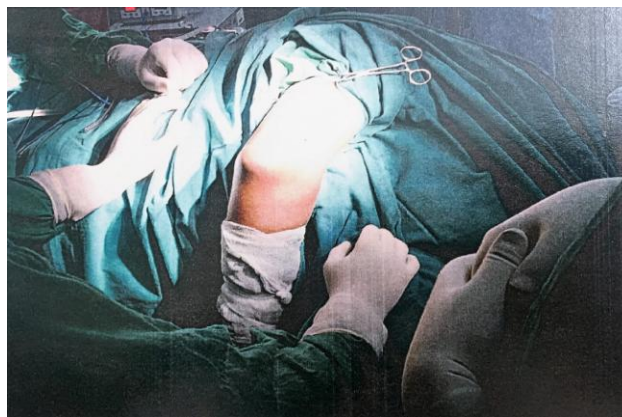- 1) Reduction and fixation of condyle together
- 2) Fix the medial or lateral epicondylar ridge to the humeral metaphysis, if it is fractured
- 3) Reassembled condyles are fixed to the humeral metaphysis

Reduction and fixation of condyles;

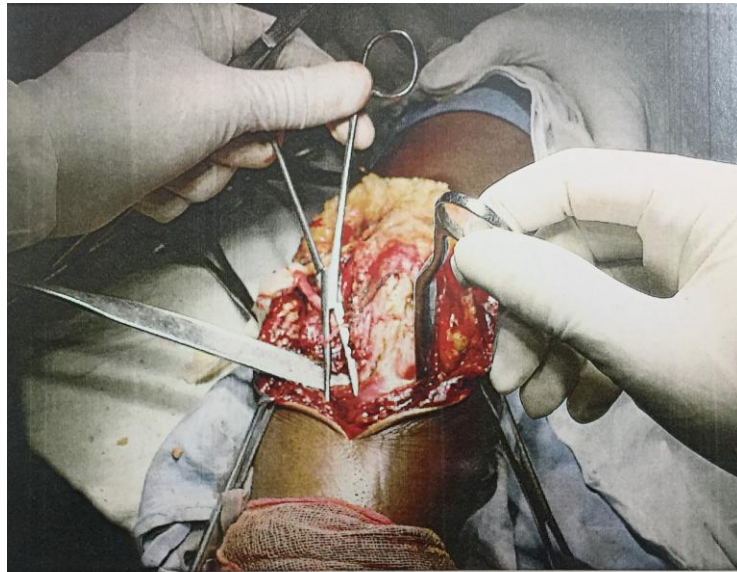
- ✓ Condyles were reduced and held with a bone holding clamp
- ✓ Reduced condyle was provisionally fixed with Kirschner wire
- ✓ AO cancellous screw was inserted across the reduced condyles
- ✓ Reduction and fixation of condyles to metaphysis
- ✓ Reduction and temporary stabilization of the medial and lateral columns was done by using Kirschner wire
- ✓ Medial and lateral pillars were reconstructed using contoured 3.5mm reconstruction plate and screws
- ✓ To enhance the mechanical strength the plates were placed as close to 90° to each other as possible
- ✓ The stability of the internal fixation was tested by putting the elbow through a range of motion
- ✓ The olecranon osteotomy was reduced under direct vision and held with reduction clamp. A 6.5mm AO cancellous screw was introduced from the tip of the olecranon. Periosteum was stripped from the shaft of the ulna distal to osteotomy site and transverse hole was drilled approximately 3-5cm distal to osteotomy site. A no.16 stainless steel malleable wire passed through thin transverse hole and crossed over the posterior surface of the olecranon in a figure of eight and then passed around the neck of the screw and tightened. Instead of 6.5mm AO cancellous screw with tension band wiring, it can also be fixed with tension band wiring with obliquely placed Kirschner wire.
- ✓ At the completion of fixation the elbow was again put through a range of motion to test the security of internal fixation
- ✓ Tourniquet was let down and hemostasis carefully secured over a large suction drain and the wound was closed in layers
- ✓ Limb was immobilized with above elbow POP slab.

Follow-up:

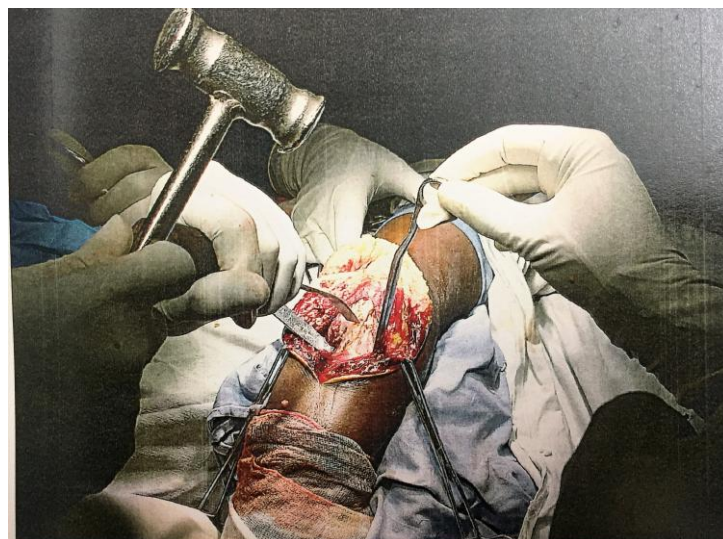- ✓ Patients were advised to report for follow-up after 6 weeks and 12 weeks and thereafter every 3 months. The results were assessed 3 and 6 months after the procedure.
- ✓ At follow up a detailed clinical examination was done and patients were assessed subjectively for the symptoms like pain, swelling and restriction of joint motion
- ✓ Physiotherapy was given in the form of active flexion-extension and pronation-supination without loading.
- ✓ Functional assessment of the patient was done according to Mayo elbow performance score



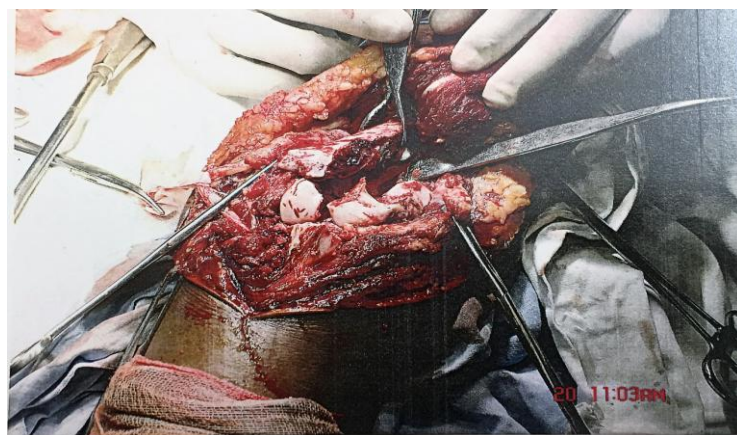
Posterior – Midline Incision



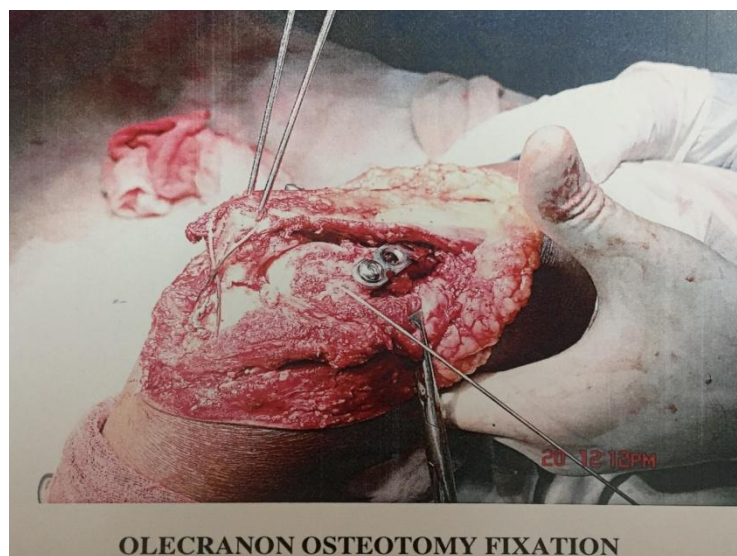
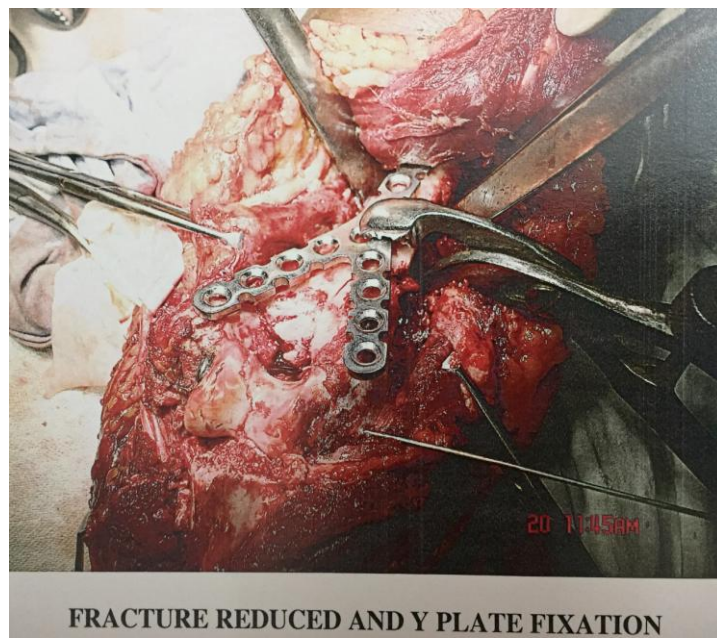
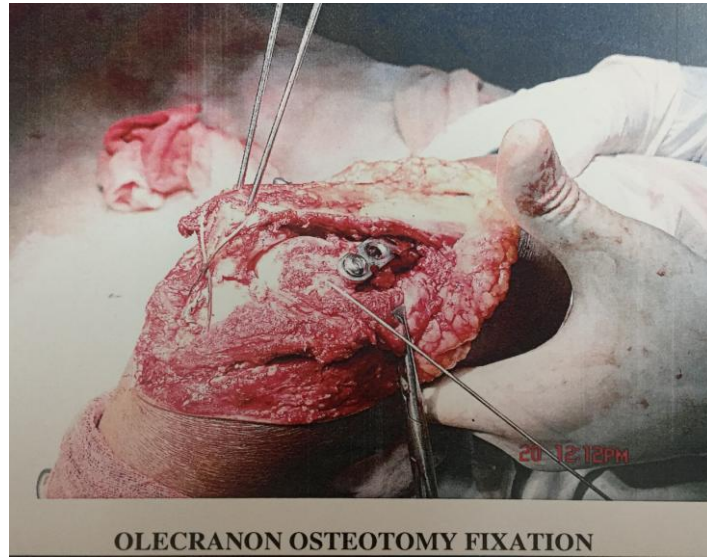
ULNAR NERVE ISOLATED

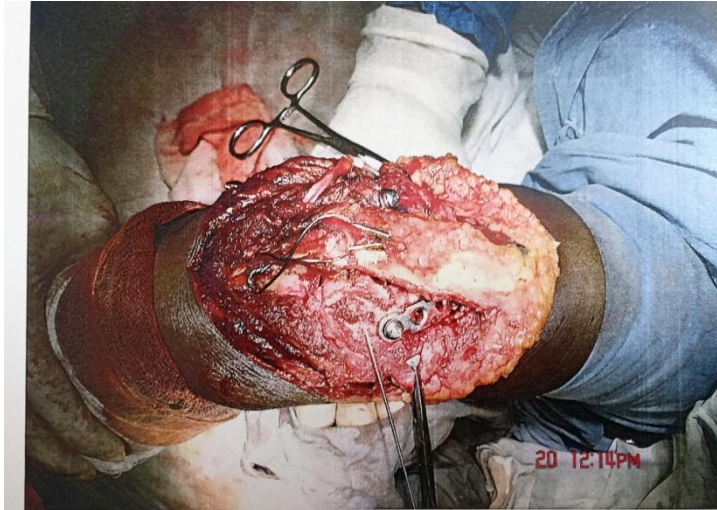


OLECRANON OSTEOTOMY

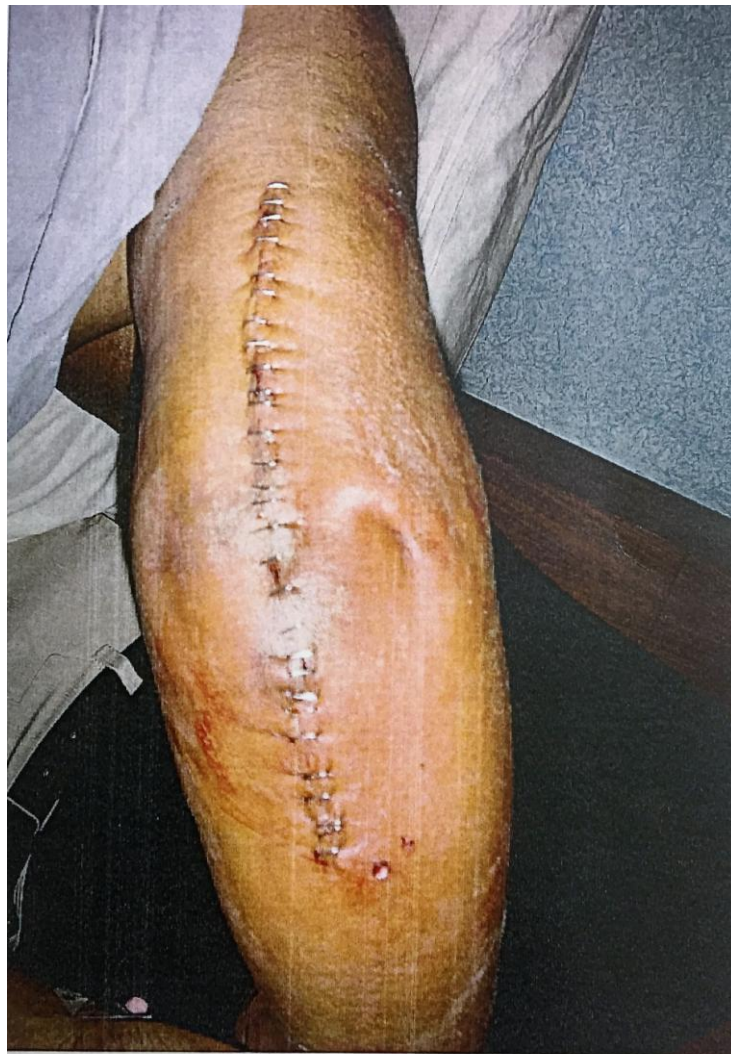

TRICEPS REFLECTED AND FRACTURE SITE EXPOSED





TENSION BAND WIRING OF OLECRANON AND FRACTURE



SKIN CLOSURE

III. Results

The study consists of Adult patients having distal humerus fractures involving articular surface who are admitted to Guntur government hospital attached to Guntur medical college after obtaining their informed written consent. This is a prospective study from November 2012 to September 2014.

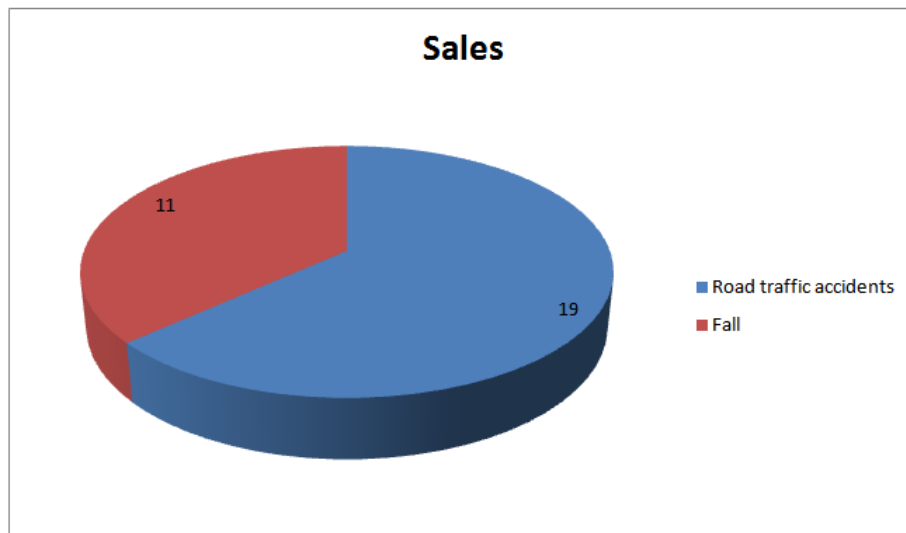
Table 1: Age group

Age group	No. of patients
18-20	5
21-30	9
31-40	6
41-50	6
51-60	4

Table 2: Sex Incidence

Sex	No. of Patients
Males	25
Females	5

Table 3: Mode of Injury



In the study, we found that road traffic accidents were the most attributing to 19(63.33%) and Fall 11(36.67%).

Table 4: Side Involvement

Side	No. of Patients
Left	14
Right	16

Table 5: Type of Fracture

Type of Fracture	No. of Patients
Type 3	16
Type 4	14

Table 6: Complications

Complication	Type of fixation
Superficial infection	1
Non Union	1
Ulnar Neuropraxia	1
Implant Failure	1

Table 7: Type of fixation

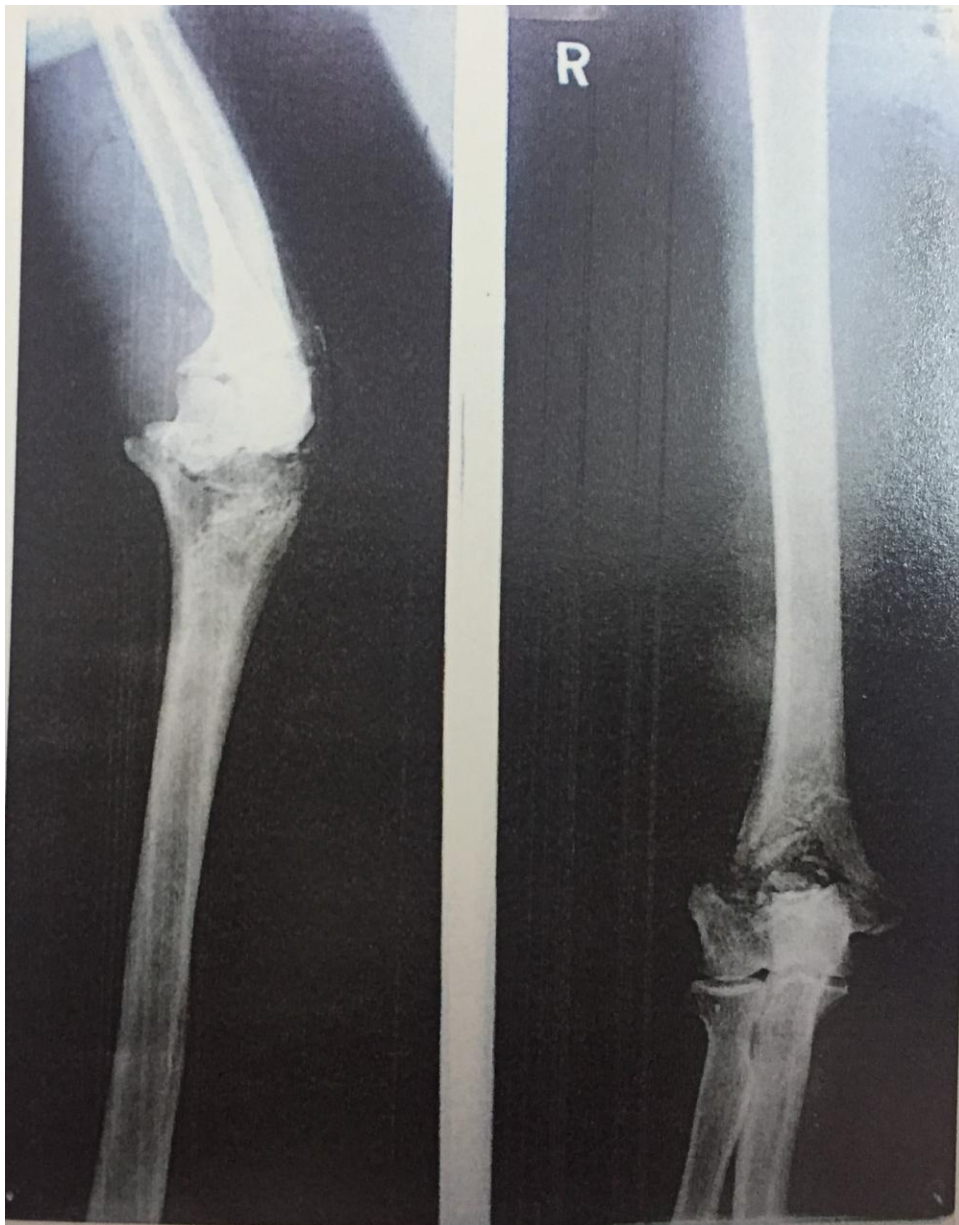Type of fixation	Type of fixation
Plate	24
Y plate	6

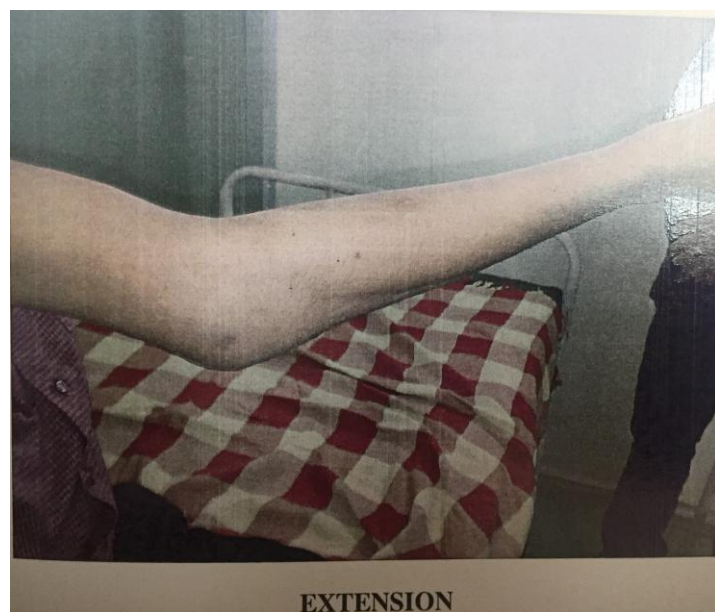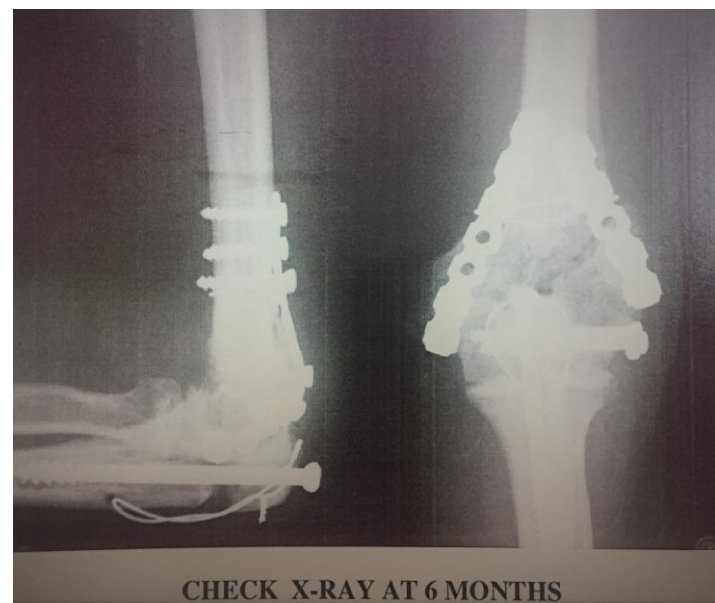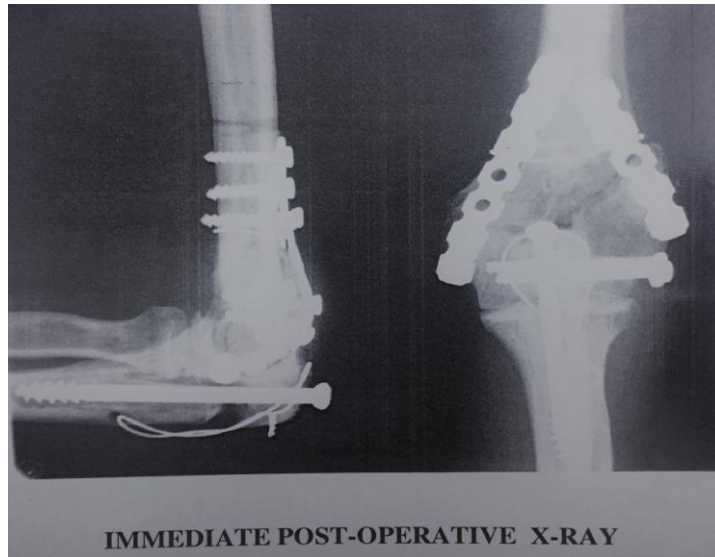Table 8: Grading of results

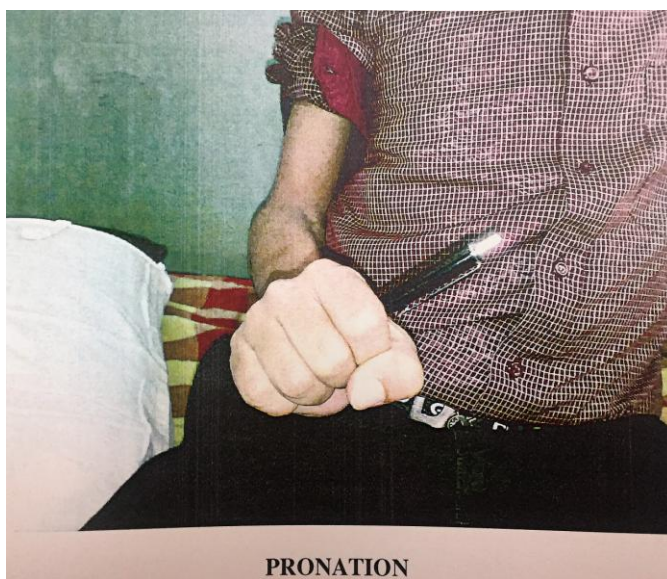
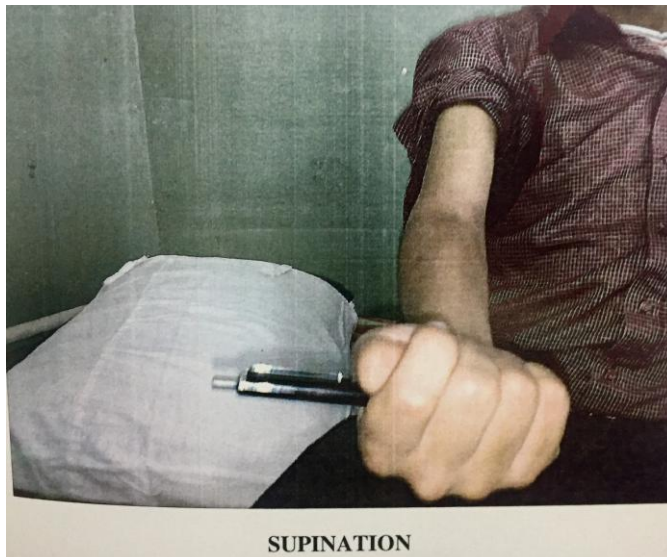
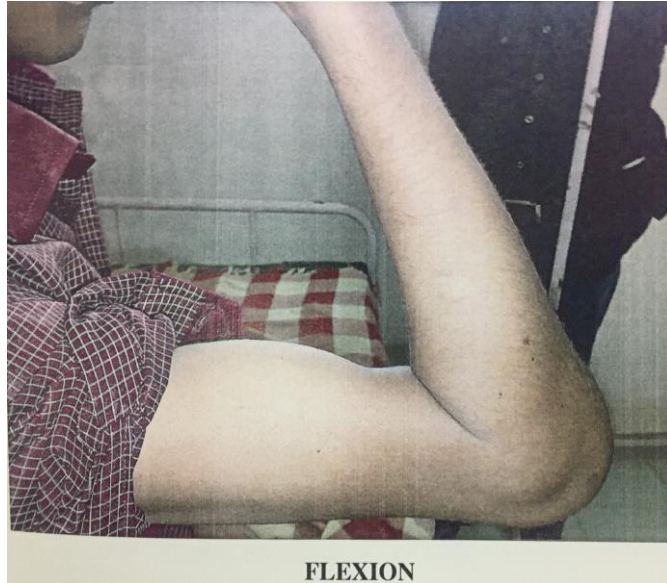
Results	No.of Patients
Excellent	4
Good	20
Fair	4
Poor	2

Case 1

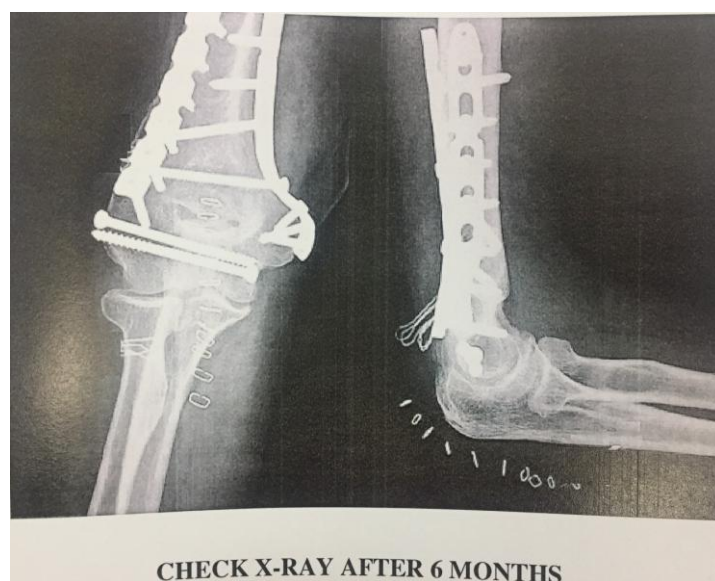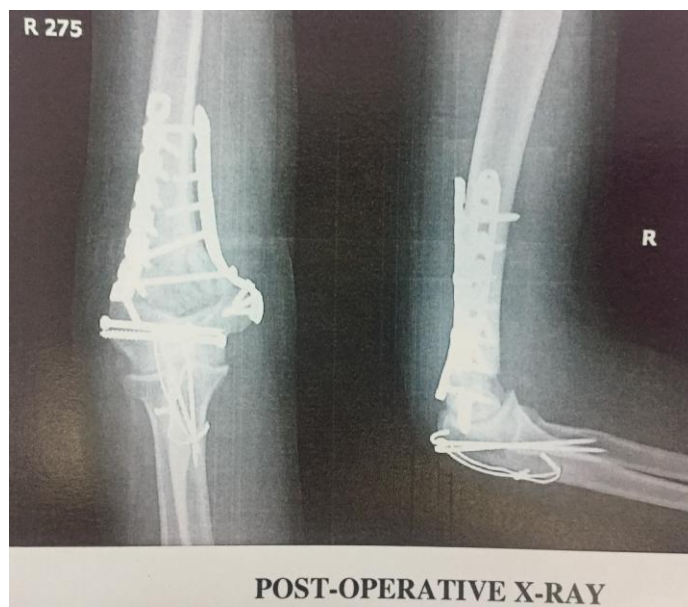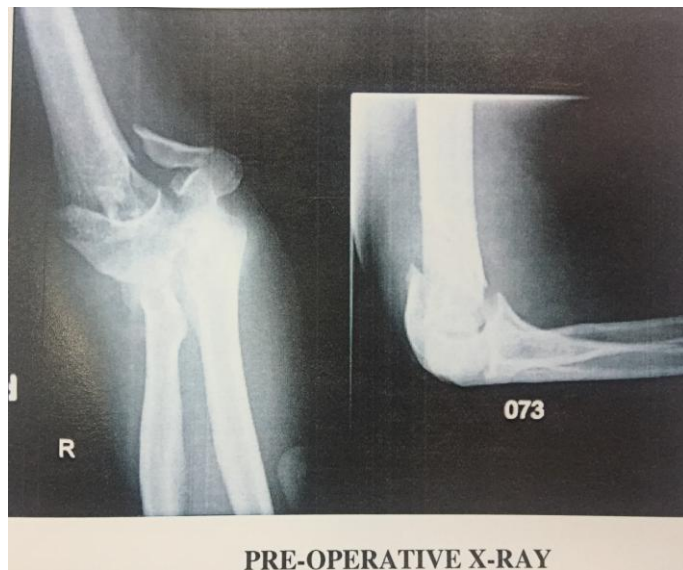Pre-op X-ray

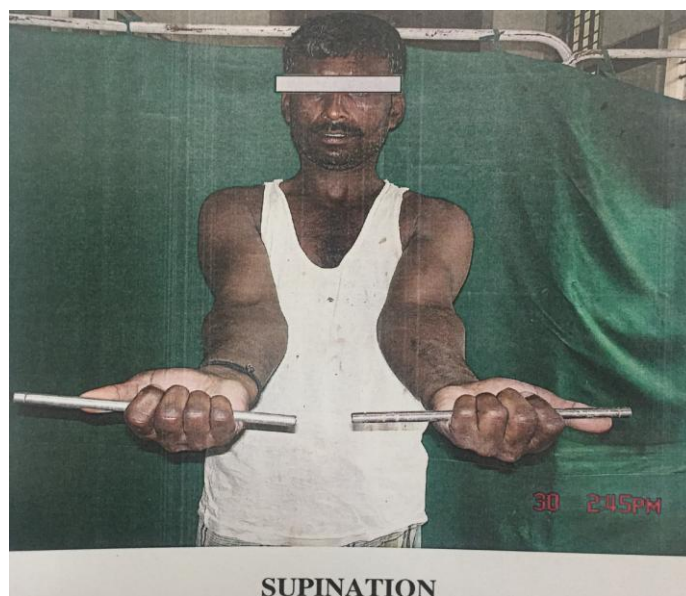
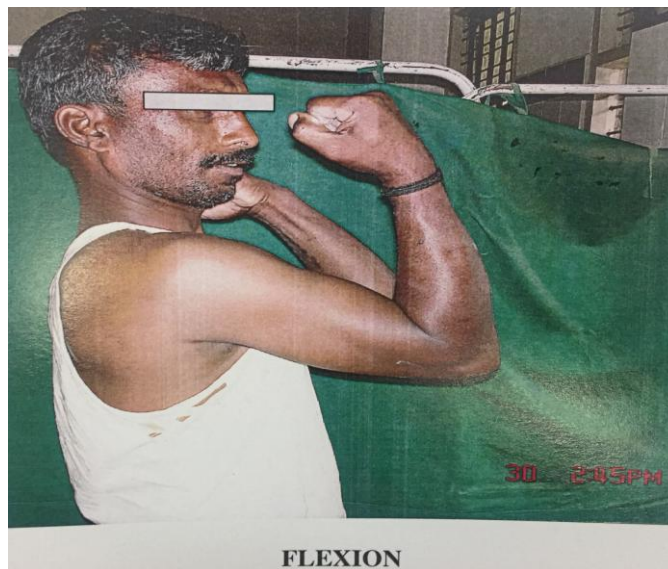
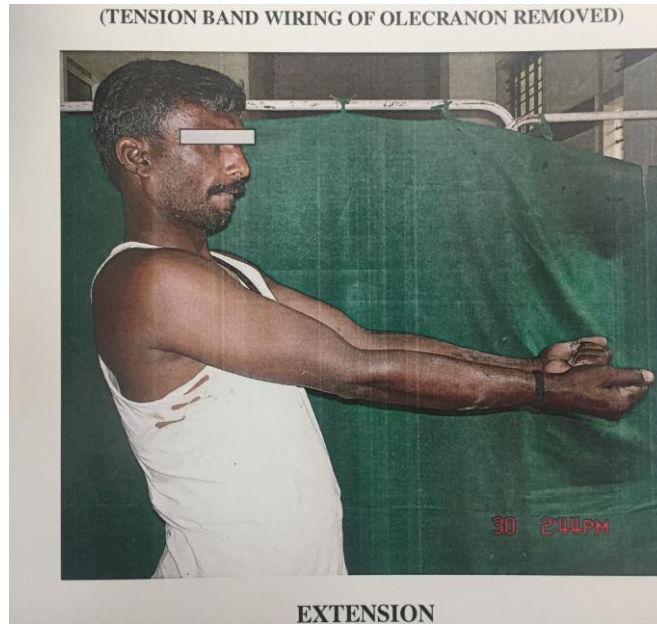


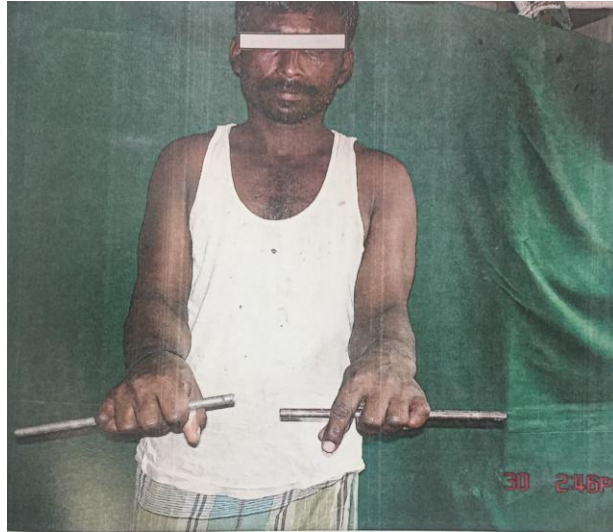



Case 2

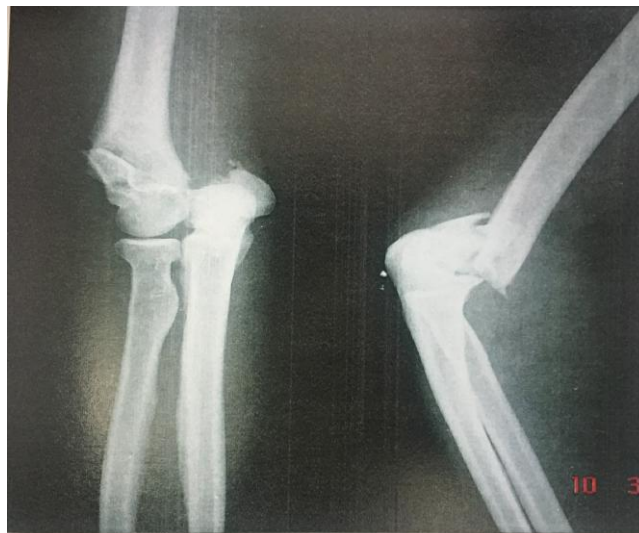



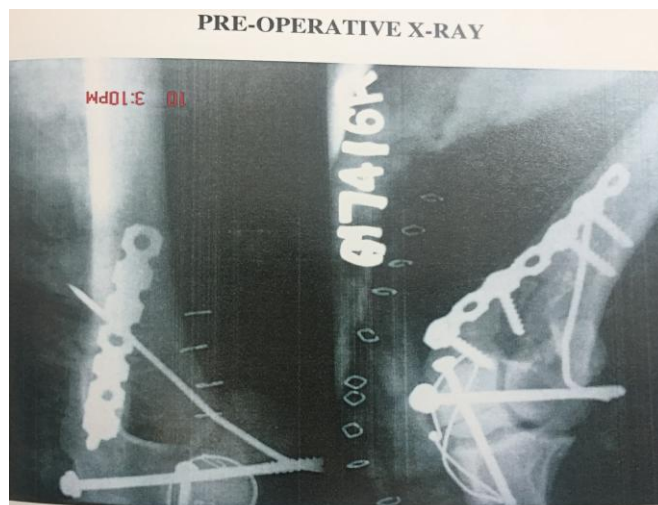


PRONATION

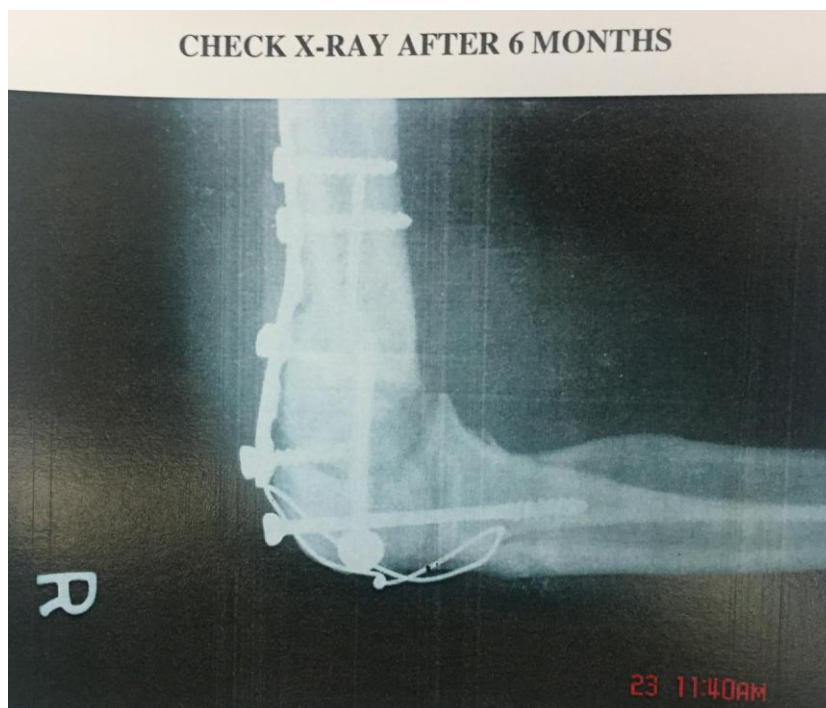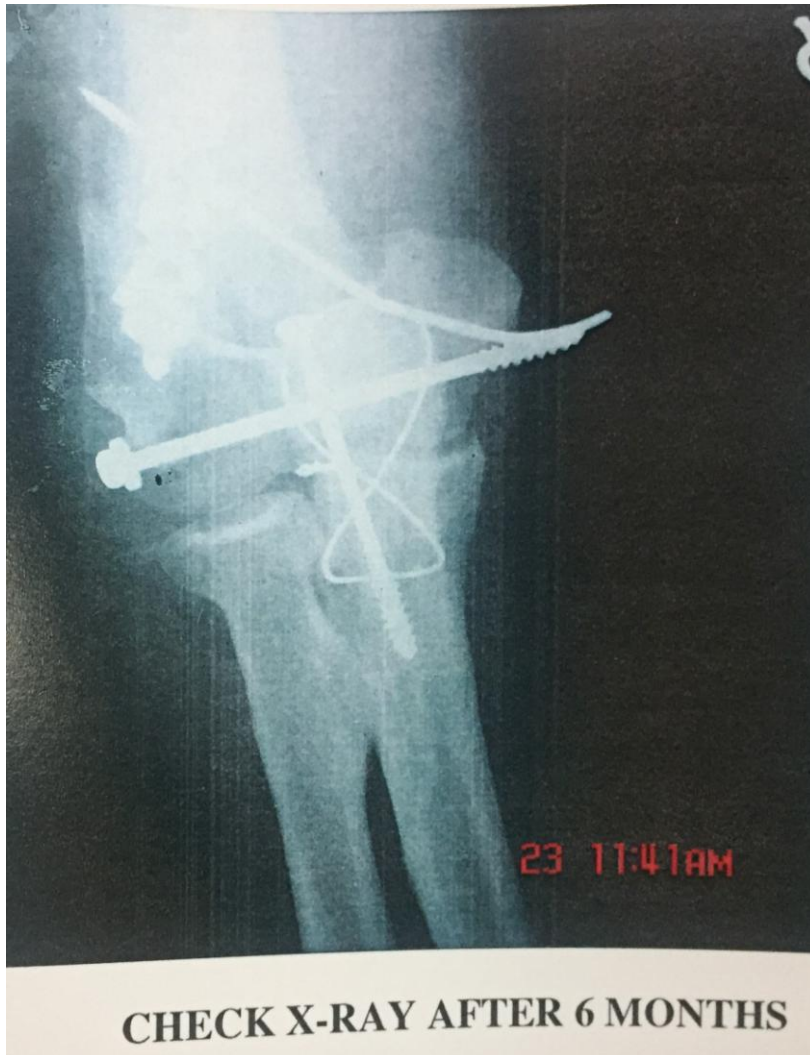Case 3

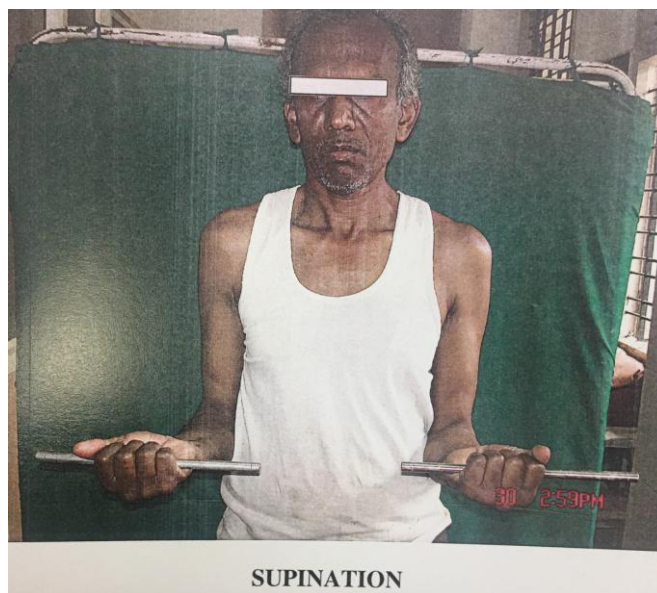
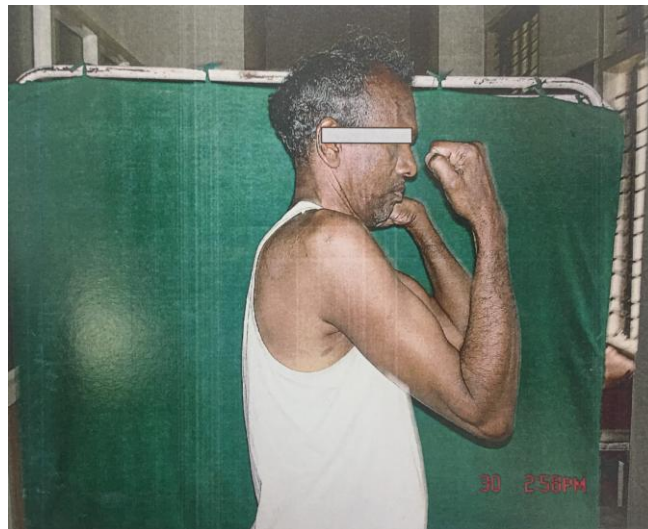
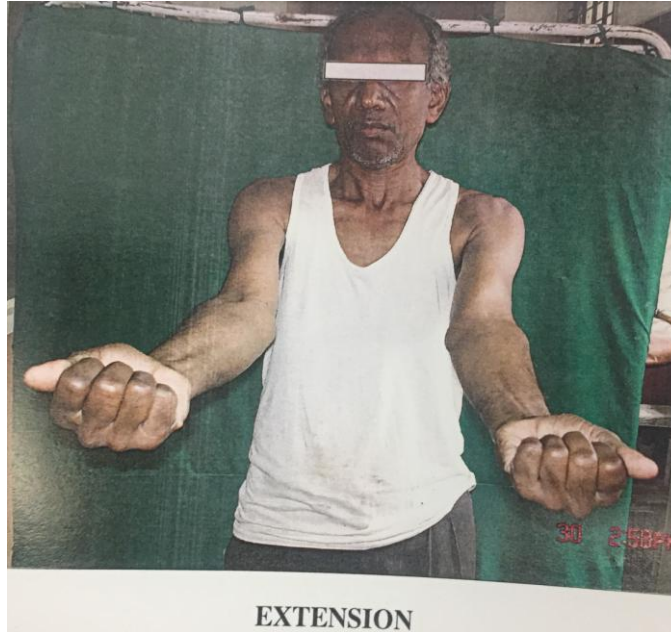



PRE-OPERATIVE X-RAY



POST --OPERATIVE X-RAY







IV. Discussion

In our study 24 cases of intercondylar fractures of distal humerus were treated with two 3.5mm reconstruction plate and 6 cases of intercondylar fractures of distal humerus were treated with Y plate. Our experience with these methods of fixation has given favorable results.

Age incidence:

In our study fractures were commoner in 2nd and 3rd decade with average age being 35years(18-60).

Sex:

In our study there were 25 male patients(83.33%) and 5 female patients(16.67%).

Mechanism of injury:

In our series 36.67% of the cases were due to direct fall and 63.33% of cases had road traffic accident

Type of fractures(Riseborough and Radin classification)

In our series we accounted no cases of fractures of RR type 1 and RR type 2, 53.33% fractures of RR type 3 and 46.67% fractures of RR type 4.

Study	RR type 1	RR type 2	RR type 3	RR type 4
M.Bradford et al(1987)	3(9%)	4(12%)	14(43%)	12(36%)
Our study	-	-	16(53.33%)	14(46.67%)

Functional outcome:

In our study functional outcome based upon Mayo Elbow performance Score is excellent in 4 patients(13.33%),good in 20 patients (66.67%),fair in 4 patients(13.33%),poor in 2 patients(6.67%).

Our study is comparable to the studies conducted by Teng-Le Huang.et.al, K.Reising et al and Ibmocha Singh et al

Study	Good/excellent scores(based on MEPS)
Teng-Le Huang.et.al(2004)	87.5%
Ibmocha Singh et al(2004)	81.8%
K.Reising et al(2009)	85%
Our study	80%

Complications:

In our series we had a case of superficial infection which resolved with appropriate antibiotics. A case of ulnar neuropraxia was seen which resolved spontaneously after conservative treatment. Our patient had a non-union, in which Y plate was removed and internal fixation with two 3.5mm reconstruction plate with bone grafting was done. Recon plate breakage occurred in one patient where re-surgery was done, broken plate was removed and two 3.5mm reconstruction plates were applied with bone grafting.

In our study Soon JL et al reported 4% superficial infection, 7% of ulnar neuropraxia, 5% of implant failure, 2% of non union and 4% incidence of Heterotropic ossification

Study	Superficial infection	Ulnar neuropraxia	Non union	Heterotropic ossification	Implant failure
Soon JL et al	6.66%	13.33%	6.66%	Nil	Nil
Our study	3.33%	3.33%	3.33%	-	3.33%

V. Summary

30 cases of intercondylar fractures treated by open reduction and internal fixation with two 3.5mm reconstruction plate or Y-plate in Guntur government hospital between November 2008 to September 2010. All patients underwent surgery, various parameters like age, sex, side involvement, mechanism of injury, type of fracture were analysed. Surgical procedure carried out in all 30 patients.

- In the present study maximum number of patients were found to be in second and third decade
- There was a significant male predominance in the present study 25 patients (83.33%)
- Right side 16(53.33%) distal humerus fractures were more common than left side 14(46.67%)
- Direct fall 11(36.67%) was more common than road traffic accident 19(63.33%)
- There was no case of type-1 and type 2 fracture. 16(53.33%) cases of type 3 fracture and 14(46.67%) cases of type 4 fractures

Results were analysed according to Mayo elbow performance score. Excellent results were achieved in 13.33%, good results in 66.67% and fair results in 13.33% of the case and poor results in 6.67%. The complications like superficial infection in 1(3.33%) patients, ulnar neuropraxia in 1(3.33%) patient, non union in 1(3.33%) patients, implant failure in 1(3.33%) patients were noticed which were treated accordingly.

VI. Conclusion

In this study carried out in 30 intercondylar fractures we came to following conclusions:

- Intercodylar fractures of the humerus are common in adult males
- Common mode of injury is RTA and direct fall of elbow is next common mode
- These fractures demands careful evaluation, classification of fracture type and pre-operative planning
- Trans olecranon approach provides best visualisation of articular surface
- Open reduction internal fixation should be done as soon as possible. Delay in open reduction with delayed soft tissue dissection leads to increased chances of elbow stiffness due to periarticular fibrosis.
- For a successful internal fixation of closed distal humeral fracture, it is necessary to maintain anatomic and stable reconstruction of articular surface and of both humeral columns using two parallel 90-90° plates.
- Early vigorous, active physiotherapy is a must for good results. Stable fixation allows early, active and aggressive postoperative mobilisation

Bibliography

- [1]. 1) Ozer H, Solak S, Turanli S, Baltaci G, Colakoglu T, Bloukbasi S- Arch Orthop Trauma Surg .2006 Oct;126(8):574
- [2]. 2) Amit Pankaj, G. Mallinath, Rajesh Malhotra, Surya Bhan, "Indian J. Orthop, Surgical management of intercondylar fracture using Triceps reflecting anconeus pedicle approach, 2007, 41:219-223
- [3]. 3) Sanchez, Sotelo, Joaquin, M.D. Ph.d Torchia Michael E., Ordricoll, Shawn W.M.D. Complex distal humeral fractures internal fixation with a principle based parallel plate technique. The Journal of bone and joint Surgery 2007; 89:961-969
- [4]. 4) K. Reising, O. Hauschild, P.C. Strohm, N.P. Suedkamp- Stanilisation of articular fractures of the distal humerus: Early experience with a novel perpendicular plate system Injury Volume 40, Issue 6, Pages 611-617, June 2009
- [5]. Green A- Open reduction and internal fixation with 90-90 plating of bicolumn distal humerus fractures. I course Lect. 2009; 58:515
- [6]. Liu D, Li P.- investigate the method and clinical effect of double plating fixation in treatment of distal humerus fractures. Orthopaedic Center, Urumchi Xinjiang, P.R. China: Zhongguo Xiu Fu Chong Jian Wai Ke Za Zhi. 2010 Jun; 24(6):680-2

Dr.P.Kiran kumar. “A Study of Surgical Management of Intra Articular Fractures of Distal Humerus in Adults”. IOSR Journal of Dental and Medical Sciences (IOSR-JDMS), vol. 18, no. 2, 2019, pp 01-17.