

Facial Deformity With 16 Mm Reverse Overjet Treated By Le Fort I & Evro: A Pictorial Case Report.

¹Dr. (Brig.) Supriyo Roy, ²Dr. (Surg Cdr) Sheosevak Pandey,

³Dr. Ankush Mahajan, ⁴Dr. Arpita Sahu

¹Chief Oral and Maxillofacial Surgeon, Department of Oral and Maxillofacial Surgery, Clove Dental, Delhi NCR.

²Head of Implantology, Department of Oral and Maxillofacial surgery, Clove Dental, Delhi NCR.

³Consultant Oral and Maxillofacial Surgeon, Clove Dental, Delhi NCR.

⁴Consultant Orthodontist, Clove Dental, Delhi NCR.

Corresponding Author: Dr. (Brig.) Supriyo Roy

Abstract:

Orthognathic Surgery is used to treat mild to severe jaw deformity cases combining orthodontia and oral and maxillofacial surgery to give esthetics, function and stability. Here by we present a severely deformed case with 16 mm reverse overjet requiring bijaw surgery combining le fort I advancement and extra oral vertical ramus osteotomy of mandible for set-back.

Date of Submission: 25-01-2019

Date of acceptance: 07-02-2019

I. Introduction

Dentofacial deformities and malocclusion are corrected by orthognathic surgery that includes orthodontic and surgical operation of facial skeleton. Correcting malocclusion helps in achieving functional efficiency, structural balance and esthetics.¹ Patient with severe malocclusion has compromised physical health, masticatory dysfunction, upper airway resistance, sleep disorders, oral hygiene issues and may also have dysfunctional TMJ.² Majority of the malocclusion cases have skeletal class III, which are corrected using maxillary advancement, mandibular set back or a combination of both in certain cases.

II. Case Report

A 23-year-old male reported in clinic with a chief complaint of unaesthetic facial appearance due to forwardly placed lower jaw with chewing and speech difficulty. (Fig. 1 & 2) On further discussion, no relevant family history or any medical history was found. Extra-Orally Increased lower facial height, Long chin throat length, Reduced labiomental field, Less prominent chin button, Acute lip-chin-throat angle, Concave profile with prognathic mandible. Intra-orally Posterior cross bite, Reverse overjet of 16 mm, Dental midline discrepancy. (Fig. 3 & 4) Pre-treatment records include Lateral cephalogram, PA cephalogram and orthopantomogram. (Fig. 5 & 6) Treatment plan includes Pre-surgical Orthodontics, Lefort 1 osteotomy with bilateral extraoral vertical ramus osteotomy along with vertical reduction genioplasty. Mock Surgery was performed to evaluate the efficacy and fabricate a splint. (Fig. 7) Post-surgical orthodontics. Pre-surgical orthodontic treatment involved stepping up of upper and lower arches. In upper arch main aim was to align and decompensate the arch, the wire sequence was 014 NITI, 016 NITI. In the lower arch crowded teeth are there anteriorly, interproximal reduction was done for same. Wire sequence in the lower arch was 012 NITI, 016 NITI. Intra-arch levelling and aligning was done. Surgical procedure included Lefort 1 maxillary impaction was carried out initially which was repositioned 6 mm anteriorly. Bilateral extraoral vertical ramus osteotomy procedure done after Lefort 1 osteotomy in which mandible was set back by 10 mm. (Fig. 8) Vertical reduction genioplasty was performed as a primary procedure to reduce the chin in vertical direction. (Fig. 9) Rigid type fixation with miniplates used in both the jaws. Post-surgical orthodontic correction was done to achieve proper function and stability.



Fig. 1. Clinical Photographs Front- Pre orthodontia, Pre surgery, Post operative, Post Orthodontia

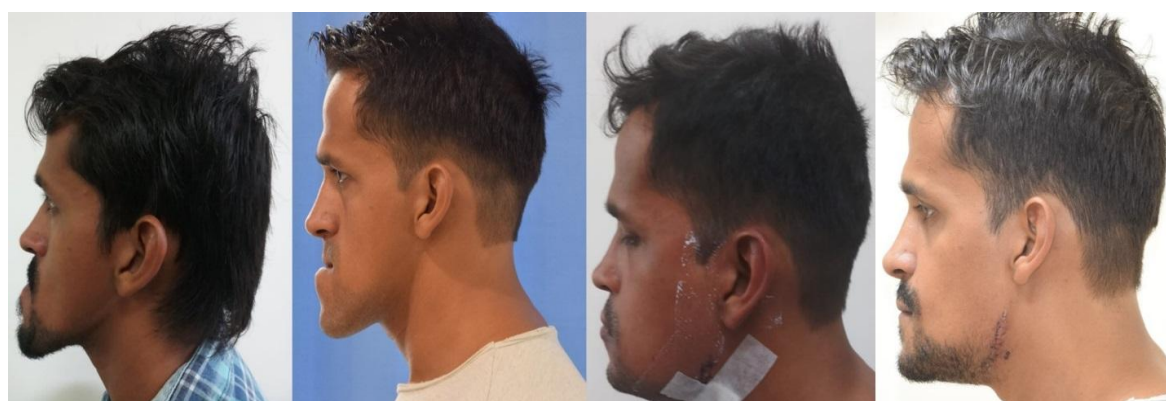

Fig. 2. Clinical Photographs Left- Pre orthodontia, Pre surgery, Post operative, Post Orthodontia

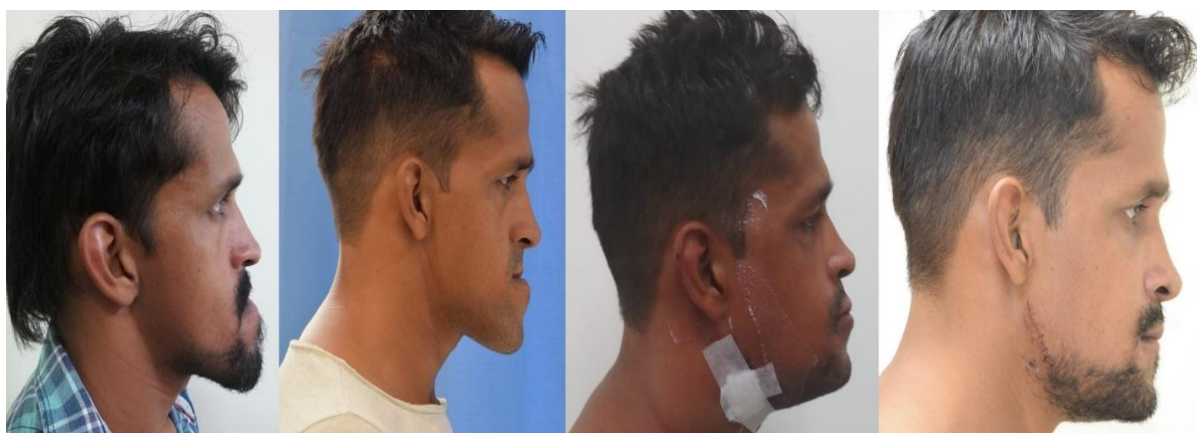

Fig. 3. Clinical Photographs right- Pre orthodontia, Pre surgery, Post operative, Post Orthodontia

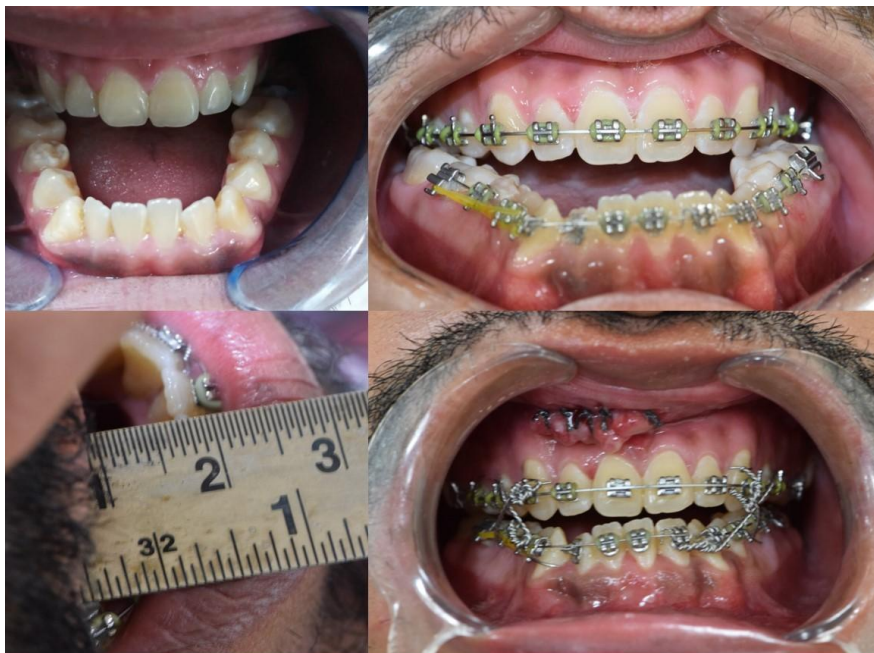

Fig. 4. Occlusal Photographs- Reverse Overjet, Pre & Post Surgery

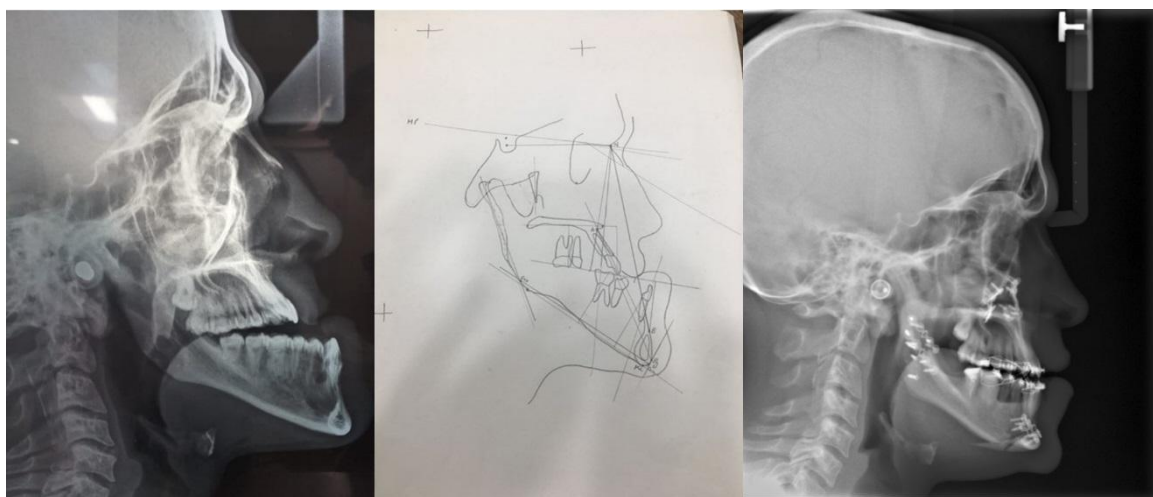


Fig. 5. Lateral Cephalograms - Pre operative, Tracing, Post operative

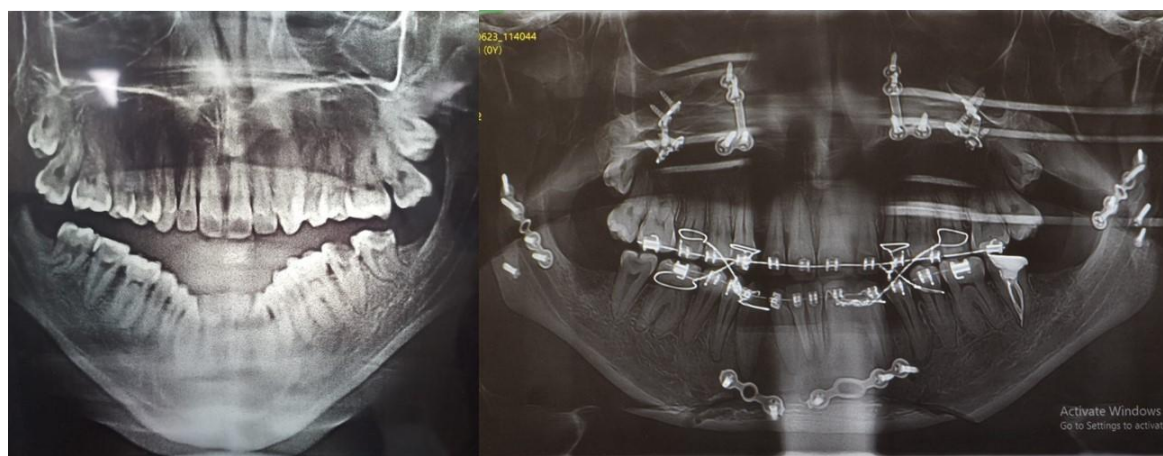


Fig. 6. Orthopantomograms - Pre & Post Surgery



Fig. 7. Mock Surgery- Pre & Post Mock Surgery

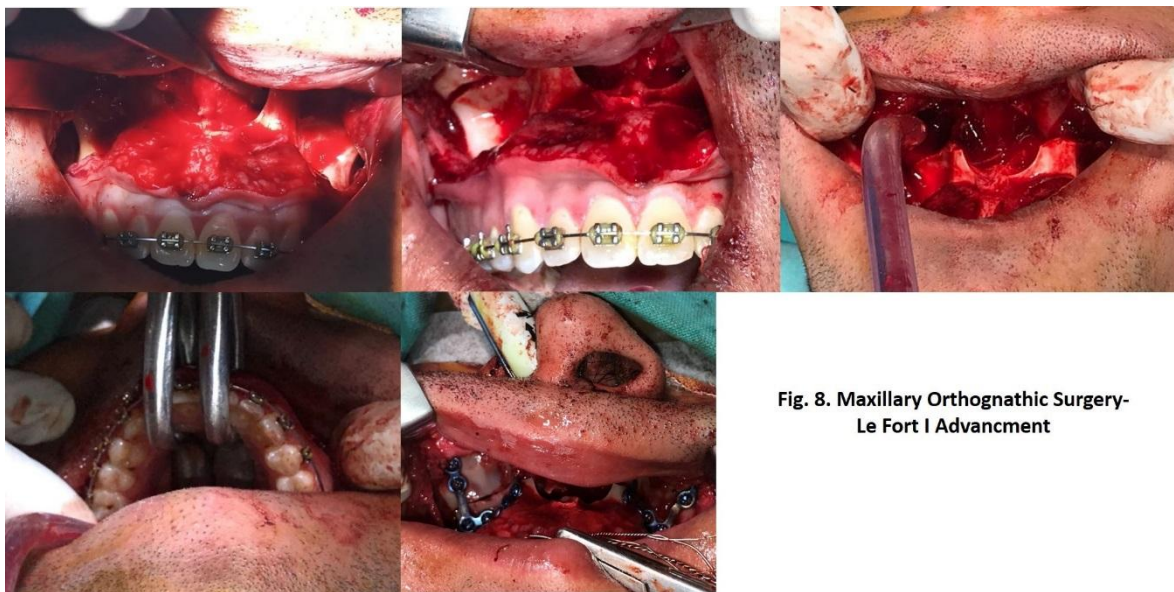


Fig. 8. Maxillary Orthognathic Surgery- Le Fort I Advancement

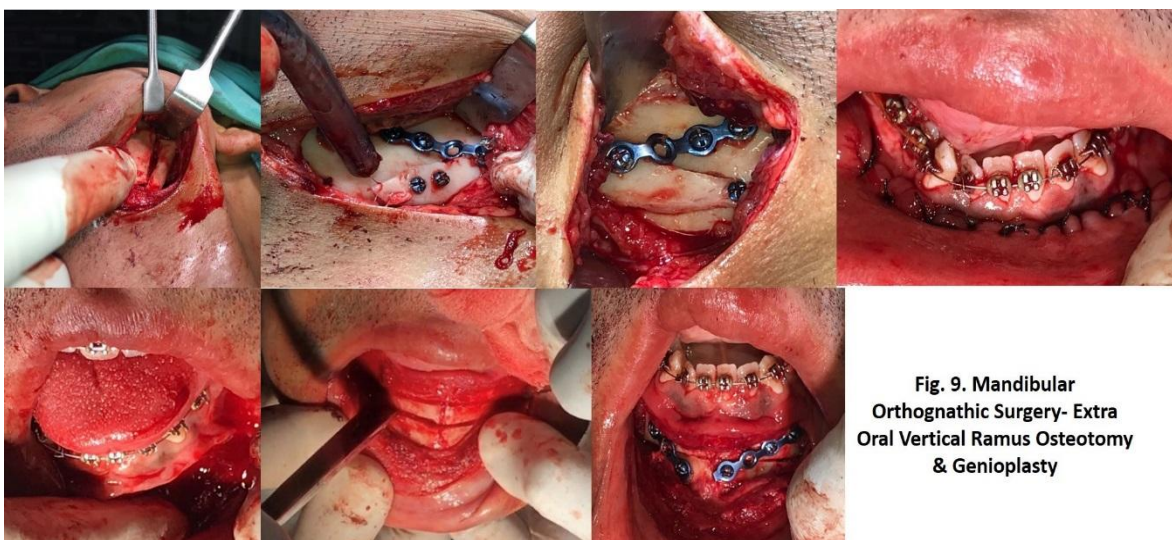


Fig. 9. Mandibular Orthognathic Surgery- Extra Oral Vertical Ramus Osteotomy & Genioplasty

III. Discussion

A multidisciplinary approach is required to establish common objectives and expectation of the proposed surgical and orthodontic therapy. Bimax surgery requires clinical experience and judgement, crucial part of treatment planning by thorough evaluation during presurgical phase of orthodontic treatment. Treatment objective is to achieve ideal intra arch and interarch co-ordination with each tooth in the oral cavity in its correct position.³ In order to outline an accurate and effective treatment plan, it is very important to understand the component of facial discrepancy. Cephalometric analysis helps in determining whether the discrepancy involves maxillary arch or mandibular arch or both, also if its associated with any dental compensation. In this case, correct facial height was obtained by superior reposition of maxilla along with maxillary advancement and mandibular extraoral vertical ramus osteotomy to rectify anteroposterior discrepancy.⁴ Advancement of maxilla helped in obtaining facial fullness and also limited the extent of mandibular setback within steady limits.⁵ Desired profile changes were also kept in mind in deciding relative amount of maxillary advancement and mandibular setback. The patient had a long and non-projecting chin, hence vertical reduction genioplasty was performed along with other procedures. Post orthognathic treatment, patient had decreased anterior and lower facial height along with soft tissue changes which includes decreased SNB angle, increased ANB angle and increased facial convexity.⁶ To maintain surgically obtained occlusion, good dental retention has a major role to play as it guarantees occlusal stability with positive outcome in the final hard tissue stability. Patient had no extensive issues with the extraoral scars and there were no postoperative complications.⁷

IV. Conclusion

Severely deformed jaws need exact diagnosis and treatment planning to achieve at a prompt results which will increase the quality of life of patient. Each and every case needs through planning for a better esthetics, function and stability.

References

- [1]. Jose Cherackal G, Thomas E, Prathap A. Combined orthodontic and surgical approach in the correction of a class III skeletal malocclusion with mandibular prognathism and vertical maxillary excess using bimaxillary osteotomy. *Case reports in dentistry*. 2013;2013.
- [2]. Vadgaonkar V, Gangurde P, Deshmukh V, Shah A. Orthodontic and surgical perspectives in management of a severe skeletal open bite. *BMJ case reports*. 2014 May 16;2014: bcr2013200069.
- [3]. Abeltins A, Jakobsone G, Urtane I, Bigestans A. The stability of bilateral sagittal ramus osteotomy and vertical ramus osteotomy after bimaxillary correction of class III malocclusion. *Journal of Cranio-Maxillofacial Surgery*. 2011 Dec 1;39(8):583-7.
- [4]. Ho CT, Huang CS, Lo LJ. Improvement of chin profile after mandibular setback and reduction genioplasty for correction of prognathism and long chin. *Aesthetic plastic surgery*. 2012 Oct 1;36(5):1198-206.
- [5]. Athanasios AE, Mavreas D, Toutountzakis N, Ritzau M. Skeletal stability after surgical correction of mandibular prognathism by vertical ramus osteotomy. *The European Journal of Orthodontics*. 1992 Apr 1;14(2):117-24.
- [6]. Luyk NH, Ward-Booth RP. The stability of Le Fort I advancement osteotomies using bone plates without bone grafts. *Journal of maxillofacial surgery*. 1985 Jan 1; 13:250-3.
- [7]. Acharya SS, Reddy PA, Arunraj MR, Prabhakar R, Karthikeyan MK, Hashir YM. Outcomes of Orthognathic Surgery-A Case Report. *International Journal of Contemporary Dentistry*. 2012 Feb 23;3(1).

Dr. (Brig.) Supriyo Roy. "Facial Deformity With 16 Mm Reverse Overjet Treated By Le Fort I & Evro: A Pictorial Case Report." *IOSR Journal of Dental and Medical Sciences (IOSR-JDMS)*, vol. 18, no. 2, 2019, pp 44-48.