

Pedicle Thoracumbilical Flap for Soft Tissue Coverage Defects Around Elbow Region

Prof Dr V Ramadevi¹, Dr K Sathsih Kumar²

Institute for Research & Rehabilitation of Hand & Department of Plastic Surgery

Government Stanley Medical College & Hospital, Chennai-1

Corresponding Author: Prof Dr V Ramadevi

Abstract: Pedicle flaps play a vital role for soft tissue reconstruction. One such pedicle flap is based on the vascular territory of the paraumbilical perforator vessels anastomosing with anterior division of lateral cutaneous branch of intercostal arteries known as Thoraco-umbilical pedicle flap. In this study, we present a series of thoracumbilical pedicle flap used to cover defects around the elbow region done in our Centre during the period of January 2014 to December 2015. A total of 12 patients with defects around the elbow were included in this study and the defects around the elbow were covered using thoraco umbilical pedicled flap. Intra operative technique and post-operative care with regular follow up was done. Out of 12 patients, 9 patients flap settled well without any complications and in 1 patient there was marginal necrosis of 3cms of the distal end of flap which was managed by debridement and flap advancement. In 2 patients, infection followed by dehiscence of flap occurred, which was managed by debridement, flap advancement and appropriate antibiotics. In all patients donor area was closed primarily.

Hence this flap can be used for most of the defects around the elbow region with advantage of primary closure of donor site, cosmetically acceptable donor site scar, easy operative technique, more length to breadth ratio and with minimal post-operative complication

Date of Submission: 13-02-2019

Date of acceptance: 28-02-2019

I. Introduction

Even in the era of Microvascular surgery, pedicle flaps play a vital role for soft tissue reconstruction in many areas with minimal flap complication. One such pedicle flap is based on the paraumbilical perforator vessels radiating towards the scapula which can be used to cover the soft tissue defects around the elbow region. Based on the vascular territory of the paraumbilical perforator vessels anastomosing with anterior division of lateral cutaneous branch of intercostal arteries, a fasciocutaneous pedicle flap is raised from midaxillary line to Para rectus area and used to cover defects around the elbow^(1,3,4,7,8).

Though the flap can be used to cover the flexor aspect of forearm and below elbow amputation stump, we present a series of thoracumbilical pedicle flap used to cover defects around the elbow region done in our centre during the period of January 2014 to December 2015. In our series, the flap dimension ranges from 20cm x 9cm to 24 cm x 12 cm. This series reports the usefulness of Thoraco-umbilical pedicle flap to cover defects around the elbow region.

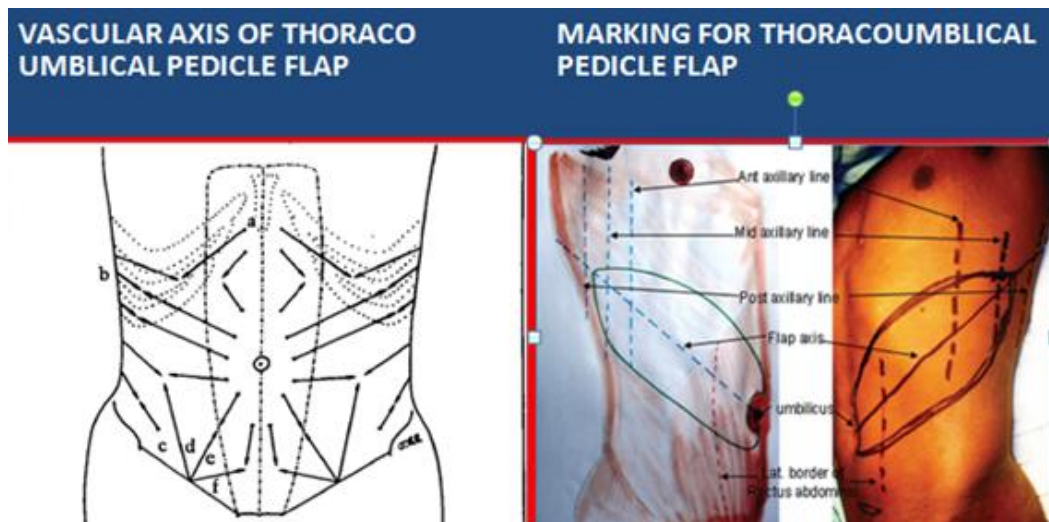
II. Materials and methods

Between January 2014 and Dec 2015, 12 patients presented with soft tissue defects around the Elbow region of which there were 11 males and 1 female with a mean age of 30years (range 20-40) who required flap cover for the defect. Out of 12 patients, 11 sustained injuries due to road traffic accident and 1 patient sustained injury due to industrial accident. The defect ranges from 10cm x 7cm to 15cm x 10cm. In patients with associated fracture, stabilization was done first and later soft tissue reconstruction was planned. Patients were given regional /general anesthesia. Debridement was done following which raw area was assessed and flap limits, axis were marked. The flap was elevated and inset given and arm restraint done. All patients were under clinical observation for a period of 3 weeks. Complications such as infection, marginal necrosis and flap dehiscence were noted. Division inset done at end of 3rd week and patient were discharged at the end of 4th week. Patients were then referred to physiotherapy for active and passive mobilization at the end of 6 weeks and later assessment done at end of 3rd months for joint stiffness and donor site scar.

VASCULAR ANATOMY OF THE FLAP:

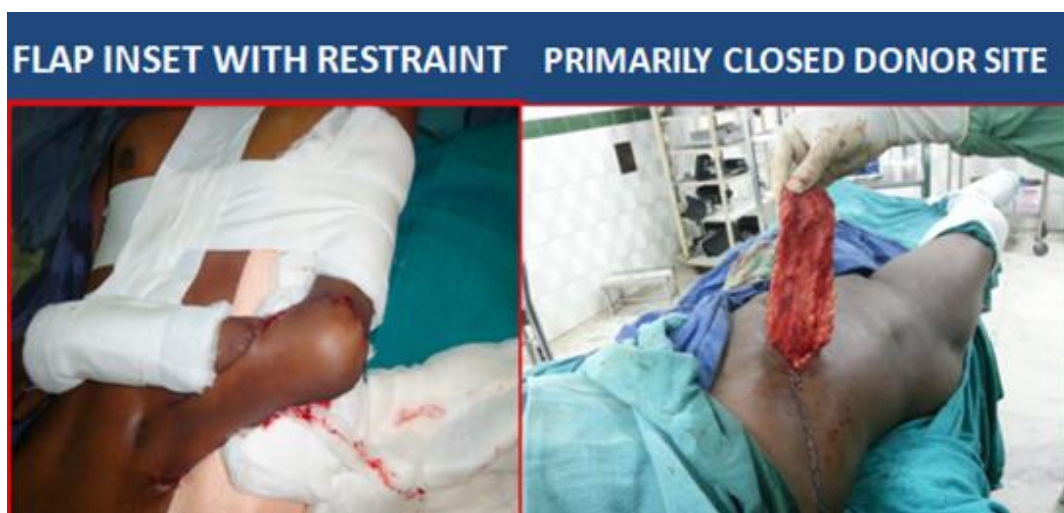The thoracumbilical flap is supplied by paraumbilical perforators from the deep inferior epigastric vessels that anastomose with anterior division of lateral cutaneous branch of posterior intercostal arteries. The

largest perforator is located at approximately 2 cm from the umbilicus and directed towards the inferior angle of the scapula. This large perforator anastomoses with the lateral cutaneous branch of posterior intercostal artery (1,3,4,5,9,10)



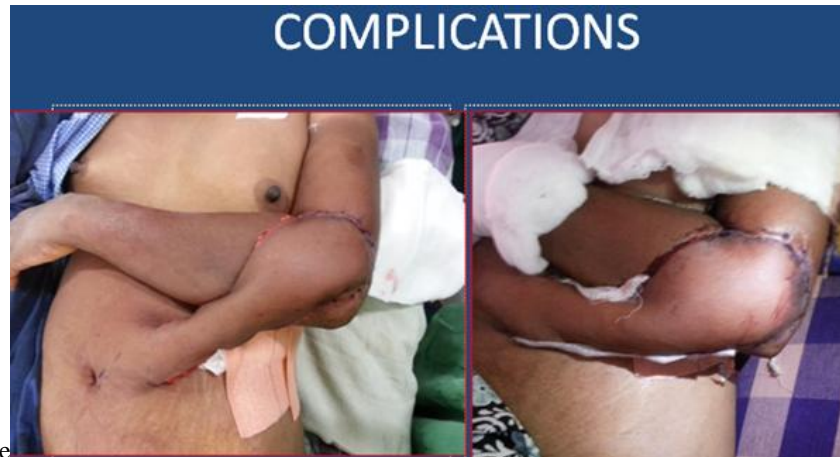OPERATIVE TECHNIQUE

Procedure was done under general / regional anesthesia in supine position .The axis of the flap is marked as a line extending superiorly and laterally from the umbilicus to the tip of scapula. The mid axillary and posterior axillary lines are marked. The mid axillary line is the safe margin for the distal end of the flap beyond which the flap can be elevated safely only after doing delay. A sand bag is placed below the lower ribs. Lint pattern of the defect is taken from the elbow. The lie of forearm should be planned such that it is placed in a comfortable position. Planning in reverse done .Flap markings done along the axis of the flap with base of the about 2cm on each side of the axis. The flap is raised superficial to the musculature from the lateral aspect to the medial aspect. The flap elevation should be stopped when the lateral border of rectus muscle is reached or at any point if the flap is found to be adequate in length. If pedicle length is not sufficient to reach the defect an additional 2 cm of pedicle length can be achieved safely after incising the rectus sheath in lateral border and elevating the flap below the sheath taking care not to injure the perforator. After elevating the flap, it is replaced in position to assess the viability .The surrounding areas are undermined and donor site is closed primarily. The arm is immobilized with help of adhesive plasters and a pillow beneath the elbow ⁽¹⁾. The flap division and inset are performed at the end of 3rd week. At the end 4th week patients were discharged and advised for follow up. Physiotherapy for active and passive mobilization of elbow was started at 6th week and at end of 3 months assessment of donor area and joint stiffness was done.



III. Results

Out of 12 patients, 9 patients flap settles well without any complications and in 1 patient there was marginal necrosis of 3cms of the distal end of flap which was managed by debridement and flap advancement. In 2 patients, infection followed by dehiscence of flap occurred, which was managed by debridement, flap advancement and appropriate antibiotics. The flap was raised from midaxillary line in 10 patients and in 2 patients flap raised from posterior axillary line. Joint stiffness occurred in all cases but resolved with post-operative physiotherapy. In all patients donor area was closed primarily. In 2 patients, donor site suture line infection was treated with antibiotics and secondary suturing.



IV. Discussion

The basis of the pedicled thoracumbilical perforator flap is the radiating vessels from the paraumbilical perforator that originates from the deep inferior epigastric artery. The flap designed with base in the umbilical region and its axis oriented along the interconnections with branches from intercostal vessels makes it to behave as an axial flap, thereby allowing more length to breadth ratio. This is advantageous as it can be used to cover defects on the flexor, extensor, lateral and medial aspect of elbow with arm and forearm in a comfortable position⁽¹⁾.

Taylor and Boyd described that a large flap could be designed in many directions along the axis that radiate from the umbilicus. The thoracumbilical flap is one of the best flaps planned along the axis of umbilicus and inferior angle of scapula running parallel to ribs. The operative technique of thoracumbilical pedicle flap is easy to learn and execute^(3,4,5).

The thoracumbilical perforator pedicle flap can be described as perforator plus flap as described by Sharma et al in their study⁽⁶⁾.

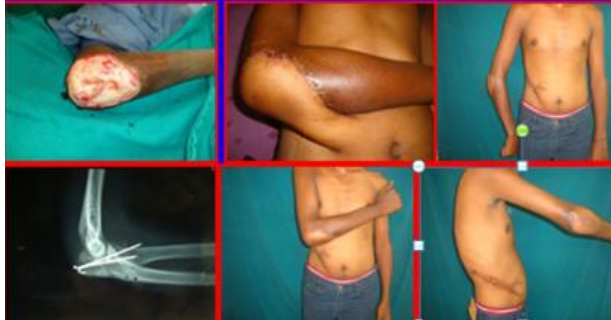The business end of the flap is usually thin and pliable and it is suitable for the coverage of elbow defects. The proximal part of the flap is bulky and tends to settle with time after final inset. Moreover, the upper limb with attached flap could be maintained at reasonably elevated position with a pillow which avoid venous problem. In our study, 75% of the flap settles without any complication and the flap coverage area range from 84cm² to 174cm². In rest of the 25%, we noted complications of infection and flap marginal necrosis managed by debridement and flap advancement and were able to provide stable wound coverage.

The donor site was closed primarily in all our patient. Tension was noted in the suture line at the time of closure but settles well. The main drawback of the flap is the unsightly scar in the abdomen area. However none of the patients had any complaints about scar except one who complained of itching 6 months later which was managed conservatively. All patients were satisfied with the scar as it could be well concealed in clothing. The narrow pedicle of the thoraco umbilical flap enables a significant comfort for the patient during the waiting period of 3 weeks of flap attachment.

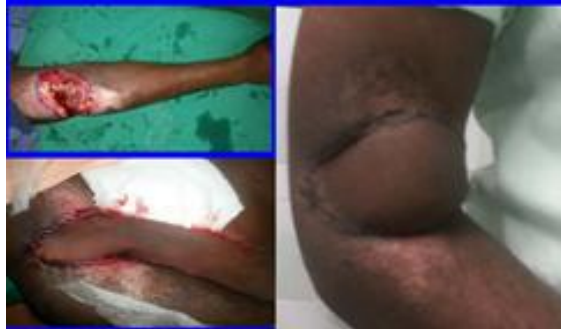V. Conclusion

The thoraco umbilical flap is a very useful flap to cover defects around the elbow region. The large donor area of this flap can be closed primarily thereby eliminating the need for split skin graft. There is no need to identify or isolate the pedicle during dissection of the flap. The learning curve for executing the flap is also easy. The flap remains in elevated position postoperatively thus having adequate venous drainage. The donor scar is cosmetically accepted by most patients as it is concealed by dresses. The flap can be a workhorse flap for defects around elbow region.

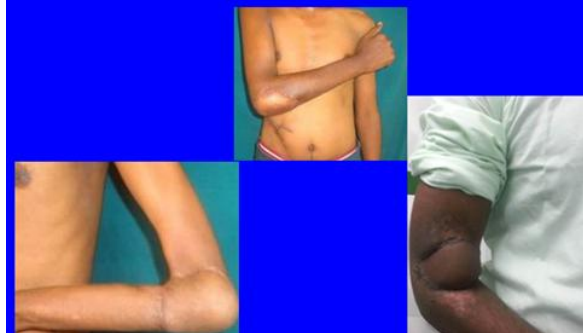CLINICAL CASE - 1



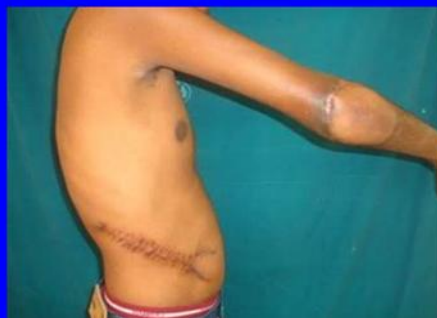CLINICAL CASE 2



LATE POST OPERATIVE PHOTOS OF THORACO UMBILICAL PEDICLED FLAP AROUND ELBOW REGION



LATE POST OPERATIVE PHOTOS OF THORACO UMBILICAL PEDICLED FLAP DONOR AREA - SCAR - CLOSED PRIMARILY



TABULATED DATA									
S no	Patient	Age	Sex	Mode	Flap dimension	Distal elevation	co morbid	Flap complication	Donor complication
1	PT 1	39	M	RTA	24x10	post axillary line		NIL	NIL
2	PT 2	40	M	RTA	18x8	mid axillary line		NIL	NIL
3	PT 3	41	F	INDUSTRIAL	20x 9	mid axillary line		marginal necrosis	infection
4	PT 4	21	M	RTA	22x10	mid axillary line		NIL	NIL
5	PT 5	26	M	RTA	20x7	mid axillary line		NIL	NIL
6	PT 6	31	M	RTA	20x12	mid axillary line		NIL	Hypertrophic scar
7	PT 7	33	M	RTA	20x12	mid axillary line		NIL	NIL
8	PT 8	29	M	RTA	20x10	mid axillary line		NIL	NIL
9	PT 9	40	M	RTA	24x8	post axillary line	diabetic	infection	infection
10	PT 10	30	M	RTA	22x10	mid axillary line		NIL	NIL
11	PT 11	20	M	RTA	20x12	mid axillary line		NIL	NIL
12	PT 12	36	M	RTA	20x 9	mid axillary line		infection	NIL

References

- [1]. Boyd JB, Mackinnon SE. An evaluation of pedicled thoraco umbilical flap in upper extremity reconstruction. *Ann Plast Surg.* 1989;22:236–42. [PubMed]
- [2]. Boyd JB, Taylor GI, Corlett R. The vascular territories of the superior epigastric and deep inferior epigastric system. *Plast Reconstr Surg.* 1984;73:1–14. [PubMed]
- [3]. Cormack GC, Lamberty BG. Cadaver studies of correlation between vessel size and anatomical territory of cutaneous supply. *Br J Plast Surg.* 1986;39:300–6. [PubMed]
- [4]. El-Mrakby HH, Milner RH. The suprafascial course of the direct paraumbilical perforators vessels. *Plast Reconstr Surg.* 2002;109:1766–8. [PubMed]
- [5]. McGregor IA, Jackson IT. The groin flap. *Br J Plast Surg.* 1972;25:3–16. [PubMed]
- [6]. Sharad Mishra and Ramesh Kumar Sharma The pedicled thoraco-umbilical flap: A versatile technique for upper limb coverage *Indian J Plast Surg.* 2009 Jul-Dec; 42(2): 169–175
- [7]. Sharma RK, Mehrotra S, Nanda V. The perforator plus flap: a simple nomenclature for locoregional perforator based flaps. *Plast Reconstr Surg.* 2005;116:1838–9. Further discussion and comment in *Plast Reconstr Surg* 2008;121:1864-5; author reply 1866-7. [PubMed]
- [8]. Taylor GI, Corlett R, Boyd JB. The extended deep inferior epigastric flap: A clinical technique. *Plast Reconstr Surg.* 1983;72:751–64. [PubMed]
- [9]. Taylor GI, Corlett RJ, Boyd JB. The versatile deep inferior epigastric flap. *Br J Plast Surg.* 1984;37:330–50. [PubMed]
- [10]. Zhang XQ, Wang SD, Fan QY, Mao BA, Zhou Y, Zhang MH. Thoracoumbilical flap: experience with 33 flaps. *J Reconstr Microsurg.* 2004;20:133–7. [PubMed]

Prof Dr V Ramadevi. “Pedicled Thoracoumbilical Flap for Soft Tissue Coverage Defects Around Elbow Region.” *IOSR Journal of Dental and Medical Sciences (IOSR-JDMS)*, vol. 18, no. 2, 2019, pp 23-27.