

Pheochromocytoma: A Rare Cause of Hypertension

Dr. Arun Kumar N.A¹, Dr. Jayanth.H²

¹Junior Resident , Department of General Surgery, A.J.Institute Of Medical Sciences And Research Centre , Mangalore , Karnataka , India.

²Senior Resident, Department Of General Surgery, A.J.Institute Of Medical Sciences and Research Centre, Mangalore.

Corresponding Author: Dr. Jayanth.H

Abstract

I hereby report a case of pheochromocytoma, rare cause for hypertension. Pheochromocytomas are rare tumours arising from adrenal medulla and it can present with abdominal pain and headache . A 35 year old lady with no co-morbidities presented with complaints of abdominal pain confined to right lumbar region with headache since 3 months ; low grade fever of 4 days . On examination Pulse = 116/ min , normal volume , Blood Pressure = 150/110 mm of Hg. Per abdomen no palpable mass .Radiologically diagnosed as right suprarenal mass ,which is confirmed by laboratory investigations and upon adrenalectomy operation and histopathology examination diagnosed as Pheochromocytoma.

Keywords : Pheochromocytoma , Suprarenal mass.

Date of Submission: 13-02-2019

Date of acceptance:28-02-2019

I. Introduction

Pheochromocytomas are rare tumours with prevalence rates ranging from 0.3% to 0.95% ¹ in autopsy series. In 1886 ,Mr.Felix Frankel described pheochromocytoma in a young woman with intermittent attacks of palpitations ,anxiety, vertigo, headache².This tumour stains brown when treated with chromium salt in autopsy hence the name. It is commonly reported among 40 - 50yr age group with no gender predilection.^{1,2} It affects 0.2 % of hypertensive individuals ; Classical triad of symptoms – Headache, Diaphoresis, and Palpitations².Extra adrenal tumours like ,functional paragangliomas sometimes may be associated. Previously called 10% tumour; has association with syndromes like MEN 2A , MEN 2B { Multiple Endocrine Neoplasia }, VHL { von Hippel Lindau } syndromes. Plasma Metanephrine testing has high sensitivity of 99 %.²

II. Case Report

A 35 year old lady , presented at surgical out-patient department with complaints of abdominal pain since 3 months, headache since 3 months ,palpitations since 1 month, and fever since 4 days . Pain is dull-aching type , located over the right lumbar region , non – radiating type , continuous , no aggravating or relieving factors ,and not associated with vomiting or abdominal distension. She is not a known diabetic , or hypertensive .; She complains of head ache since 3 months not relieved by medications and palpitations since 1 month not associated with dyspnoea, chest pain.She does not gives any history of tobacco use and alcohol consumption and there is no relevant family history .

Physical Examination : Blood Pressure was 150/110 mm of Hg , Pulse was 116/ min ,normal volume, regular rhythm , ; She was afebrile .

Per Abdomen :- Soft , Diffuse tenderness over the right lumbar region noted and on posterior part of right 12 th rib ., No hepato-splenomegaly , no palpable mass , no local rise of temperature , hernial orifices are normal .

Cardiovascular system : S1 , S2 , heard , No murmurs.

Ultrasound Abdomen and Pelvis: - A well defined lobulated heterogenous lesion predominantly hyperechoic noted in right adrenal measuring 6.2 X 4.1 cms. Few cystic areas noted within ; Colour Doppler shows minimal vascularity within , superiorly this is seen to indent inferior surface of liver.--Impression - Right adrenal incidentaloma / Pheochromocytoma.

Laboratory investigations : Showed Plasma Metanephrine levels was 552 pg /ml (Normal range ,< 57 pg/ml)

VMA (Vanillyl Mandelic Acid) in 24 hrs urine = 55.5mg /24hrs (normal range < 8.0)

VMA ratio to creatinine = 62.5mg/g Creatinine (normal range <8.0)

24 hour urinary total catecholamine = 232.6 µg/24 h (normal < 100 µg /24 hour)

Serum calcium was 8.8 g/dl . T3 , T4 , TSH was normal.

Other lab investigations are within normal limits

Contrast Enhanced Computed Tomography (CECT) abdomen and pelvis : A well defined inhomogeneously enhancing lesion measuring 7 X 5.4 X 4 cms in right supra -renal region with preserved fat planes with adjacent organs. The lesion is seen receiving blood supply from right renal artery. Features of Right Adrenal Pheochromocytoma.

Impression :

Right sided Pheochromocytoma with uncontrolled hypertension .

In view of diagnosis patient was started on alpha blocker , Phenoxybenzamine 20 mg daily for one month and planned for surgery .³

Surgery : Lateral Approach is used under General Anesthesia with epidural analgesia , right subcostal incision made ,peritoneum is opened , Hepatic flexure of the colon is mobilised inferiorly , triangular ligament is incised to retract liver medially and superiorly , Kocherization of duodenum is done, Retroperitoneal fat and IVC is exposed , 12 th Rib is excised at its base , Gerota's fascia is incised and gland with the tumour is freed from the surrounding fibro-fatty tissue and kidney inferiorly; Short right adrenal vein is dissected ligated and divided ; Intraoperatively gross variation in blood pressure was noted and managed accordingly.; Tumour is removed resulting space filled with perinephric fat and closed in layers , chest x ray is done post operatively to rule out pneumothorax.¹

Post operative period was uneventful .

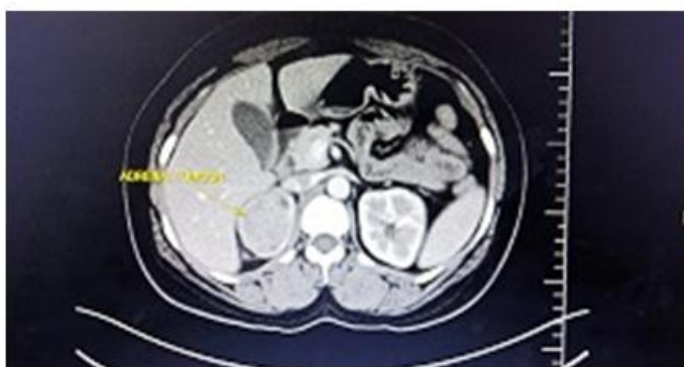

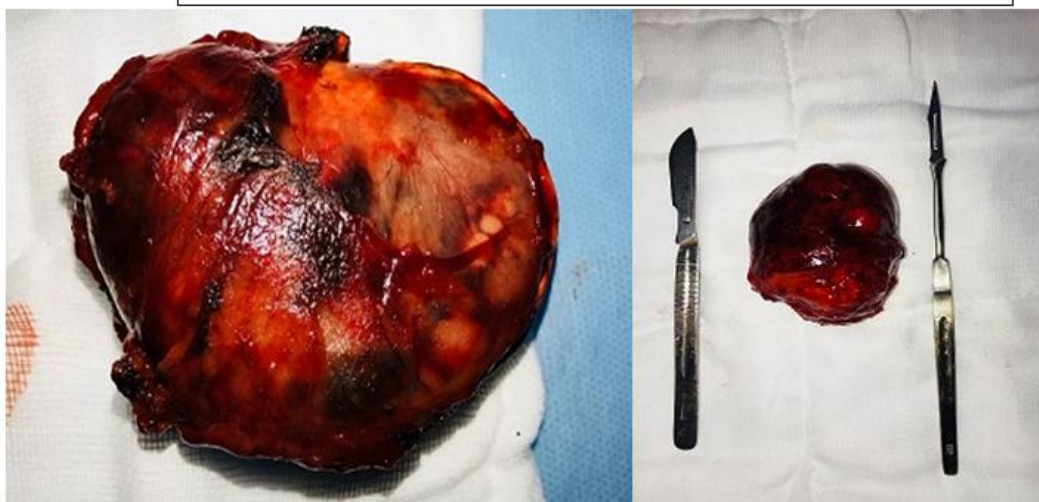
Fig.1 .-Showing sagittal section of right supra renal mass - pheochromocytoma

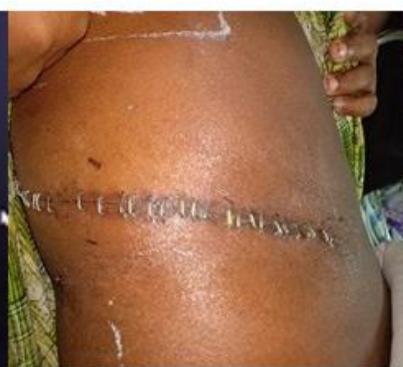

Fig.2.Right subcostal incision scar

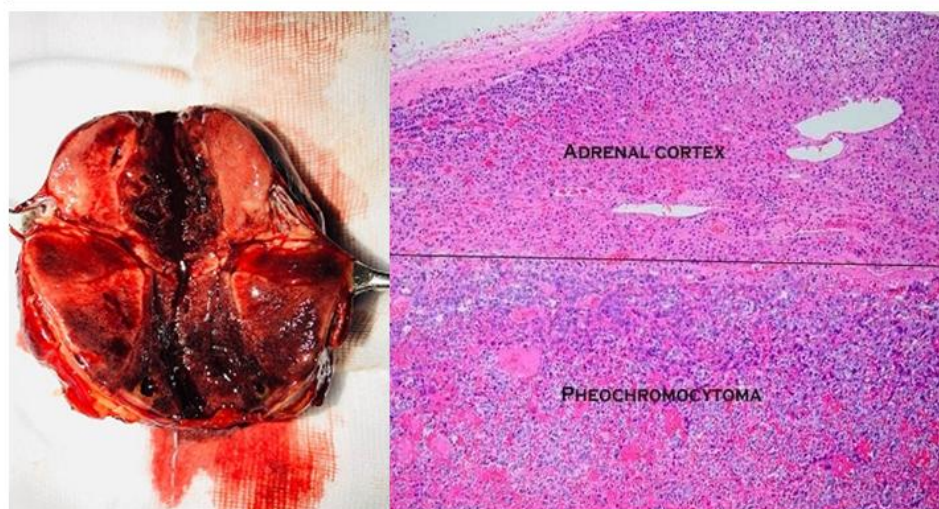
Histopathology :

Fig.3, 4. Resected specimen of right adrenal tumour



Gross : A tumour measuring 7.0 cm X 6.5cm X 4.5cm weighing 75 g , intact fibrous capsule noted , Cut surface shows lobulated with pink tan and fleshy areas ; hemorrhagic and cystic areas noted.

Fig.5,6.Gross and microscopic picture of tumour



Microscopy: Showed tumour tissue with large polygonal cells arranged in nests separated by vascular septae , alveolar pattern , and foci of solid sheets . Tumour cells are large,polygonal with amphophilic cytoplasm having round to ovoid coarsely clumped chromatin and a single prominent nucleoli with occasional pseudoinclusions . Foci of vascular invasion seen within tumour – Features are consistent with Pheochromocytoma.

III. Discussion

Clinical presentation : Headache , palpitations and diaphoresis with or without abdominal pain of short duration must suspect the cause of hypertension could be pheochromocytoma. Also the previous rule of 10 which is being challenged due to newer discovery of genetic underpinning ² . Incidence of malignant pheochromocytoma which is associated with decreased survival is increasing 12- 29 % ¹. Persistent hypertension unresponsive to medical management should arouse the suspicion of pheochromocytoma as in this case .

Blood investigations: Plasma metanephrine values were estimated to be 552pg/ml (normal < 57 pg/ml).This has high sensitivity but false positives can occur if patient is on sympathomimetics, phenoxybenzamine , acetaminophen , psychotropic drugs ¹

Other tests like ;24 hour urinary catecholamine metabolites estimation, clonidine suppression test, MRI which is highly sensitive , CECT yields better anatomic definition for operative planning – favours the diagnosis, I¹³¹ or I¹²³ MIBG (Metaiodobenzyl guanidine) scan , Single photon emission computed tomography (SPECT) will also favours the diagnosis in 90 % of tumours .²

In our case , as the patient had short duration of headache , right lumbar pain with hypertension ,palpitations ,and ultrasonography & CECT showed evidences of right suprarenal mass ; Additionally the plasma metanephrines and 24 hour urinary catecholamines were elevated and we considered the diagnosis as right sided pheochromocytoma.

As the relevant investigations like ECG ,2D – ECHO ,TFT ,FBS were normal and no medication history preoperatively , the diagnosis for symptoms of palpitations and headache rules out coronary artery disease (CAD), cerebrovascular accident (CVA), and cardiac failure ,hypoglycaemia ,hyperthyroidism , panic disorders, drug related adverse effects .

Preoperatively patient was started on alpha adrenergic antagonist like phenoxybenzamine 20 mg daily with additional 10mg increment upto 160mg till hypotension occurs and then fixed the dose .³

Surgical open adrenalectomy was performed followed by careful monitoring of blood pressure and heart rate post operatively . As the tumour size is more than 5 cm and; due to lack of expertise of laparoscopy we performed open procedure.

Complications : If left undiagnosed the patient can develop cardiovascular complications like-myocardial infarction , cerebrovascular accident,TIA (Transient ischemic attacks), sudden death. Post operative complications like profound hypotension → cardiovascular collapse, ² pneumothorax ,pleural effusion , and basal atelectasis can be seen.

IV. Conclusion

Pheochromocytoma is a rare tumour of adrenal medulla may present with newly diagnosed hypertension with or without complications. Laboratory investigations of catecholamine metabolite estimation forms a key role in diagnosing a case of adrenal incidentaloma. These tumours require prompt use of alpha blockers and well planned surgical resection followed by lifelong follow-ups . The peri-operative mortality rate is reduced from 20-45% to less than 3% with the use of alpha adrenergic antagonists like phenoxybenzamine.³

References

- [1]. Schwartz's Principles Of Surgery , 10th Edition ,Specific considerations ; Adrenal glands : 1586-1588.
- [2]. Sabiston's Textbook Of Surgery,1st SAE Edition ,Endocrine section: adrenal glands- pheochromocytoma; 980-985.
- [3]. Bailey & Love 's Short Practice Of Surgery, 27th Edition . Part 8: Surgery of the Adrenal glands :846-847.
- [4]. Bai.S ,Yao.Z Zhu.X,et al International Journal of Surgery ,2018. Dec ,Risk factors for post operative severe morbidity after pheochromocytoma surgery : 188-193
- [5]. Bettacchioli.E, Leven .C, Padelli .M. Annals of Surgery ,Paris 2018: Oct : Biological diagnosis of pheochromocytoma ; urinary metanephrine estimation :76(5); 537-544
- [6]. Aksakal .N., Sahbaz NA, Erbil .Y et al , American Journal of Surgery 2018 June: Predictive factors of operative hemodynamic instability for pheochromocytoma 84(6): 920-923
- [7]. Afaneh A, Yang .M, et al ,Surgical Management of Giant Pheochromocytoma; May 2018 32(3): 703-706.

Dr. Arun Kumar N.A" Pheochromocytoma : A Rare Cause of Hypertension" IOSR Journal of Dental and Medical Sciences (IOSR-JDMS), vol. 18, no. 2, 2019, pp 20-23.