

Outcome analysis of Management of untreated Developmental Dysplasia of Hip by Klisic Procedure

Dr.K.P. Manimaran.,¹Dr.M.Sathish.,²Dr.R.H. Govardhan³

¹Associate Professor, Institute of Orthopaedics and Traumatology,
Madras Medical College & Rajiv Gandhi Government General Hospital, Chennai – 03.

²Junior Resident in MS Ortho, Institute of Orthopaedics and Traumatology,
Madras Medical College & Rajiv Gandhi Government General Hospital, Chennai – 03.

³Emeritus Professor, Dr.MGR Medical University, Guindy, Chennai.

Corresponding Author:Dr.M.Sathish

Abstract:

Introduction:Developmental dysplasia of hip (DDH) is a spectrum of disorders of the developing hip that present in different forms at different ages. As the child becomes older without early treatment more secondary deformities develop which can be grouped on 3 major pathological entities like acetabular dysplasia, femoral head subluxation and soft tissue contractures. The aim of our study is to analyse the effectiveness and functional outcome in neglected developmental dysplasia of hip by one stage Klisic procedure.

Methodology: This is a prospective study conducted in Institute of Child Health and Government General Hospital, Egmore from 2013-2018. Patients presenting with DDH more than 3 years of age were included in the study. All the patients were evaluated radiologically and their acetabular index is calculated and proceeded with one stage Klisic procedure which consist of Open reduction of displaced hip joint with Primary femoral shortening, Varization and Derotation with Capsulorrhaphy and Pelvic osteotomy namely Salter or Dega for acetabular dysplasia. Post-operative acetabular index on follow up and functional outcome is evaluated by Modified Mc Kay's classification.

Results:We included 12 hips from 10 patients in the study of which 8 were female and 2 male children with age range between 3-15 yrs (Mean 7 yrs). There were 7 left sided hips and 5 right sided hips and 2 bilateral hips. 4 patients had unsuccessful surgical attempts earlier. Mean follow up is 3.7 yrs with range between 2.5-5 yrs. Mean preop acetabular index was 42°. On final follow up mean acetabular index was 33°. According to Modified McKay's classification 25% (3) had Excellent results while 16.67%(2) had Good and 41.66% (5) had Satisfactory and 16.67% (2) had Poor results. We had complications like secondary subluxation in one patient and superficial infection in one and lateral popliteal nerve palsy in one patient due to valgus deformity correction in knee.

Conclusion: The one stage correction procedure can be considered as a safe and effective option in neglected developmental dysplasia of hip in patients more than three years of age. If the procedure is done in relatively younger children the functional outcome is better compared to older children. This procedure has the advantage of decreasing the need for subsequent surgeries in multistage procedure and eliminating the need for prolonged post-operative immobilization.

Key words – DDH, Klisic Procedure, Modified McKay classification, Acetabular Index

Date of Submission: 13-02-2019

Date of acceptance:28-02-2019

I. Introduction

There is no single cause for developmental dysplasia of hip but number of predisposing factors have been identified. These factors include ligamentous laxity, prenatal positioning, post-natal positioning, racial predilection. The etiology of developmental dysplasia of hip (DDH) is of multifactorial and it is influenced by hormonal and genetic elements. Developmental dysplasia of hip is a gradually progressive disorder associated with distinct anatomical changes many of which are initially reversible. It is a malformation of anatomic structure that have developed normally during the embryologic period. As the child grows secondary changes in the pelvis occurs which are not reversible.

At birth the affected hip will spontaneously slide into and out of the acetabulum. For this to occur, the posterior superior rim of the acetabulum has to have lost its sharp margin and become flattered and thickened on the area over which the femoral head slide. As the head rides in and out of the socket, a ridge of thickened articular cartilage arises along the posterior superior acetabular wall.

If the hip remains dislocated out of the socket permanently, many secondary anatomy changes will take place gradually. As the child becomes older more secondary deformities develop which can be grouped on 3 major pathological entities like acetabular dysplasia, femoral head subluxation and soft tissue contractures. The aim of our study is to analyse the effectiveness and functional outcome in neglected developmental dysplasia of hip by one stage Klisic procedure.

II. Materials & Methods:

This is a prospective study conducted in Institute of Child Health and Government General Hospital, Egmore from 2013-2018.

Inclusion criteria

1. The children, more than 3 yrs old with developmental dysplasia of hip are included in this study.
2. The children who underwent previous surgeries for developmental dysplasia of hip are also included in this study.
3. The children with associated deformities like congenital talipes equino varus and secondary valgus deformity of knee due to the stiff hip are also included in this study.

Exclusion criteria

1. The children with developmental dysplasia of hip, less than 3 yrs old were excluded from this study.

Treatment methodology

All the patients were treated with one stage correction procedure which was described by Predrag Klisic. The klisic's procedure consists of

- Open reduction
- Capsulorrhaphy
- Femoral shortening, derotation and varization
- Pelvic osteotomy (Salter or Dega osteotomy)

In our study none of the patients were put in skeletal traction in the fear of avascular necrosis. The amount of the shortening femur is calculated preoperatively from the upper pole of femoral head to the superior part of the roof of acetabulum. In our study we have done 6 salter osteotomies and 6 Dega osteotomies.

In one case secondary valgus deformity of the knee due to the dislocated hip was corrected by ilizarov fixator prior to the klisic procedure. In one case we observed avascular necrosis of dislocated femoral head pre operatively.

Post Op protocol

- Drain removal on 2nd day
- Antibiotics up to 3rd day
- Suture removal on 10 to 12th day
- Hip Spica immobilization for 6 to 8 weeks
- After 8th week mobilization in bed
- Weight bearing and Walking as tolerated.

Surgical procedure

This Klisic procedure is done under general anaesthesia with caudal block. Patient is put in supine position with a sand bag under the affected hip.

Open reduction

We followed the anterior or iliofemoral approach. The bikini incision is made from the anterior superior iliac spine to the lateral aspects of the femur. The superficial plane is between Sartorius and tensor fascia lata. The deep plane is between rectus femoris and gluteus medius. The reflected part of the rectus femoris is erased from capsule. The capsule is incised and the pseudo acetabulum is identified. The ligamentum teres is traced and the true acetabulum identified. The iliopsoas tendon identified and cut to facilitate reduction of the hip joint.

Femoral shortening

Through the lateral approach the femur is exposed by erasing the vastuslateralis from the lateral intermuscular septum. Femoral osteotomy is performed with the help of giglee saw to facilitate reduction of the femoral head to the hip joint. The osteotomy is performed at the level of the lesser trochanter. The length of the is calculated preoperatively from the upper pole of femoral head to the superior part of the roof of acetabulum. The femur is fixed with 3.5 mm cortical screws in Asian dynamic compression plate.

During the fixation of the femur the valgus position of the upper femur is corrected into varus position. After the open reduction the patella will face medially and the limb will be in internal rotation. The internal rotation also corrected during the fixation of the osteotomised femur by derotation.

Capsulorrhaphy

The lax redundant capsule is excised and tightened by capsulorrhaphy by double breasting method.

Pelvic osteotomy

Pelvic osteotomy is done to reorient and reshape the acetabulum for the better containment of the femoral head in the dysplastic acetabulum.

Salter innominate osteotomy

Salter innominate osteotomy is made just above the acetabulum running transversely from the anterior superior iliac spine to the greater sciatic notch subperiosteally. The lower fragment is displaced downwards, outwards and forwards. While displacing the lower fragment the pubic symphysis is acting as a hinge. A wedge shaped graft which is harvested from the anterior part of the iliac crest is inserted into the osteotomy site to maintain the position and fixed with two K-wires.

Dega osteotomy

Dega osteotomy is also a trans iliac osteotomy which is an alternative to salter innominate osteotomy. This incomplete trans iliac osteotomy involves osteotomy of the anterior and middle portion of the inner cortex of the ilium. The posterior cortex is intact and acts as a hinge. At the osteotomy site the lower fragment is displaced and resected femur from the femoral shortening is used as a graft.

The following prerequisites are necessary for the success of pelvic osteotomy.

1. The femoral head must be positioned opposite to the level of the acetabulum; this requires the primary femoral shortening.
2. Contracture of the iliopsoas must be relaxed to obtain open reduction of hip joint.
3. The femoral head should be reduced into the depth of the true acetabulum completely and concentrically. This needs excision of the fibro cartilage from the acetabulum.

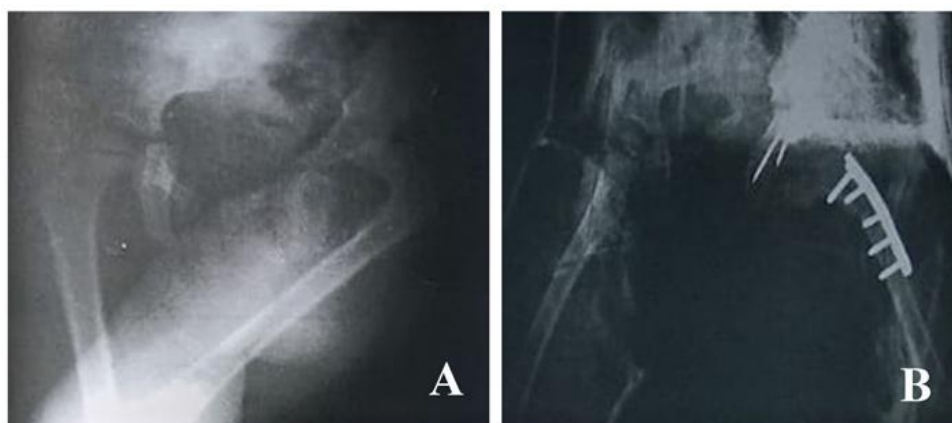
All the patients were evaluated radiologically and clinically. The pre and post-operative acetabular index is measured.

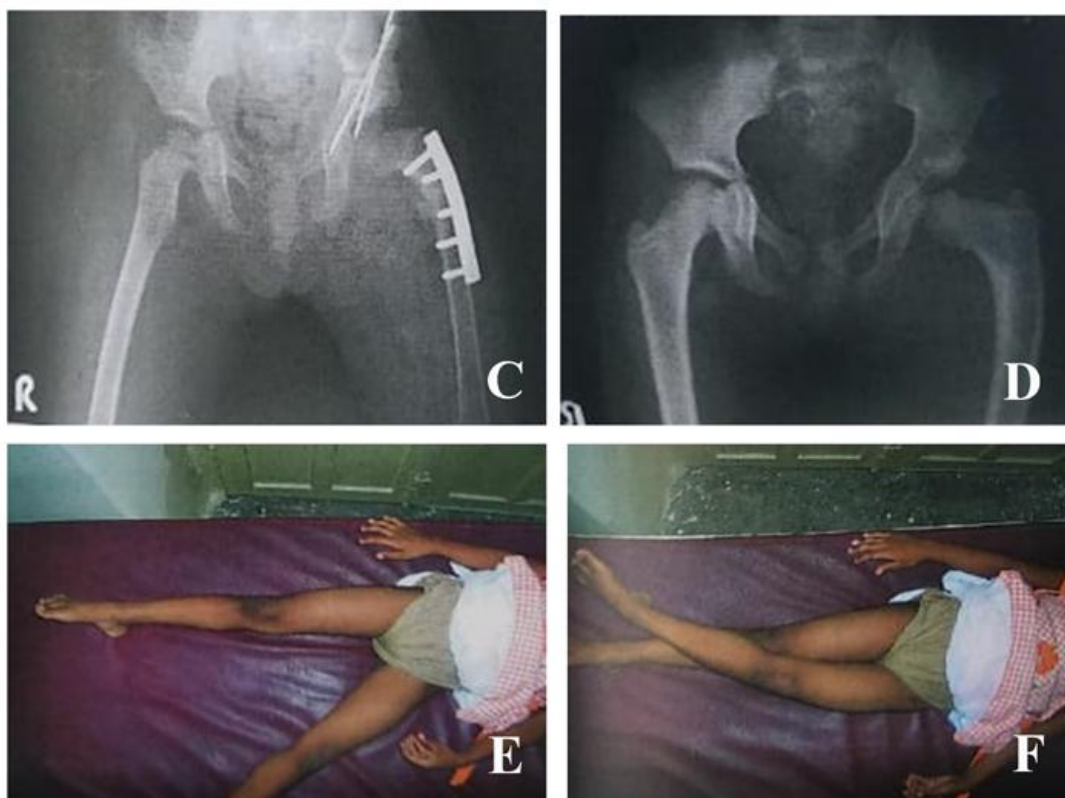III. Results

There were 8 female and 2 male children with the female preponderance of developmental dysplasia of hip. All the patients were more than 3 yrs old. The lowest age is 3 yrs and the highest age is 15 yrs. The mean average of the age is 7 yrs. There were 7 left sided hips of 5 right sided hips which include 2 bilateral hips.

Four patients had previous unsuccessful surgical attempts, one patient had bilateral congenital talipes equinovarus while another patient had secondary valgus deformity of the knee due to stiff hip. The period of study is from 2013-2018. The longest follow-up is 5 yrs while shortest follow-up is 2 yrs and 6 months. All the patients are evaluated clinically and radiologically.

Figure 1 A-E showing an illustrative case with A- Preop X ray B-immediate Post op X ray C-Pre implant exit status X ray D-X ray on final follow-up E&F showing abduction and adduction range in hip on final follow-up.





Clinical evaluation:

Post operatively after the period of immobilization (6-8 weeks) the patients were evaluated with the following criteria.

- Pain in the hip joint while at rest, standing and walking.
- Stability of the hip.
- Range of movement of the hip joint.
- Trendelenburg sign.

Table:1 Modified MC Kay’s classification

Excellent	Painless stable hip. No limp More than 15° internal rotation Negative Trendelenburg sign
Good	Painless, stable hip, Slight limp Slight decrease on hip rotation Negative Trendelenburg sign
Satisfactory	Minimum pain Moderate stiffness Positive Trendelenburg sign

Table:2 Results of clinical evaluation by modified McKay’s classification

Clinical Result	Number	Percentage
Excellent	3	25%
Good	2	16.67%
Satisfactory	5	41.66%
Poor	2	16.67%

Radiological evaluation:

Post operatively all the patients were evaluated radiologically with severin’s classification. The Severin classification includes the following criteria

- Deformity of the femoral head
- Deformity of the femoral neck
- Deformity or dysplasia of acetabulum

- Articulation of the femoral head
- Centre edge angle
- Age

Mean preop acetabular index was 42°. On final follow up mean acetabular index was 33°.

Complication:

One secondary subluxation of femoral head posterior after salter innominate osteotomy as the posterior wall of the acetabulum is deficient. Supracondylar fracture of femur occurred during treated by antibiotics. The lateral popliteal nerve palsy is due to the complication of correction of the secondary valgus deformity of the knee due to a dislocated hip. This accurse while correcting the deformity with illizarov fixator. This managed by lateral popliteal nerve release.

Table 3 Master chart of the study showing the preop and post op functional and radiological results

S. No	Name	Age/Sex	Diagnosi s	Previous Surgery	Pre-Operative		Surgery		Post-operative		Function al Result	Radiolog ical	Follow un	
					Neck shaft angle	Acetabula r Index	Procedure	Pelvic osteotomy	Neck shaft angle	Acetabula r Index			Grade	Year
1	Sushimitha	7/F	DDH Rt	Operated	140°	40°	Klisic	Salter	130°	35°	Poor	II	5	0
2	Kathirmani	12/M	DDH Lt	-	143°	62°	Klisic	Dega	128°	40°	Satisfactory	III	5	0
3	Pushpavalli	8/F	DDH Lt	-	141°	43°	Klisic	Salter	125°	33°	Excellent	II	5	0
4	Arul Jothi	3/F	DDH Lt	Operated	110°	34°	Klisic	Salter	96°	28°	Excellent	I	4	7
5	Ammu	15/F	DDH Rt	-	128°	42°	Klisic	Salter	121°	31°	Poor	II	3	6
6	Deepa	5/F	DDH Rt	Operated	125°	35°	Klisic	Dega	120°	31°	Good	IV	3	3
			DDH Lt	-	145°	45°	Klisic	Salter	120°	33°	Satisfactory	II	3	6
7	Krishnakumari	7/F	DDH Lt	-	141°	38°	Klisic	Dega	125°	32°	Good	II	3	8
8	Kala	4/F	DDH Rt	Operated	110°	35°	Klisic	Dega	91°	30°	Satisfactory	IV	3	9
9	Arunkumar	4/M	DDH Lt	-	135°	45°	Klisic	Salter	121°	35°	Excellent	II	3	10
10	Akshyalakshmi	9/F	DDH Rt	-	140°	43°	Klisic	Dega	105°	38°	Satisfactory	II	2	9
			DDH Lt	-	145°	45°	Klisic	Dega	125°	30°	Satisfactory	II	2	7

IV. Discussion:

In our study all the patients with neglected developmental dysplasia of hip were having secondary changes in the soft tissues, bony pelvis and in the upper femur.

Many treatment options have been proposed for developmental dysplasia of hip. While in our study all the patients were treated with a one stage correction by Klisic procedure which includes Open reduction with capsulorrhaphy, femoral shortening varization, derotation and pelvic osteotomy like salter or dega osteotomy.

In our study we did not use any pre-operative traction. In older children the more rigid contractures of the soft tissues may prevent reduction or may cause it to be unstable.^{8,11} This tightness also results in major pressure on the capital femoral ossific nucleus if reduction is obtained leads to avascular necrosis of the femoral head.⁵

Femoral shortening allows all of the muscles that cross the osteotomy site to function as if they were lengthened. When it is combined with open reduction, it avoids the prolonged hospitalization, risk of skeletal traction and avascular necrosis.

There have been numerous reports discussing the merits of the more aggressive surgical approach which includes open reduction of the dislocated hip, femoral procedure for relatively long femur and valgus mal-alignment of the neck and pelvic osteotomy for acetabular dysplasia. In all the reports the results were

encouraging. In our study we have shown 83.33% excellent to satisfactory results clinically and 83.33% excellent to satisfactory to results radiologically which is comparable with other studies.

Galpin et al have reported 75-85% satisfactory results radiologically and clinically.⁵ Rachid K haider have reported 97.8% excellent to good results clinically.¹⁸ In this study he is able to show better results because the patients were relatively young age. Salter and Dubos have reported excellent to good results 93.6% radiologically in patients less than 4 yrs. And 56.7% between the age of 4-10 yr. R.R. Rajendra et al have shown 76.9% clinically excellent to good results 69.2% radiologically excellent to good results.¹⁹

We did not use any pre-operative traction pre operatively. The open reduction femoral shortening derotation and varization effectively lengthened the soft tissue across the hip joint and decrease the pressure on the femoral head during and after reduction. This is one of the important causes for the prevention of avascular necrosis.^{5,8,11}

In our study early cases were done with salter innominate osteotomy we there is a chance of secondary subluxation posteriorly after salter innominate osteotomy. The dislocation after salter innominate osteotomy is discussed by fixen et al.⁴ He suggest that the secondary subluxation his due to poorly executed osteotomy, a lax capsulorrhaphy or an excessive femoral anteversion. During the combined procedure the pelvic osteotomy by salter method will result in posteriorly deficient acetabulum and the derotation preformed for centering the femoral head increases the rate secondary subluxation of the hip joint.

In our study we have shown 8.33% secondary subluxation rate that is comparable with 5 to 14.3% subluxation rate in Rachid K Haider study. In later cases we followed dega osteotomy for the correction of acetabular dysplasia and good results were obtained without any secondary subluxation. The functional outcome his better in younger children and those who were not undergone previous surgery. The functional outcome is relatively poor in older children and who had previous surgeries.

V. Conclusion:

The one stage correction procedure can be considered as a safe and effective option in neglected developmental dysplasia of hip in patients who were more than three years old. If the procedure is done in relatively younger children the functional outcome is better compared to older children. This procedure has the advantage of decreasing the need for subsequent surgeries in multistage procedure and eliminating the need for prolonged post-operative immobilization. In posterior subluxation of hip with posterior defect Dega osteotomy can be performed.

This study is the authentic work of the authors. No financial benefits were received from any commercial party for this study.

Funding:

The author(s) received no financial support for the research, authorship, and/or publication of this article

References

- [1]. Artz. T Levine D.Lim W et al : Neonatal diagnosis, treatment and related factors of congenital dislocation of hip. Clinical Orthop 1975:110:112.
- [2]. Coleman .S congenital dysplasia of the hip on the Navaja infant. Clin Orthop 1968:56:P179.
- [3]. Deputyen G. Original or congenital displacement of the heads of the thigh bones clinical orthop 1964:33:3
- [4]. Fixen JA : anterior and posterior subluxation of hip following innominate osteotomy. J.Bone Joint Surg 1987:69B:361-364.
- [5]. Galpin RD, Road JW, Wenger DR.: One stage treatment of congenital dislocation of the hip : the risk of avascular necrosis with three different approaches. Pediatr orthop 1986:6:127-132.
- [6]. Ideleberger.K : The genetic pathology of so called CDH. Munich, Urban and Schwazenberg. 1951.
- [7]. Jan S.Grudziak, W.Timothy ward dega osteotomy for the treatment of congenital dysplasia of the hip. J.Bone Joint Surg, (American) 2001:83:845-854.
- [8]. King H.A. and coleman S.S. open reduction and femoral shortening on congenital of the hip orthop. Trans 4:302-303.1980.
- [9]. Klisic P congenital dislocation of hip a misleading term J.Bone joint surgery 1989:71B:136.
- [10]. Lorenz. A my life and work newyork Charles scrobner and sons 1936.
- [11]. Morel georges : The treatment of congenital dislocation of the hip. In the older child acta orthop. Scandinavica 4b: 364-399, 1975.
- [12]. Mirville . P on the anatomy and pathology of the hip joint acta orthop scand 1936:7:107.
- [13]. Muller G. Seddon H.Later results of treatment of congenital dislocation of the hip. JBJS 1953.35-A:342.
- [14]. Ortolani .M Un Sargno Polo noto e sue importanza per la diagnosi precoce di preussazione congenital dellanca pediatria 145:129.
- [15]. Osborne .D Effmann .E Broda K. et al. The developmental of the upper end of the femur with special reference to its internal architecture radiology 1980:137:71.
- [16]. Pemberton PA: Pericapsular osteotomy of the ilium for the treatment of congenital subluxation and dislocation of the hip. J. Bone Joint Surg. 1965:47A:65-86.
- [17]. Predrag kilsic, Ljubisa Jankovic: Combine procedure of open reduction and shortening of the femur in the treatment of congenital dislocation of the hip in older children. Clin orthop 1976:119:60-69.
- [18]. Rachid K Haidar, Richard S Jones, Diederick A.: Simultaneous open reduction and saltar innominate for developmental dysplasia of the hip. J. Bone Joint Surg 1996:78B:471-476.
- [19]. RR Rajendra, VI Tarasov, AO trammel & RA Khoshabaev: A one stage open reduction with salter's innominate osteotomy and corrective femoral osteotomy for the treatment of congenital dysplasia of the hip: The internet journal of orthopedic surgery 2003: Volume 1, Number 2.

Outcome analysis of Management of untreated Developmental Dysplasia of Hip by Klisic Procedure

- [20]. Salter RB: Innominate osteotomy in the treatment of congenital dislocation and subluxation of the hip. J. Bone Joint surg Br.1961.43:518-39.
- [21]. Schofield .C Smibert J. Trochanteric growth disturbance after upper femoral osteotomy for congenital dislocation of hip JBJS 1990;72B:32.
- [22]. Suzuki S. Yamamur T. Correlation of foetal posture and congenital dialocation of hip. Acta orthop scand 1986;57:81.
- [23]. Tachdjian's pediatric orthopaedics third edition P 513.
- [24]. Wyne-Davies R. Acetabular dysplasia and familial joint: laxity: two etiological factors in congenital dislocation of hip. J. Bone Joint Surg. 1970;52B:704.

Dr.M.Sathish,“Outcome analysis of Management of untreated Developmental Dysplasia of Hip by Klisic Procedure.” IOSR Journal of Dental and Medical Sciences (IOSR-JDMS), vol. 18, no. 2, 2019, pp 38-44.