

## Value of Adding Portal Vein Doppler with Ultrasound in Dengue Fever- What Radiologist Need to See??

Dr. Kumar Ashok Charan<sup>1</sup>, Dr. Parthasarathy. K R<sup>2</sup>, Dr. Mahesh K<sup>3</sup>, Dr. Vinay. M, Dr. Shashank G H<sup>3</sup>

<sup>1</sup>(Professor and Joint director. Department of radiology, Bokaro General Hospital. Bokaro steel city, Jharkhand)

<sup>2</sup>(Professor and head, department of radio diagnosis, SSIMS &RC/ RGUHS/ INDIA)

<sup>3</sup>(Junior Residents, department of radio diagnosis, SSIMS &RC/ RGUHS/ INDIA)

**Abstract:** Dengue being the most common arbo-viral disease and increasing epidemic of dengue has raised the need of cost effective and useful modality to know the complications and severity of dengue fever. Many studies has been done regarding the USG findings in dengue and complications. Our study aims at highlighting the value of adding portal venous doppler with USG in detecting the severity of complications of dengue.

**Key words:** USG, Dengue fever, portal vein doppler.

Date of Submission: 13-02-2019

Date of acceptance: 28-02-2019

### I. Introduction

Dengue fever is the most common and important arthropod-borne viral (arbovirus) illness in humans, a.k.a break bone fever. It is transmitted by mosquitoes of the genus *Aedes*, which are widely distributed in subtropical and tropical areas of the world. Which has 4 serotypes ( DEN 1-4), most often due to DEN-2<sup>1</sup>. The incidence of dengue has increased dramatically in recent decades, in India highest number of cases are reported from Maharashtra, Odisha, Tamilnadu, Karnataka and kerala<sup>2</sup>.

Main Pathophysiology is CLS (Capillary leak syndrome)<sup>3</sup>. Clinically seen as ascites, pleural effusion, gallbladder thickening and hepatosplenomegaly<sup>4</sup>.

Ultrasound has a role in detecting severity and progression of dengue infection. USG findings in dengue include oedematous and thickened GB wall (earliest sign), pericholecystic free fluid, ascites, pleural effusion, hepato-splenomegaly<sup>5,6</sup>.

In this study in addition to above findings Doppler of portal vein was done to detect capillary leakage syndrome.

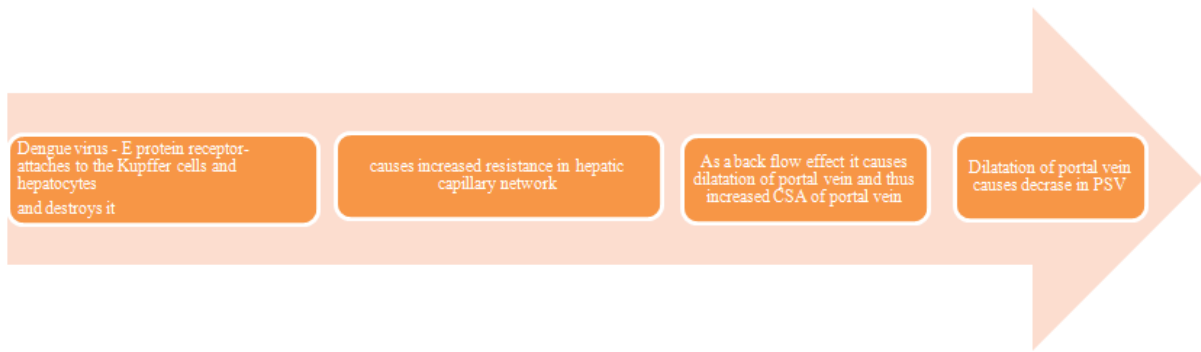### II. Aim

- USG features of capillary leak in dengue infection.
- Evaluating the role of adding doppler of portal vein to detect capillary leakage.

### III. Methods And Methodology:

- Prospective study done in Department of radiology SSIMS, Davangere Karnataka.
- **Study Design:** Cohort study.
- **Study population:** Patients with fever, thrombocytopenia, NS1 and other serological positive dengue features.
- **Study period:** JULY 2018 – JANUARY 2019
- **Sample size:** 52
- **Study technique:** USG of abdomen and chest performed using LOGIQ S7 expert and VOLVUSON 730 machines in both grey scale and colour Doppler. GB wall thickening is measured between the two layers of the anterior wall by placing the callipers. Liver is scanned in both intercostal and subcostal approach. Spleen is scanned in intercostal view. Thoracic scanning is done in either sitting or supine posture. Both the pleural spaces are evaluated through an intercostal approach. Portal vein is assessed in both grey scale and power doppler.

**Chart I:** Pathophysiology in dengue fever causing relative findings in USG and doppler

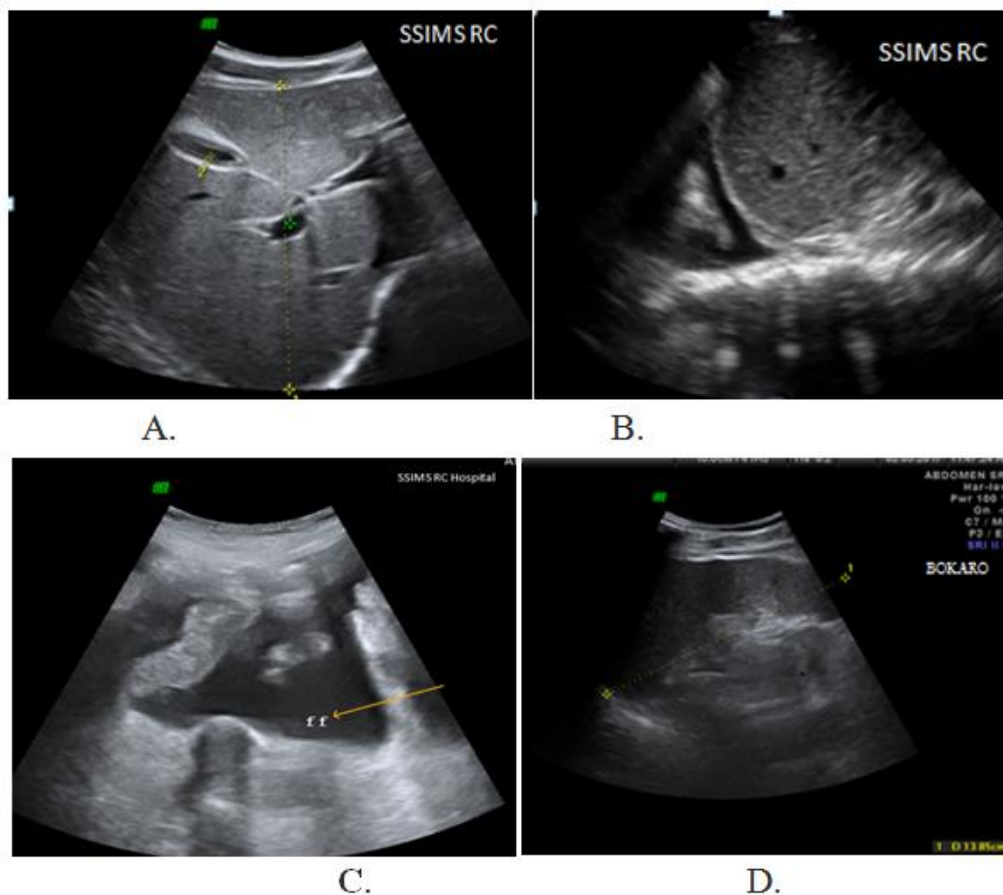


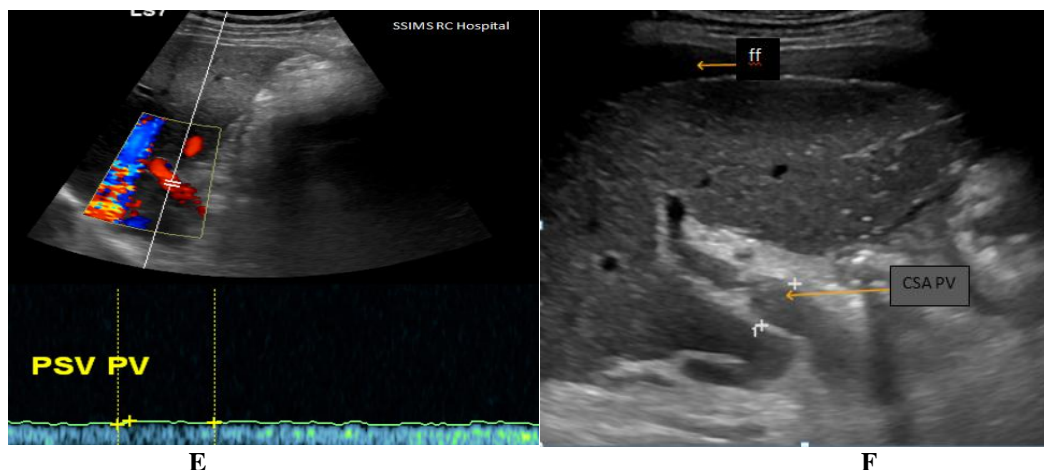
**USG features of dengue noted were:**

- Increased GB wall thickness.
- Pericholecystic free fluid and GB wall edema (Like a laminated/ onion peel appearance)
- Bibasal pleural effusion
- Ascites
- Hepato-splenomegaly. Hepatomegaly is considered when size of liver is > 15cm and splenomegaly when spleen size > 13cm.

**Power doppler assessment:**

- Grey scale of portal vein for its diameter and CSA. In dengue fever there is damage of sinusoidal kupfer and endothelial cells which causes increased resistance in hepatic capillary network. As a back flow effect it causes dilatation of portal vein and thus increased CSA of portal vein.
- Colour Doppler and spectral wave form assessment of portal vein for its flow (Hepatopetal / hepatofugal) and flow velocity<sup>7</sup>.
- Congestive index<sup>8</sup> = CSA/ Portal vein PSV cm/sec.





- A. Gallbladder edema and pericholecystic free fluid.
- B. Right sided basal pleural effusion.
- C. Free fluid in inter bowel loops and dependent parts of pelvis.
- D. Splenomegaly (Size- 13.8cm)
- E. PSV of portal vein – 18.2cm/sec
- F. CSA of portal vein – 15.2mm

#### IV. Results:

There is no sex distribution; both male and female were equally affected.

Common age group was between 15-24years. Capillary leak syndrome was found in 42 patients out of 52 patients (80.7%).

There were 29 (55.7 %) males and 23(44.3 %) females. Majority of them were between 15-24 years 30 patients (57.6%).

Gall bladder wall thickening and pericholecystic fluid was noted in majority 45 patient's (86.5%), of the study subjects followed by ascites in 26 (50%), whereas bilateral pleural effusion was observed in 8 (15.3%) cases only.

Splenomegaly was present in 27 (51.9%) subjects and hepatomegaly in 24(46.1%).

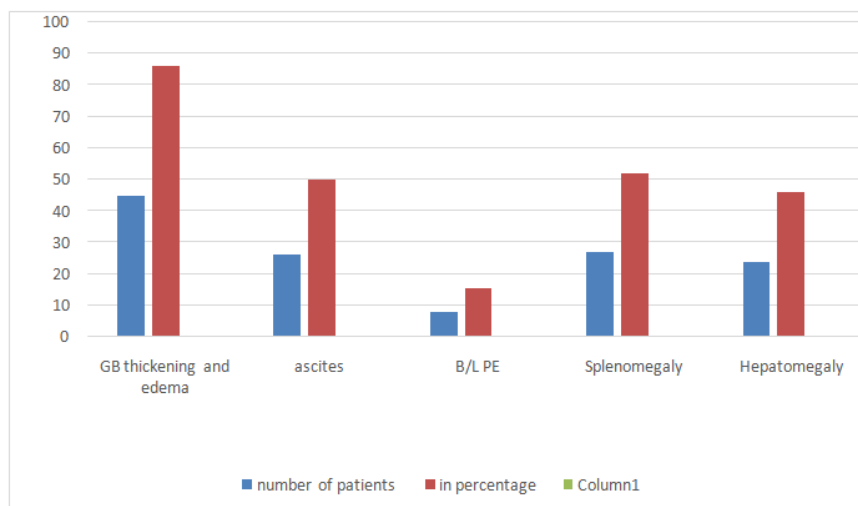
Mean portal vein diameter was 12.4mm in CLS positive and 10.8mm in CLS negative patients.

Mean PSV of portal vein was 17.4cm/sec in CLS positive and 24.8cm/sec in CLS negative patients.

Mean CSA of portal vein was 1.32cm<sup>2</sup> in CLS positive and 1.02cm<sup>2</sup> in CLS negative patients.

**Table no 1:** Shows different USG parameters and percentage among affected people

USG findings	Number of patients(out of 50)	Percentage (in %)
Gall bladder wall thickening and edema	45	86.5
Ascites	26	50
Bibasal pleural effusion	8	15.3
Splenomegaly	27	51.9
Hepatomegaly	24	46.1



Mean congestive index was 0.089 in CLS positive and 0.038 in CLS negative patients.

PSV of PV has higher sensitivity and significance.

Congestion index shows highest specificity.

Overall study shows USG in addition to portal vein Doppler has increased sensitivity and more PPV.

## V. Discussion

Dengue is emerging as one of the most important mosquito borne diseases in India. *Aedes aegypti* mosquitoes that transmit the disease breed in man-made containers such as tanks, pitchers, discarded containers etc. in which water has stagnated for over a week<sup>9</sup>.

Dengue has myriad clinical manifestations with unpredictable evolution and outcome. The disease typically begins with an acute febrile phase lasting 2-7 days and is accompanied by flushing, generalized body ache, myalgia, arthralgia and headache<sup>4</sup>. Increased capillary permeability reflected by progressive increase in hematocrit heralds the beginning of critical phase at around 3-7 days of illness. Severe hemorrhagic manifestations and shock secondary to plasma leakage may occur at this stage. Leucopenia and declining platelet counts are also seen preceding this stage.

Serological diagnosis is confirmatory of dengue and includes direct methods such as virus isolation and NS1 antigen detection and indirect methods such as IgM and IgG antibody detection.

It is in the recognition of the complications occurring in the critical phase that sonography has an increasingly important role. Sonography is a readily available, cost-effective method for the recognition of above complications and directly impacts the management of patients with dengue fever.

In our study the commonly recognized sonological abnormalities in the abdomen and thorax include thickening of gall bladder wall, ascites, pleural effusion, hepatomegaly and Splenomegaly. Thickening and edema of gall bladder wall was found to be the most frequent finding in our study.

Sensitivity of GB wall thickening with pericholecystic free fluid, ascites and pleural effusion were 70%, 42.5% and 46% with specificity of 95%, 90% and 100% respectively.

Sensitivity of PV diameter, PV velocity, CSA and congestive index were 75%, 90%, 55% and 60% with specificity of 75%, 70%, 85% and 100% respectively.

Thus our study confers USG features had an increased specificity with low sensitivity, while portal vein Doppler had an increased sensitivity and thus decreased false negative rate.

## VI. Conclusion:

Dengue being most common arthropod borne viral disease in India, USG findings with Doppler of portal vein has the higher efficiency in diagnosing capillary leak syndrome.

Thus USG combined with portal vein doppler of portal vein CSA, diameter, velocity and congestion index aids in early diagnosis of complications of dengue fever and predicting the outcome.

## References

- [1]. Shepard SD, Halasa YA, Tyagi BK, Adhish SV, Nandan D, Chellaswamy V et al. Economic burden of Dengue illness in India. *Am. J. Trop. Med. Hyg* 2014;91:1235-42.
- [2]. Govt. of India(2016), National Health profile 2015, DGHS, ministry of health and family welfare, New Delhi.
- [3]. Verma, Sudhir Kumar, Gutch, Manish, Agarwal, Abhishek & Vaish, AK. (2011). Capillary leak syndrome in dengue fever. WHO Regional Office for South-East Asia.
- [4]. Nimmannitya S. Clinical manifestations of dengue/dengue haemorrhagic fever. In *Monograph on Dengue/Dengue Haemorrhagic Fever*. Regional Publication No. 22. WHO Regional office for Southeast Asia. 1993:48-61.
- [5]. Pramuljo HS, Harun SR. Ultrasound findings in dengue haemorrhagic fever. *Pediatr Radiol*. 1991;21:100-102.
- [6]. Oliveira GA, Machado RC, Horvat JV, Gomes LE, Guerra LR, Vandestein L, et al. Transient reticular gallbladder wall thickening in severe dengue fever: a reliable sign of plasma leakage. *Pediatr Radiol* 2010;40:720-724.
- [7]. Ralls PW. Color Doppler sonography of the hepatic artery and portal venous system. *AJR Am J Roentgenol* 1990; 155:517-525.
- [8]. Moriyasu F, Nishida O, Ban N, Nakamura T, Sakai M, Miyake T, Uchino H, *AJR Am J Roentgenol*. 1986 Apr; 146(4):735-9
- [9]. WHO (2011). *Comprehensive Guidelines for Prevention and control of Dengue and Dengue Haemorrhagic Fever*, Revised and expanded edition, Regional office of SEAR.

Dr. Kumar Ashok Charan. "Value of Adding Portal Vein Doppler with Ultrasound in Dengue Fever- What Radiologist Need to See??" *IOSR Journal of Dental and Medical Sciences (IOSR-JDMS)*, Vol. 18, no. 02, 2019, pp. 27-30.