

Congenital Pseudoarthrosis of Clavicle: A Case Report

Cheong Keen Wah¹, Han Chung Sing²

^{1,2} (Department of Orthopaedics and Traumatology, Hospital Sultan Haji Ahmad Shah, Malaysia)

Abstract: Congenital pseudoarthrosis of the clavicle is a rare occurrence. This congenital defect usually involves the right side, of which the aetiology is still uncertain. The defect is usually benign. Surgical treatments such as plating and k-wiring are not indicated normally, except when there is presence of neurovascular deficit. As of now, this is the first recorded case in our centre.

Date of Submission: 10-12-2019

Date of Acceptance: 25-12-2019

I. Introduction

Congenital pseudoarthrosis of the clavicle is a rare defect of the shoulder girdle. The pathogenesis has not been identified. The defect of clavicle is usually unilateral on the right side, involving the middle third of clavicle.^{1,2} The defect is usually detected early as a swelling or asymmetry of the shoulder girdle. The diagnosis can be confirmed with radiography.

II. Case Report

A newborn boy, born term, via normal vaginal delivery, with no intrapartum complications, was admitted to neonatal ICU for transient tachypnea of the newborn. Chest X-ray was done, noted the absence of the lateral part of right clavicle, and was referred to orthopaedics team. Upon examination, there was a palpable bump on the right midclavicular area, which was non tender. Moro's reflex present. Patient showed no other signs of brachial plexus injury. This patient was discharged and followed up at our paediatric orthopaedic clinic.

Patient was then followed up at 2 months, 6 months, 1 year and 2 years. During the follow ups, there was no neurovascular deficit of the right upper limb. Range of movement of right shoulder was full. Parents only noted asymmetry of bilateral shoulders. Otherwise patient was active at home, with normal developmental milestones achieved.

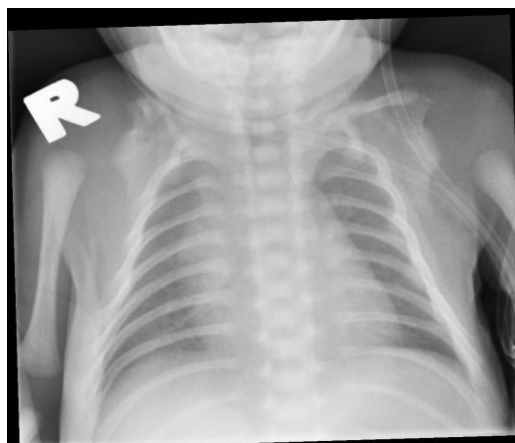


Fig-1 : Chest radiography of patient at birth. Absence of lateral portion of the right clavicle

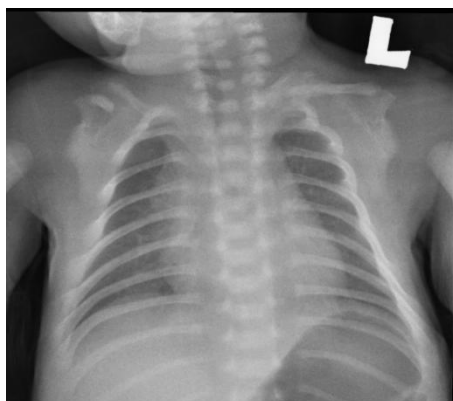


Fig-2 : Chest radiography of patient at 6 months of age.

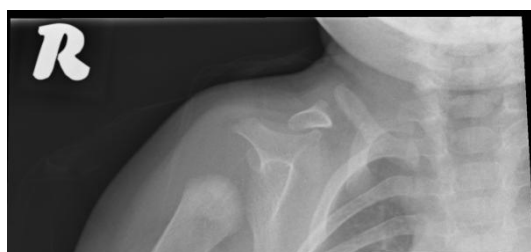

Fig-3 : Chest radiography of patient at 1 year of age.

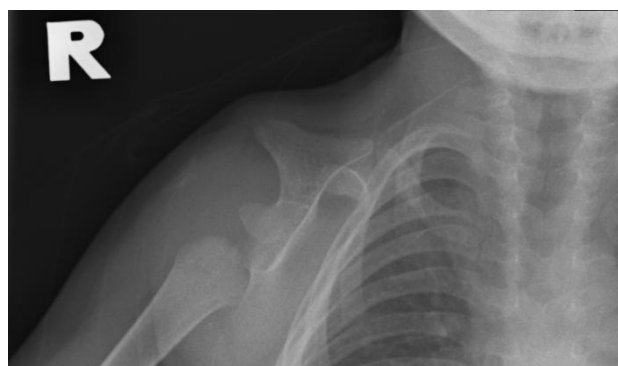

Fig-4 : Chest radiography of patient at 2 years of age.

III. Discussion

Congenital pseudoarthrosis of the clavicle was described by Fitzwilliams in 1910, as an entity different from cleidocranial dysostosis, posttraumatic pseudoarthrosis and neurofibromatosis.^{3,4} The peculiar part of this entity is that it almost always happen on the right clavicle, in 10% involvement is bilateral clavicle. The cases which involve the left clavicle are usually associated with dextrocardia.^{5,6}

Diagnosis of pseudoarthrosis of the clavicle is usually done at birth or during the first few months of life due to the midclavicular swelling. The most important clinical feature is the absence of pain, which sets it apart from traumatic non-union of the clavicle. Radiography usually shows the involvement of the middle third of the clavicle, with no signs of callus formation. The sternal segment usually overlies the clavicular segment. Malformations associated are :boomerang-shaped scapula, congenital elevation of the scapula, inter ventricular communication, dextrocardia and bilateral hip dysplasia.^{7,8,9,10}

Surgical treatment is controversial, with surgical indications of presence of symptoms, functional impairment and cosmetic deformities.^{11,12} During adulthood, pain, functional impairment and thoracic outlet syndrome may occur.¹³

IV. Conclusion

Congenital pseudoarthrosis of the clavicle is a benign condition which can be treated conservatively, unless there is presence of symptoms during adulthood.

References

- [1]. Behringer BR, Wilson FC. Congenital pseudoarthrosis of the clavicle. *Am J Dis Child* 1972 ; 123 : 511-517.
- [2]. Alldred AJ. Congenital pseudoarthrosis of the clavicle. *J Bone Joint Surg* 1963 ; 45-B : 312-319.
- [3]. Fitzwilliams DCL : Hereditary cranio-cleido-dystosis. *Lancet* 2 : 1466-1475, 1910
- [4]. Ahmadi B, Steel HH : Congenital pseudoarthrosis of the clavicle. *Clin Orthop* 126 : 130-134, 1977
- [5]. Bargar WL, Marcus RE, Ittleman FP. Late thoracic outlet syndrome secondary to pseudoarthrosis of the clavicle. *J Trauma* 1984 ; 24 : 857-859
- [6]. Garnier D, Chevalier J, Ducasse E et al. [Arterial complications of thoracic outlet syndrome and pseudoarthrosis of the clavicle : three patients] (in French). *J Mal Vasc* 2003 ; 28 : 79-84
- [7]. Hahn K, Shah R, Shalev Y et al. Congenital clavicular pseudoarthrosis associated with vascular thoracic outlet syndrome : case presentation and review of the literature. *Cathet Cardiovasc Diagn* 1995 ; 35 : 321-327.
- [8]. Lozano P, Doaz M, Riera R, Gomez FT. Venous thoracic outlet syndrome secondary to congenital pseudoarthrosis of the clavicle. Presentation in the fourth decade of life. *Eur J Vasc Endovasc Surg* 2003 ; 25 : 592-593.
- [9]. Cadilhac C, Fenoll B, Peretti A et al. Congenital pseudoarthrosis of the clavicle : 25 childhood cases. *Rev Chir Orthop* 2000 ; 86 : 575-580.
- [10]. Gibson DA, Carroll N. Congenital pseudoarthrosis of the clavicle. *J Bone Joint Surg* 1970 ; 52-B : 629-643.
- [11]. Gulino G, Ragazzi PG. Congenital pseudoarthrosis of the clavicle. Considerations on surgical treatment. *Chir Organi Mov* 1979 ; 65 : 701-706.
- [12]. Owen R. Congenital pseudoarthrosis of the clavicle. *J Bone Joint Surg* 1970 ; 52-B : 644-652.
- [13]. Varese LA, Lange MM. [Congenital pseudoarthrosis of the clavicle. Clinical contribution] (in Italian). *Minerva Pediatr* 1967 ; 19 : 2049-2052.

Cheong Keen Wah. "Congenital Pseudoarthrosis of Clavicle: A Case Report." *IOSR Journal of Dental and Medical Sciences (IOSR-JDMS)*, vol. 18, no. 12, 2019, pp 60-62.