

Large Submandibular Sialolith – A Case Study and a Review of Its Various Treatment Procedures

Dr. Anubhav Das Adhikari¹, Prof. (Dr.) Sudip Chakraborty²,
Prof. (Dr.) Richi Burman³

¹ 3rd Year PGT, Department of Oral & Maxillofacial Surgery, Guru Nanak Institute of Dental Sciences and Research, Panihati, Kolkata, India

² Professor, Department of Oral & Maxillofacial Surgery, Guru Nanak Institute of Dental Sciences and Research, Panihati, Kolkata, India

³ Professor, Department of Oral & Maxillofacial Surgery, Guru Nanak Institute of Dental Sciences and Research, Panihati, Kolkata, India

Abstract: Chronic sialadenitis is commonly associated with an acute chronic inflammation and obstruction of the excretory duct. The differentiation between chronic sialadenitis and obstruction of the excretory duct is difficult. The main causes of obstructive disorders are stones in about 60% to 70%, stenosis in about 15% to 25%, inflammation of the duct (sialodochitis) in about 5% to 10%, and other obstructions, such as anatomic variations or foreign bodies, in about 1% to 3%. We report the case of a 56-year-old man who had 3 large submandibular duct sialoliths. We describe the management of this patient and review the literature with emphasis on the various treatment modalities available.

Keywords: Large submandibular sialolith, Transoral, sialolithiasis

Date of Submission: 04-12-2019

Date of Acceptance: 19-12-2019

I. Introduction

Sialolithiasis is the second most common disease of the salivary glands after mumps¹. Sialolithiasis is the most common aetiology of obstructive sialadenitis, followed by stenosis and sialodochitis.

Sialolithiasis is estimated to affect 12 in 1000 of the adult population with males being affected almost twice as much as females^{2,3}. Children are very rarely affected⁴.

Stone formation is more frequent in areas where the duct is narrow or compressed⁵. More than 80% of the sialoliths occur in the submandibular gland or its duct, 6% in the parotid gland and 2% in the sublingual gland or minor salivary glands^{1,5,6}.

Simultaneous lithiasis in more than one salivary gland is rare, occurring in fewer than 3% of cases. Also, 70 to 80% of cases feature solitary stones; only about 5% of patients have three or more stones⁵.

Management of sialoliths depends on the stone size, location, number of stones and the extent of ductal obstruction. It is also the most common disease of submandibular glands in middle-aged adults⁷. There is no left or right predominance⁸.

The stones themselves are typically composed of calcium phosphate or calcium carbonate in association with other salts and organic material such as glycoproteins, desquamated cellular residue, and mucopolysaccharides.

Bacterial elements have not been identified at the core of a sialolith⁹.

Some factors inherent to the submandibular gland tend to favor stone formation there like longer and larger caliber duct, flow against gravity, slower flow rates and higher alkalinity along with higher mucin and calcium content of the saliva¹⁰.

The submandibular gland hosts the largest stones with the largest reported one being 6cm in length¹¹. Most submandibular stones are found in the salivary duct (75 to 85% of cases). Hilar stones tend to become very large before becoming symptomatic. Ductal stones are elongated in shape whereas hilar stones tend to be oval¹².

II. Case Study

A 56-year-old male patient reported to the Department of Oral and Maxillofacial Surgery, Guru Nanak Institute of Dental Sciences and Research, Kolkata following referral by a general dental practitioner, for fabrication of a removable partial denture and management of a firm mass in the anterior part of the floor of the mouth. History revealed that the patient was relatively asymptomatic for last 4 years as far as the mass is concerned. He has a h/o ingestion of acid due to family quarrel due to which he has a partial ankyloglossia. He was referred from the Dept. of Prosthodontics of the same institute for removal of the mass as it was obstructing the lingual flange of the proposed denture.

Intraoral examination showed a large mass, protruding and rupturing through the mucosa of the floor of the mouth on the left side. Mouth opening was less than 3 fingers (measured with patient's own fingers at interincisal region). Partial ankyloglossia was present. (Fig. 1)

On the basis of history and clinical examination, a diagnosis of left submandibular duct calculi was made. Mandibular occlusal radiograph showed 3 large radio opaque mass located in the left floor of the mouth, extending beyond the distal surface of the lower left second molar. A CT scan of the submandibular region was done which showed that the stones were present in the submandibular duct and were situated just below the floor of mouth and above the mylohyoid muscle layer. The stones were measured to be 21.3 mm, 9.02 mm and 13.8 mm along its greatest length(Fig. 2). Blood and serum biochemistry findings were within normal limits and his health history was unremarkable.

At a subsequent appointment, the stones were removed by a transoral approach under local anaesthesia (2% lignocaine with 1:80,000 adrenaline). The wound was left to heal by secondary intention. The total size of the calculi removed surgically was almost equal to the total length of the 3 calculi combined as measured previously from the CT scan (Fig. 3). The postoperative period was uneventful. The patient was advised to perform warm saline mouth rinses and prescribed analgesics and sialogogues.

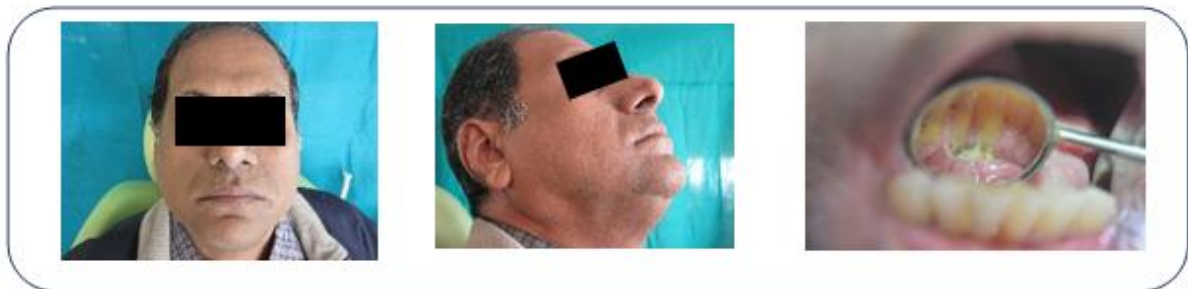

Fig. 1:Pre op pics

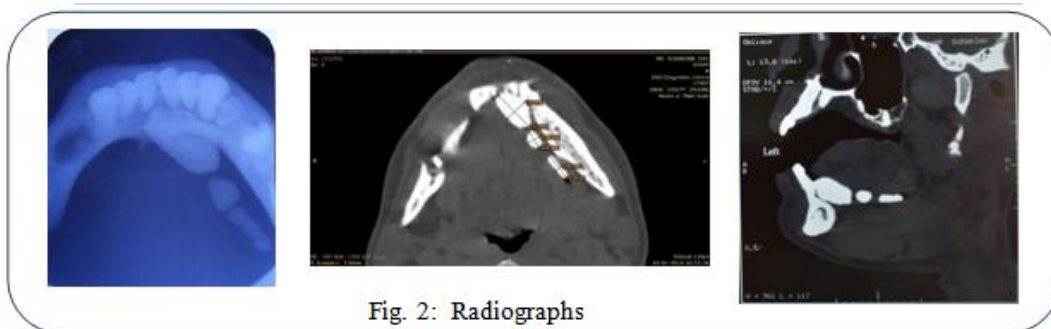


Fig. 2: Radiographs

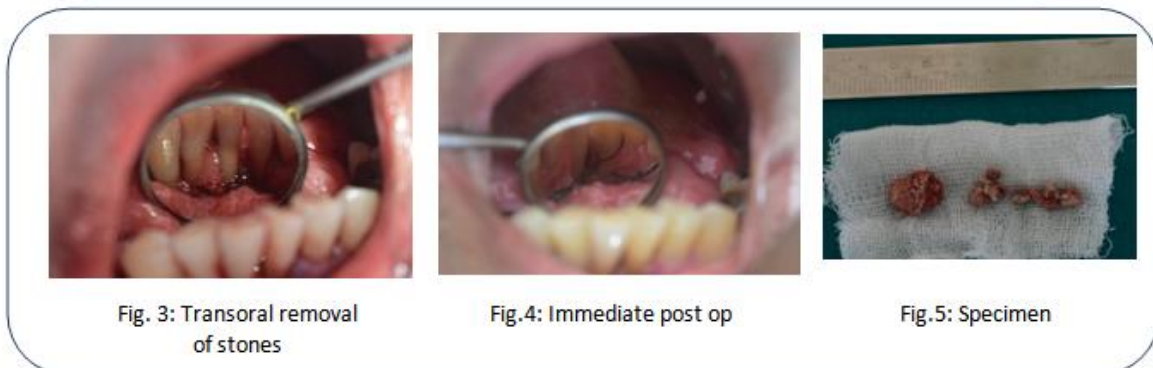


Fig. 3: Transoral removal of stones

Fig.4: Immediate post op

Fig.5: Specimen

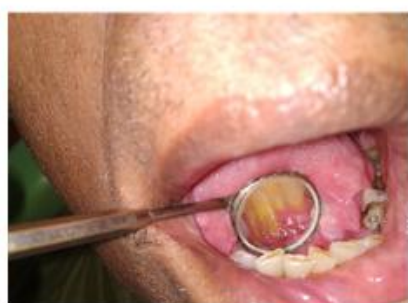

Fig.6: 6 months post op

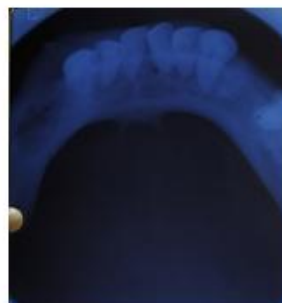

Fig.7: 6 months post op
occlusal radiograph

III. Discussion

Chronic sialadenitis is one of the major disorders that can cause salivary hypofunction and correct diagnosis and management is essential for its recovery. The classification of this pathological condition has changed in the past decade and nowadays was revised and modified, for new diagnostic (high-resolution ultrasonography, CT and MR sialography and sonoelastography) and therapeutic methods (sialoendoscopy) were introduced¹³. Sialolithiasis is the most common cause of inflammatory diseases of large salivary glands and occurs in about 1.2 % of the population^{14,15} mostly in the submandibular gland—87 %. Salivary gland stones are single or multiple, located in the efferent duct distally or proximally, rarely occur intraparenchymally, representing various shapes and sizes. The annual increase in size of salivary stones is estimated at 1 mm¹⁶, and thus the duration of complaints history is crucial for treatment planning.

This particular patient was asymptomatic even with such a large stone protruding into his oral cavity through the floor of mouth. The particular h/o ingestion of acid may have led to formations of strictures in the duct or may have altered the anatomy of ductal epithelium. Either of which would have led to stasis of salivary flow resulting in sedimentation and hence stone formation.

Contemporary achievement in endoscopy caused strong common belief that stones of up to 4–5 mm in diameter can be successfully removed through sialoendoscopy (SE). This applies specially to stones which lie freely in the lumen of the duct and are mobile. In these cases, the stones can be extracted under endoscopic control in more than 80 % of cases^{14,16,17}. Larger sialoliths may, however, be fragmented in the lumen of the duct, either mechanically or using a laser beam. Extracorporeal Shock Wave Lithotripsy (ESWL) is another possibility for the fragmentation of large sialoliths of any size and location; although up to three sessions of lithotripsy may be required. Thus, the introduction of sialoendoscopy has significantly reduced the number of submandibular glands removal in the course of sialolithiasis^{14,16,17,18,19,20}. According to literature data, the use of lithotripsy is effective in 75 % of cases, and in turn, allows for the complete retrieval of stones in half of the cases^{18,19,21,22,23}. The number of successes in the use of lithotripsy clearly decreases with increase in the stone diameter.

Despite notable technological progress, 5–10 % of patients with sialolithiasis cannot be successfully treated using minimally invasive techniques²⁴. The main cause appears to be the large size of the stones and long-standing history of recurrent inflammations, which lead to the impaction of the sialolith to the wall of the efferent duct. In these cases, the complete removal of the submandibular gland is indispensable.

According to Bigler²⁵, Harrison²⁶, Yoel²⁷, Work¹⁰, Wang et al.²⁸, there are two particular subdivisions: chronic obstructive (sialolithiasis, stenosis of the duct, inflammation of the glandular tissue with recurrent stenosis or enlargement of the duct) and nonobstructive group of inflammations.

Diagnosis of sialolithiasis is based on its clinical presentation and symptoms. Painful, rapidly increasing salivary colic character is exhibited especially during mealtime. This agonizing experience may even occur without any component of mechanical obstruction, although presence of lithiasis is the main cause in 50 % of affected individuals. High-resolution ultrasonography could be utilized as an optional diagnostic method for visualization of calcified deposits or exclusion of tumor presence²⁹. The main feature of sialography is excision, constriction or enlargement of the excretory ducts. It is not utilized during acute states. Ultrasonographic confirmation of either ductal stricture or presence of intraparenchymal stones allow postponing the sialoendoscopy procedure until the acute state has subsided^{13,17,19}. High-resolution computed tomography is still considered to be the most sensitive method for the determination of stones, whereas the ultrasonographic technique allows to view a sialolith < 2 mm. Increased accumulation of inorganic calcified uncommon to overlook miniscule remnants of the stones due to insufficient signal saturation. However, it is important to emphasize that false positive results could be obtained in case of excessive hyperemia caused by inflammation of the duct. In these particular situations, sialoendoscopy is considered superior. Classic

sialography, sialography performed by utilization of computed tomography or by magnetic resonance imaging, is an instrumental addition to the diagnostic evaluation; however, many authors prefer high-resolution ultrasonography²⁹.

The use of endoscopic and minimally invasive techniques allows for the greater preservation of the major salivary glands in cases of sialolithiasis. According to literature data, 80–90 % of patients with parotid gland sialolithiasis can be treated using minimally invasive techniques such as sialoendoscopy and ESWL^{14,16,17,18,19,22,29,30,31}. It should be remembered that stones larger than 6 mm in diameter and impacted in the wall of the duct limit the possibility of using sialoendoscopy^{14,16,17,30,31}. After performing ESWL, larger stones (larger than 8–10 mm in diameter) can successfully be fragmented and then removed using a sialoendoscopy.

It is valuable to include a diagnostic and therapeutic procedure developed by Koch³¹ (Fig. 8). Sialoendoscopy is considered as a significant diagnostic and therapeutic method of primary treatment. In situation in which there is a limited access to ESWL, a double approach could be used as an alternative method of treatment in both parotid and submandibular glands^{32,33,34,35,36}.

The most conservative method of treatment, as well as the one that provides us with the least number of unfavourable outcomes, is the main objective for those affected by a chronic inflammatory process.

According to the literature, in the vast majority of cases, surgical intervention could be replaced with a minimally invasive procedure by utilization of diagnostic and therapeutic sialoendoscopy procedures^{19,31,32,34}.

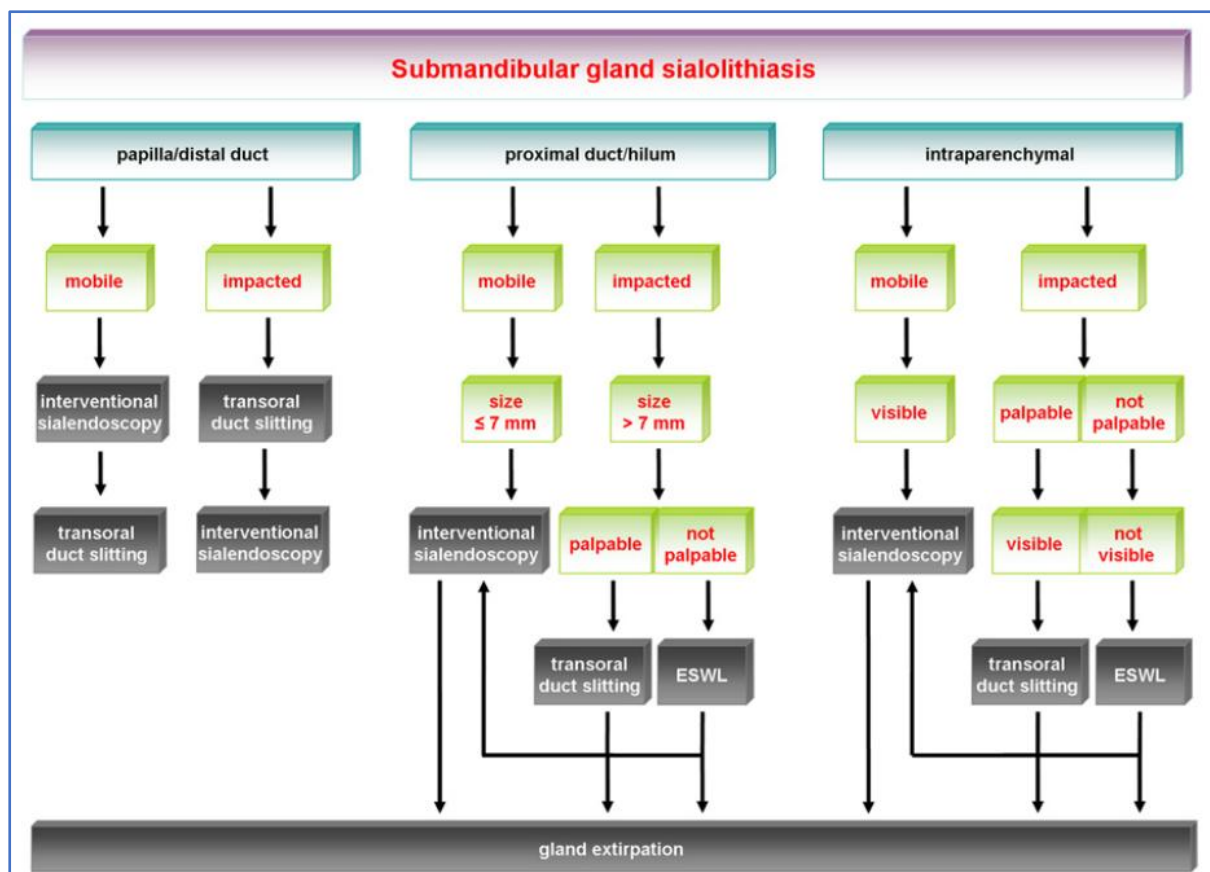


Fig. 8: Algorithm of salivary gland obstructive pathology treatment, according to Koch et al

IV. Conclusion

With the advent of new diagnostic and therapeutic methods, it is imperative to verify current classification of chronic inflammation of large salivary glands. Critical analysis of literature reviews indicate that continuous improvement of current methods and introduction of new ones, such as utilization of sialoendoscopy are crucial in treatment of pathological obstructions of salivary glands. However, in this particular case sialoendoscopy was not advocated as there was limited mouth opening (due to h/o ingestion of acid) and also the stones were situated at a very superficial level and were easily retrievable through transoral approach.

References

- [1]. Levy DM, ReMine WH, Devine KD. Salivary gland calculi: pain, swelling associated with eating. *Jama*. 1962 Sep 29;181(13):1115-9.
- [2]. Leung AK, Choi MC, Wagner GA. Multiple sialoliths and a sialolith of unusual size in the submandibular duct A case report. *Oral Surgery, Oral Medicine, Oral Pathology, Oral Radiology, and Endodontology*. 1999 Mar 1;87(3):331-3.
- [3]. Cawson RA, Odell EW. *Essentials of oral pathology and medicine*. London: Churchill Livingstone. 1998:228-57.
- [4]. Steiner M, Gould AR, Kushner GM, Weber R, Pesto A. Sialolithiasis of the submandibular gland in an 8-year-old child. *Oral surgery, oral medicine, oral pathology, oral radiology, and endodontics*. 1997 Feb;83(2):188.
- [5]. McKenna JP, Bostock DJ, McMenamin PG. Sialolithiasis. *American family physician*. 1987 Nov;36(5):119-25.
- [6]. Perrotta RJ, Williams JR, Selfe RW. Simultaneous bilateral parotid and submandibular gland calculi. *Archives of Otolaryngology*. 1978 Aug 1;104(8):469-70.
- [7]. Gregg JM, Kruger GO. *Textbook of oral and maxillofacial surgery*.
- [8]. Yildirim A. A case of giant sialolith of the submandibular salivary gland. *Ear, nose & throat journal*. 2004 May;83(5):360-1.
- [9]. Williams MF. Sialolithiasis. *Otolaryngologic Clinics of North America*. 1999 Oct 1;32(5):819-34.
- [10]. Work WP, Batsakis IG (1977) Classification of salivary gland diseases. *Otolaryngol Clin North Am* 10:287–296
- [11]. Vittal U, Shetty SC, Manvikar P, Kini U, Gupta S. Giant Sialolith (megalith) of submandibular salivary gland. *Australian Journal of Oto-Laryngology*. 2002 Apr 1;5(1):43.
- [12]. Akin I, Esmer N. A submandibular sialolith of unusual size: a case report. *The Journal of otolaryngology*. 1991 Apr;20(2):123-5.
- [13]. Kopeć T, Wierzbicka M, Szyfter W. A proposal for the classification of chronic sialadenitis of the major salivary glands with current diagnostic and treatment schedule. *Otolaryngologia polska: The Polish otolaryngology*. 2011;65(3):188-93.
- [14]. Koch M, Zenk J, Iro H. Diagnostic and interventional sialoscopy in obstructive diseases of the salivary glands. *Hno*. 2008 Feb;56(2):139-44.
- [15]. Rice DH. Noninflammatory, non-neoplastic disorders of the salivary glands. *Otolaryngologic Clinics of North America*. 1999 Oct 1;32(5):835-42.
- [16]. Marchal F, Dulguerov P. Sialolithiasis management: the state of the art. *Archives of Otolaryngology–Head & Neck Surgery*. 2003 Sep 1;129(9):951-6.
- [17]. Katz P. New techniques for the treatment of salivary lithiasis: sialoendoscopy and extracorporeal lithotripsy: 1773 cases. In *Annales d'oto-laryngologie et de chirurgie cervicofaciale: bulletin de la Societe d'oto-laryngologie des hopitaux de Paris* 2004 Jun (Vol. 121, No. 3, pp. 123-132).
- [18]. Iro H, Dlugaiczyk J, Zenk J. Current concepts in diagnosis and treatment of sialolithiasis. *British Journal of Hospital Medicine* (2005). 2006 Jan;67(1):24-8.
- [19]. Iro H, Zenk J, Escudier MP, Nahlieli O, Capaccio P, Katz P, Brown J, McGurk M. Outcome of minimally invasive management of salivary calculi in 4,691 patients. *The Laryngoscope*. 2009 Feb;119(2):263-8.
- [20]. Thomas BL, Brown JE, McGurk M. Salivary gland disease. In *Salivary Glands 2010* (Vol. 14, pp. 129-146). Karger Publishers.
- [21]. Capaccio P, Ottaviani F, Manzo R, Schindler A, Cesana B. Extracorporeal lithotripsy for salivary calculi: a long- term clinical experience. *The Laryngoscope*. 2004 Jun;114(6):1069-73.
- [22]. Escudier MP, Brown JE, Drage NA, McGurk M. Extracorporeal shockwave lithotripsy in the management of salivary calculi. *British Journal of Surgery*. 2003 Apr;90(4):482-5.
- [23]. Schmitz S, Zengel P, Alvir I, Andratschke M, Berghaus A, Lang S. Long-term evaluation of extracorporeal shock wave lithotripsy in the treatment of salivary stones. *The Journal of Laryngology & Otology*. 2008 Jan;122(1):65-71.
- [24]. Kopeć T, Szyfter W, Wierzbicka M. Sialoendoscopy and combined approach for the management of salivary gland stones. *European Archives of Oto-Rhino-Laryngology*. 2013 Jan 1;270(1):219-23.
- [25]. Bigler JA (1946) Salivary gland infection. *Pediatr Clin North Am* 27:933–942
- [26]. Harrison JD. Causes, natural history, and incidence of salivary stones and obstructions. *Otolaryngologic clinics of North America*. 2009 Dec 1;42(6):927-47.
- [27]. Yoel J (1975) *Pathology and surgery of the salivary glands*. Charles and Thomas, Denver: Springfield
- [28]. Wang S, Marchal F, Zou Z, Zhou J, Qi S. Classification and management of chronic sialadenitis of the parotid gland. *Journal of oral rehabilitation*. 2009 Jan;36(1):2-8.
- [29]. Zenk J, Iro H, Klintworth N, Lell M. Diagnostic imaging in sialadenitis. *Oral and Maxillofacial Surgery Clinics*. 2009 Aug 1;21(3):275-92.
- [30]. Marchal F, Dulguerov P, Becker M, Barki G, Disant F, Lehmann W. Specificity of parotid sialendoscopy. *The Laryngoscope*. 2001 Feb;111(2):264-71.
- [31]. Nahlieli O, Shacham R, Bar T, Eliav E. Endoscopic mechanical retrieval of sialoliths. *Oral Surgery, Oral Medicine, Oral Pathology, Oral Radiology, and Endodontology*. 2003 Apr 1;95(4):396-402.
- [32]. Koch M, Zenk J, Iro H. Algorithms for treatment of salivary gland obstructions. *Otolaryngologic Clinics of North America*. 2009 Dec 1;42(6):1173-92.
- [33]. Koch M, Bozzato A, Iro H, Zenk J. Combined endoscopic and transcutaneous approach for parotid gland sialolithiasis: indications, technique, and results. *Otolaryngology--Head and Neck Surgery*. 2010 Jan;142(1):98-103.
- [34]. Kopeć T, Szyfter W, Wierzbicka M. Sialoendoscopy and combined approach for the management of salivary gland stones. *European Archives of Oto-Rhino-Laryngology*. 2013 Jan 1;270(1):219-23.
- [35]. Marchal F. A combined endoscopic and external approach for extraction of large stones with preservation of parotid and submandibular glands. *The Laryngoscope*. 2007 Feb;117(2):373-7.
- [36]. McGurk M, MacBean AD, Fan KF, Sproat C, Darwish C. Endoscopically assisted operative retrieval of parotid stones. *British Journal of Oral and Maxillofacial Surgery*. 2006 Apr 1;44(2):157-60.
- [37]. Walvekar RR, Bomeli SR, Carrau RL, Schaitkin B. Combined approach technique for the management of large salivary stones. *The Laryngoscope*. 2009 Jun;119(6):1125-9.

Dr. Anubhav Das Adhikari. "Large Submandibular Sialolith – A Case Study and a Review of Its Various Treatment Procedures." *IOSR Journal of Dental and Medical Sciences (IOSR-JDMS)*, vol. 18, no. 12, 2019, pp 11-15.