

Possible Prediction of Cervical Lymph Node Metastasis in Papillary Carcinoma of Thyroid

Dr. Anandaravi. B.N, Dr. Archa Kilikar

Associate professor, Department of general surgery, Mysore medical college and research institute, India Post graduate, Department of general surgery, Mysore medical college and research institute, India

Corresponding Author: Dr. Anandaravi. B.N.

Abstract

OBJECTIVE

Papillary thyroid carcinomas (PTC) frequently metastasize to regional lymph nodes. Our purpose was to investigate the predictive role of tumor location for lymph node metastasis pattern in PTCs.

METHODS

Medical records of 50 PTC patients were reviewed retrospectively. Tumor location was determined as upper, middle, and lower pole according to ultrasonography (USG) findings. The effects of tumor size, and location on lymph node metastasis were investigated.

RESULTS

The series comprised 87% females ($n = 43$) and 13% males ($n = 7$). Nineteen patients had central neck metastasis (CNM) and 12 had lateral neck metastasis (LNM). Upper pole tumors (UPT) metastasized to the central neck (CN) at a lower rate (17.6%) than middle (40.0%) or lower (48.5%) poles overall ($P = 0.104$), while it was at a significantly lower rate (13.3%) in the PTC group ($P < 0.05$). UPTs ($n = 17$) metastasized to the lateral neck (LN) almost 2-fold more. It was observed that 3 of 4 UPTs spread directly to the LN without CNM.

CONCLUSION

In our opinion, UPTs have propensity to demonstrate metastasis to Lateral neck nodes, rather than the Central nodes in PTCs. Therefore, UPTs should be evaluated meticulously in terms of LNM and thereby could suggest modified neck dissection and CN dissection is not performed for low-risk PTCs in UPTs.

Date of Submission: 02-12-2019

Date of Acceptance: 18-12-2019

I. Introduction

Papillary carcinoma accounts for 80% of all thyroid malignancies in iodine-sufficient areas and is the predominant thyroid cancer in children and individuals exposed to external radiation. Papillary carcinoma most commonly occur in women, with a 2:1 female-to-male ratio, and the mean age at presentation is 30 to 40 years. Most patients are euthyroid and present with a slow-growing painless mass in the neck. Most patients with PTC can expect an excellent prognosis, with the 10-year survival rate greater than 95%. Most thyroid cancers drain directly to central nodal basins (level VI) except for cancers in the superior third of the gland, which may drain directly to the lateral compartment (so-called skip metastases).

The extent of surgical resection that is necessary for adequate removal of metastatic disease is controversial. Various procedures have been proposed for the treatment of malignant lymphadenopathy, including radical ND, modified radical ND, ^{1,2} sentinel node biopsy, ³ and selective lymph node excision. ⁴ Bilateral NDs have also been advocated by some surgeons. ^{5,6}

There is no clear consensus regarding the appropriate levels of the neck that must be removed ⁷

Most surgeons recommend a modified radical ND, sparing the internal jugular vein, spinal accessory nerve (cranial nerve XI), and the sternocleidomastoid muscle. Its implication in the treatment of metastatic thyroid carcinoma is debatable. Extension to level VI and mediastinal nodal stations is common; but no predictable pattern for lateral metastasis has been established.

II. Materials and Methods

A retrospective study was conducted on 50 patients diagnosed pre-operatively as papillary carcinoma thyroid during the period of January 2016- January 2019 in the department of general surgery, K.R. Hospital Mysore.

Study design: retrospective study

Study location: this was a tertiary care teaching hospital based study done in Department of General Medicine, at Mysore medical college and research institute, Mysore , Karnataka , India.

Study duration: January 2016 to January 2019.

Sample size: 50 patients.

Subjects and selection method: the study population was formulated by The last preoperative radiological reports, fine needle aspiration cytology (FNAC) results, operation notes, and postoperative histopathological results were reviewed in detail. Tumor location was determined as upper, middle or lower pole according to ultrasonography (USG) and CT (computed tomography) findings. The effects of tumor size and location on lymph node metastasis were investigated.

Inclusion criteria: The patients in this study were only those who underwent total thyroidectomy (TT) plus either only central neck dissection (CND) or CND with lateral neck dissection (LND).

Exclusion criteria: 1. Patients were excluded if revision or complementary thyroid surgery was performed, if there were benign causes, or if other histological types of thyroid carcinoma were determined.

2. Multifocal or multicentric tumors were also excluded.

Procedure methodology: patients in this study were selected, who were admitted in the department of general surgery , Mysore medical college and research institute diagnosed with papillary carcinoma thyroid, through FNAC and confirmed by postoperative histopathology. The patients in this study were only those who underwent total thyroidectomy (TT) plus either only central neck dissection (CND) or CND with lateral neck dissection (LND). CND was performed bilaterally to all patients whose FNAB results were malignant. LND was performed if lateral cervical lymph node metastasis was evident radiologically or confirmed by ultrasound-guided FNAC and routinely included neck levels 2, 3, and 4. Tumor location was determined as upper, middle or lower pole according to ultrasonography (USG) and CT (computed tomography) findings. The effects of tumor size and location on lymph node metastasis were investigated.

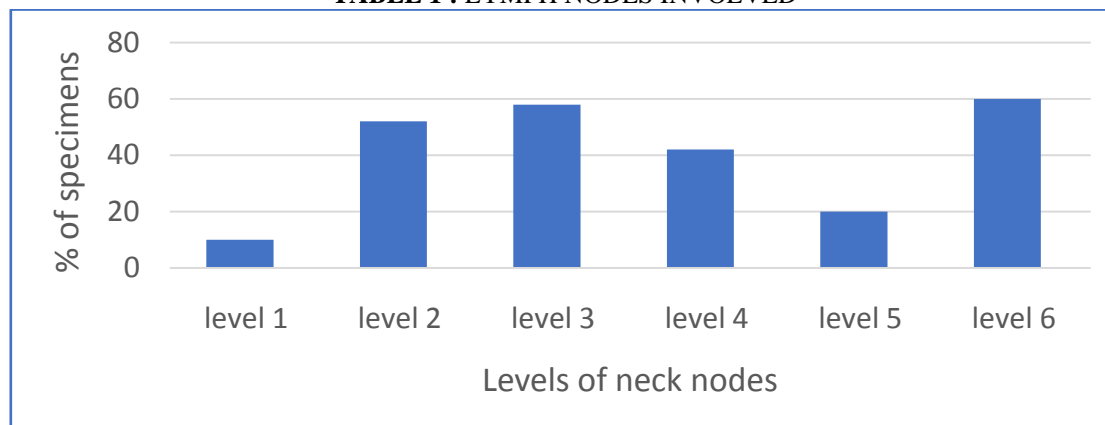
Statistical analysis: used were percentage, mean and standard deviation.

III. Results

The study included a total of 50 patients who underwent either TT + CND and/or TT + CND + LND. The series comprised 87% females (n = 43) and 13% males (n = 7).

Nineteen patients had central neck metastasis (CNM) and twelve had lateral neck metastasis (LNM). Hence level 6 lymph node involvement was seen in majority followed by level 3.

TABLE 1 : LYMPH NODES INVOLVED



Overall Upper pole tumors (UPT) metastasized to the central neck (CN) at a lower rate (17.6%) than middle (40.0%) or lower (48.5%) poles (P = 0.104), UPTs (n = 17) metastasized to the lateral neck (LN) almost 2-fold more. It was observed that 3 of 4 UPTs spread directly to the LN without CNM.

Table 2: Relationship between tumor location and metastases

LOCATION	LOWER	MIDDLE	UPPER	TOTAL
Central metastasis	48.5%	40%	17.6%	35.36
Lateral metastasis	10.8%	21.6%	26.7%	19.7

IV. Discussion

It has been previously established that regional metastasis from PTC is most commonly found in the central compartment.⁵ Metastasis to regional nodes is common in patients & this has been reported to have increased recurrence and compromised survival^(6,7) Decreasing the 5 year survival from 99% to 97% and higher regional recurrence rates⁸ Metastases to the lateral neck have been found to have higher recurrence rates than metastases to the central compartment

Consensus has been reached on the decision for lymph node dissection if the central or lateral neck has evident lymph node metastasis⁽⁸⁾ In many studies, it has been indicated that lymph node dissection has reduced recurrence and has been a positive effect on survival^(9,10).

Many authors researched the effect of intrathyroidal tumor location on the pattern of lymph node metastasis and concluded that tumors located in the upper pole tend to metastasize to the LN more frequently in PTC. It was emphasized that the LN must be examined carefully if the tumor is identified in the upper pole during the preoperative evaluation.

PTC mostly presents a sequential lymph node metastasis pattern, although a discontinuous lymph node metastasis pattern is also possible.

Zhang et al. (10) investigated the relationship between primary tumor location and nodal metastasis risk and concluded that upper pole location is a low risk for the central region but high risk for lateral region metastases. American Head and Neck Society Consensus mentioned PTC arising in the upper pole of the thyroid has a higher propensity to demonstrate skip metastases to levels III and II of the lateral compartment¹¹.

V. Conclusion

The lymph node metastasis pattern of primary tumors located in the upper pole of the thyroid gland differs from those with middle and lower pole localization.

According to this study, upper pole-located tumors have propensity to demonstrate metastasis to LN. We consider that UPTs should be evaluated more carefully preoperatively and routine CND should not be applied to these patients if there are no other prognostic risk factors, and thus reduce the risk of RLN injury and parathyroid injury and the postoperative morbidity associated with the same.

And hence a comprehensive ND, would help the patient to have lesser morbidity associated with surgery and improved survival rate .

References

- [1]. Shaha AR. Management of the neck in thyroid cancer. *Otolaryngol Clin North Am.* 1998;31:823-831.
- [2]. Noguchi S, Murakami N. The value of lymph node dissection in patients with differentiated thyroid cancer. *Surg Clin North Am.* 1987;67:251-261.
- [3]. Fukui Y, Yamakawa T, Taniki T, Numoto S, Miki H, Monden Y. Sentinel lymph node biopsy in patients with papillary thyroid carcinoma. *Cancer.* 2001;92:2868-2874.
- [4]. Balazs G, Gyory F, Lukacs G, Szakall S. Long-term follow-up of node-positive papillary thyroid carcinomas. *Langenbecks Arch Surg.* 1998;383:180-182.
- [5]. Noguchi S, Noguchi A, Murakami N. Papillary carcinoma of the thyroid, I: developing pattern of metastasis. *Cancer.* 1970;26:1053-1060.
- [6]. Adam MA, Pura J, Goffredo P, Dinan MA, Reed SD, Scheri RP, Hyslop T, Roman SA, Sosa JA. Presence and number of lymph node metastases are associated with compromised survival for patients younger than age 45 years with papillary thyroid cancer. *J Clin Oncol* 2015; 33: 2370-2375
- [7]. Liu FH, Kuo SF, Hsueh C, Chao TC, Lin JD. Postoperative recurrence of papillary thyroid carcinoma with lymph node metastasis. *J Surg Oncol* 2015; 112: 149-54.
- [8]. Sturgeon C, Yang A, Elaraj D. Surgical management of lymph node compartments in papillary thyroid cancer. *Surg Oncol Clin N Am* 2016; 25: 17-40.
- [9]. Tang T, Li J, Zheng L, Zhang L, Shi J. Risk factors of central lymph node metastasis in papillary thyroid carcinoma: a retrospective cohort study. *Int J Surg* 2018; 54: 129-132
- [10]. Zhang L, Wei WJ, Ji QH, Zhu YX, Wang ZY, Wang Y, Huang CP, Shen Q, Li DS, Wu Y. Risk factors for neck nodal metastasis in Papillary thyroid microcarcinoma: a study of 1066 patients. *J Clin Endocrinol Metab* 2012; 97: 1250-1257.
- [11]. Agrawal N, Evasovich MR, Kandil E, Noureldine SI, Felger EA, Tufano RP, Kraus DH, Orloff LA, Grogan R, Angelos P et al. Indications and extent of central neck dissection for papillary thyroid cancer: an American Head and Neck Society Consensus Statement. *Head Neck* 2017; 39: 1269-1279. 21

Dr. Anandaravi. B.N.. "Possible Prediction of Cervical Lymph Node Metastasis In Papillary Carcinoma of Thyroid." *IOSR Journal of Dental and Medical Sciences (IOSR-JDMS)*, vol. 18, no. 12, 2019, pp 38-40.