

Effectiveness of *Attaivaldal* (Leech Therapy) with Siddha Medicine Forthe Management of Medial Malleolar Bursitis-A Case Report Study

D Periyasami^{1*}, Vrindha K V², K Aarthy³, N J Muthukumar⁴

¹Lecturer, Department of SirappuMaruthuvam, National Institute of Siddha, Chennai-47, India

²P G Scholar, Department of VarmaMaruthuvam, National Institute of Siddha, Chennai-47, India

³P G Scholar, Department of SirappuMaruthuvam, National Institute of Siddha, Chennai-47, India

⁴Head of the Department, Department of SirappuMaruthuvam, National Institute of Siddha, Chennai-47, India

*Corresponding Author- D Periyasami, Lecturer, Department of SirappuMaruthuvam, National Institute of Siddha, Chennai-47, India

Abstract:

Attaivaldal(leech therapy) is one of the external therapy in Siddha system of medicine, in which medicinal leeches were used to treat various medical and surgical condition like, gouty arthritis, abscess, sprain, contusion, ulcers, skin diseases and other pitha diseases like *veekkam*(traumatic swelling), *valiazhalkeelvaayu*(rheumatoid arthritis)etc [1]. Leeches removes the blood from their host, and they release the substances like analgesic, anti-inflammatory, antibiotic, anaesthetic and anticoagulant from their saliva [2]. Current treatment procedure for medial malleor bursitis is use of topical application, NSAIDS (non-steroidal anti-inflammatory drugs), local anesthetics, drainage of the fluid from bursa,steroidal injections and surgery which are produce many side effects[3]. In Siddha system of medicine this common ailment is treated with oil bath, *Viresanam*(Purgation), internal medicine and bloodletting with *attai*. It can provide painless, cost effective and simple way of treatment for Bursitis without any adverse effect. A 45 yearsold female patient was reported at the Outpatient department of Ayothidoss pandithar Hospital, National Institute of Siddha with the complaints of pain, swelling and restricted movements over left medial malleolar area since 8 months. *Attaivaldal* (leech therapy) was planned for this condition and Prognosis of the patient assessed using Universal pain scale, Visual analog scale and Foot and ankle disability index (FADI). There was significant reduction observed in universal pain scale and other symptom score after treatment.

Keywords: *Attaivaldal*, leech therapy, bursitis, Siddha, bloodletting

Date of Submission: 02-12-2019

Date of Acceptance: 18-12-2019

I. Introduction

Attaivaldal (Leech therapy) is described as one of the type of external therapy in Siddha System. In Siddha classical texts *Attaivaldalis* was indicated for traumatic swelling, tumours, sprain, skin diseases, head ache, bleeding haemorrhoids, splenomegaly, headache induced by amenorrhea, arthritis, and some kind of eye diseases [4]. There are about 600-650 species were found around the world, out of this only 15-20 are used for treatment purpose. *Hirudomedicinalis* is the commonly using leeches for treatment purpose in western countries. In India, the leech *Hirudoventralis*(Indian cattle leech) is used for medicinal purpose. Leeches which were sometimes an indispensable part of medical practice in 19th century were lost in the advanced scientific world but has again seen light in modern plastic reconstructive surgery. Leeches work by virtue of wound puncture leading to bleeding, anesthetizing the wound and prevent clotting, also dilate the bloodvessels to increase blood flow. Hyaluronidase(an enzyme in leech saliva), which increases the local spread of leech saliva through human tissue at wound site has also antibiotic properties. Proteins and peptides with tremendous clinical applications have been identified in leech saliva[5].

A bursa is a fluid filled sac that serves to reduce friction between tendons and bone. Bursae are important structures in both the ankle joint and the subtalar joint, because they ensure that the structures of the joint move smoothly. The major bursa located in the ankle region is the Achilles bursa, retro calcaneal bursa and the bursa of the medial malleolus. Medial malleolar bursitis is characterized by the inflammation or swelling of the bursa of the medial malleolus in the ankle. This bursa is located between the skin and the medial malleolus. [3]

Bursa may inflamed due to various reasons like direct blow, repeated stress injury, inflammatory or infective arthritis etc. which can also cause tendonitis in addition to bursitis. Bursa of the medial malleolus can become swollen as a response to other ankle conditions. [6]

Main symptoms of medial malleolar bursitis are pain and tenderness along the outside of the ankle at the medial malleolus bone, swelling, limitation of ankle movements, pain with physical activities like walking, jumping, running or activities that cause stress on the tendons that are lubricated by the bursa of the medial malleolus.[7]

Common medical management for medial malleolar bursitis followed in modern medicine includes restriction of joint movements that produce pain or stress of the bursa and associated tendons (jumping, running, etc.),the use of ice to reduce inflammation and pain, RICE: (Rest, Ice, Compression, Elevation) should be used to reduce the stress on bursa, NSAIDS (non-steroidal anti-inflammatory drugs), physical therapy, drainage of the fluid in the bursa for severe cases and fluid should be checked for possible infection, antibiotics in the case of infections of the bursa, steroidal injections in nonresponsive cases, surgery is recommended remove the bursa may be needed in extreme cases if the problem becomes chronic.[3]

This case report study evaluates the efficacy of Leech therapy along with Siddha medicine for the management of Medial malleolar bursitis.

II. Materials and Method

- *Attaivaldal* (Leech therapy)

Written consent was obtained from patient and case sheet was filled properly. The necessary investigations including Hemoglobin, CT, BT, Blood sugar, HIV I & II, HBS Ag, and VDRL were carried out before the treatment.

Pretreatment procedure

Vital signs of the patient were noted and allowed to lie in supine position with exposed affected site. Medium sized active Leeches were selected and cleaned well in turmeric water and pure water for 10 minutes consecutively.

Treatment procedure

The affected area cleaned with normal saline and biting site was markedwithmarker. Leeches were allowed to bite the site properly and kept them under a wet gauze piece to avoid external nuisance. Leeches were allowed to suck the blood till the approximated time.

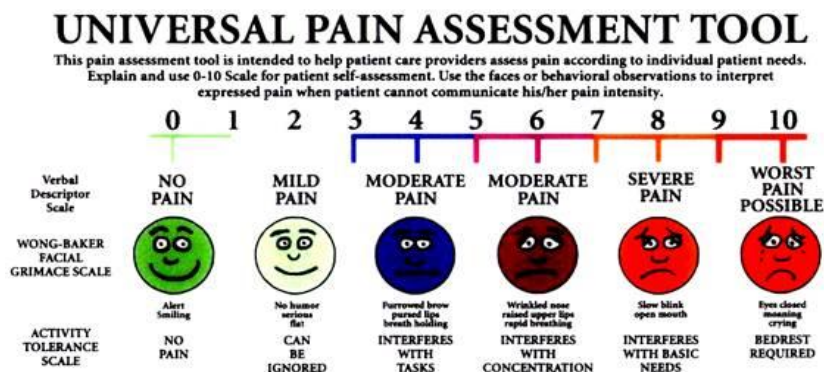
Post treatment procedure

At the end of the treatment procedure leeches were allowed to emit the blood by the application of turmeric powder over the mouth. After the complete expulsion it is kept in turmeric water and pure water for 10 minutes each. After that Leeches were stored in fresh water containers. Like that from the patient side bleeding should not arrest immediately after procedure, wait for 5 to 10 minutes for appropriate result. After hemostasis area is cleaned well and bandaged with aloe pulp dusted with turmeric powder. Finally vitals sign were checked to know the stability of the patient.

- Parameters of assessment

Symptoms were assessed by using universal pain scale, visual analog scale and quality of life is assessed by Foot and ankle disability index (FADI) score. Symptoms were noted in all sittings (before starting the procedure) and reviews. Quality of life was assessed before and after treatment.

1) Pain assessment



2) Assessment of other symptoms

Gradation of swelling of joints

- 0 - Nil, no swelling.
- 1 - Mild, feeling of swelling with heaviness of joints.
- 2 - Moderate, apparent swelling.
- 3 - Severe, huge swelling.

Gradation of tenderness of joints

- 0 - Nil, no tenderness.
- 1 - Mild, elicited on much pressure.
- 2 - Moderate, elicited on moderate pressure.
- 3 - Severe, elicited even on slight touch.

Gradation of restriction of movement

- 0 - Absence of movement restriction.
- 1 - <25% restriction of movement.
- 2 - 25–50% restriction of movement.
- 3 - >50% restriction of movement.

3) FADI for the assessment of the quality of life

The Foot and Ankle Disability Index is a 34-item questionnaire divided into two subscales: the Foot and Ankle Disability Index and the Foot and Ankle Disability Index Sport. The FADI has 26 items, and the FADI Sport has 8. The FADI contains 4 pain related items and 22 activity related items. The FADI Sport contains 8 activity related items. It assesses more difficult tasks that are essential to sport. The FADI Sport is unique in that it is a population-specific subscale designed for athletes.

Each of the 34 items is scored on a 5-point Likert scale from 0 (unable to do) to 4 (no difficulty at all). The 4 pain items of the FADI are scored 0 (none) to 4 (unbearable). The FADI has a total point value of 104 points. The FADI and FADI Sport are scored separately as percentages, with 100% representing no dysfunction. FADI sports is an optional one, we need not to answer in the case of people other than sportsman.

III. Case History

45 year old female report at the Outpatient department of National Institute of Siddha with the complaints of pain swelling and restricted movements over left medial malleolar area since 8 months. Pain aggravated while long time walking and standing. She is a Hypothyroid and taking allopathic medication. On examination she had mild flat foot deformity with obliterated medial arch, tenderness over and around medial malleolus, mild swelling present around the medial malleolus and extend to the inferior aspect. On the basis of clinical examination it was diagnosed as medial malleolar bursitis. [6]

In this case we have aimed to treat it by leech therapy along with internal medicine on the basis of clinical sign and symptoms. For this case 5 sittings of leech therapy were done with 10 days interval along with regular Siddha medicine. 2 Leeches were used for I and II sittings; 1 leech for other sittings. Prognosis of the patient assessed using Universal pain scale, visual analog scale and quality of life by Foot and ankle disability index (FADI).

IV. Observation and Results

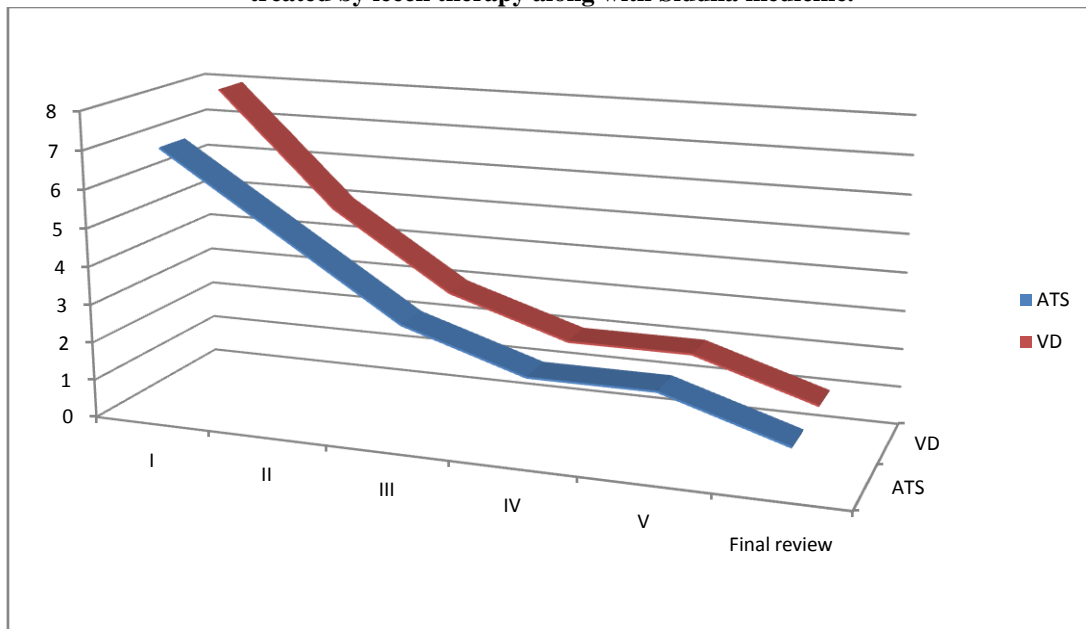
During the whole study period it has been observed that pain and swelling become decreased after the first sitting of leech therapy and after the last follow-ups there is significant decrease in signs and symptoms including pain, swelling, tenderness and difficulty in walking. Quality of life the patient is assessed by FADI and there was marked increase in the score after the completion of leech therapy. The scar of the leech bite is

also observed on the bite site but it becomes clear in 2-3 weeks after the completion of last sitting of leech therapy.

Table 1: Universal pain scale, visual analog scale score in the patientof medial malleolar bursitis treated by leech therapy along with Siddha medicine.

No. of sittings	Activity tolerance scale	Verbal descriptor scale
I	7	8
II	5	5
III	3	3
IV	2	2
V	2	2
FINAL REVIEW	1	1

Chart 1:ATS-Activity tolerance scaleVD-Verbal descriptor in the patientof medial malleolar bursitis treated by leech therapy along with Siddha medicine.



ATS-Activity tolerance scaleVD-Verbal descriptor

Table 2: Assessment of symptoms in the patientofmedial malleolar bursitistreated by leech therapy along with Siddha medicine.

No.of sittings	Swelling	Tenderness	Movement restriction
I	2	3	3
II	1	2	3
III	1	2	2
IV	1	1	2
V	0	1	1
FINAL REVIEW	0	1	0

Chart 2:Assessment of symptoms in the patient of medial malleolar bursitistreated by leech therapy along with Siddha medicine.

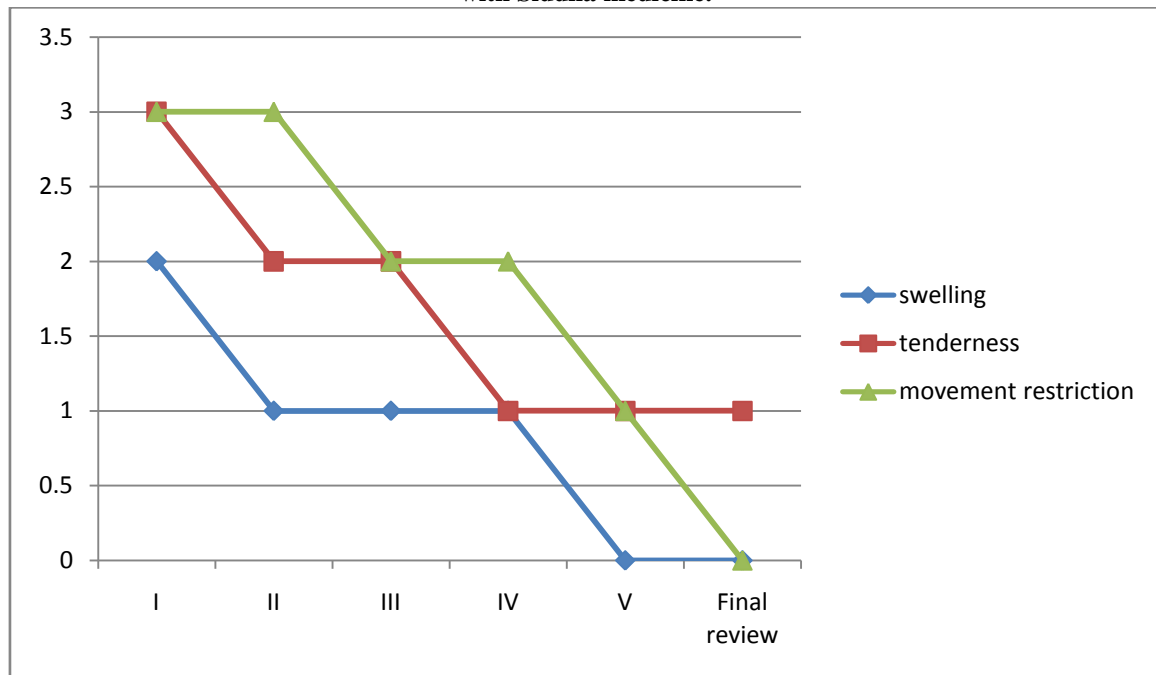


Table 3:Foot and ankle disability index (FADI) score in the patient ofmedial malleolarbursitistreated by leech therapy along with Siddha medicine.

	BEFORE TREATMENT	AFTER TREATMENT
FADI	40.4	85.6

Chart 3:Foot and ankle disability index (FADI) score in the patient of medial malleolar bursitis treated by leech therapy along with Siddha medicine.

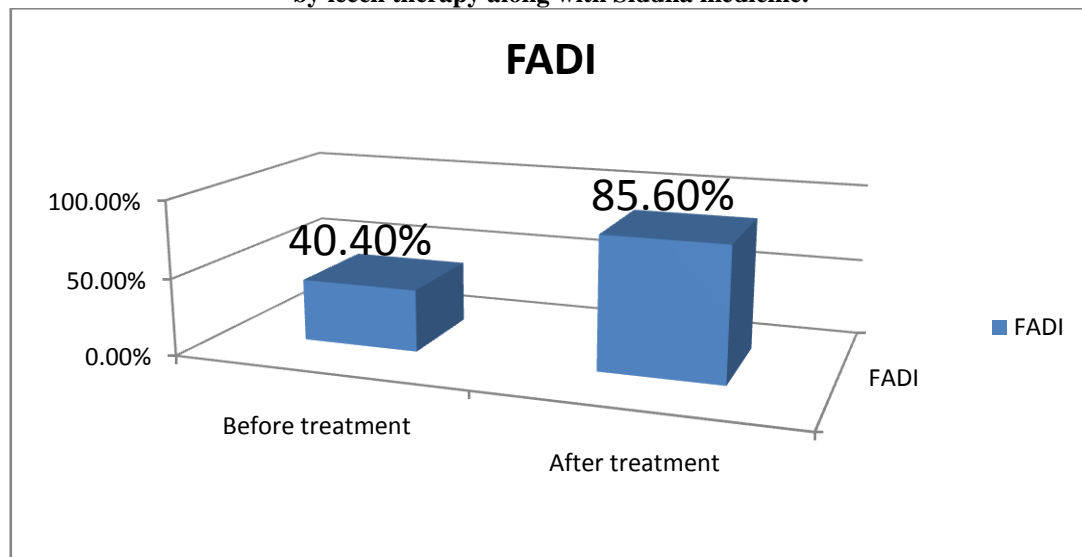

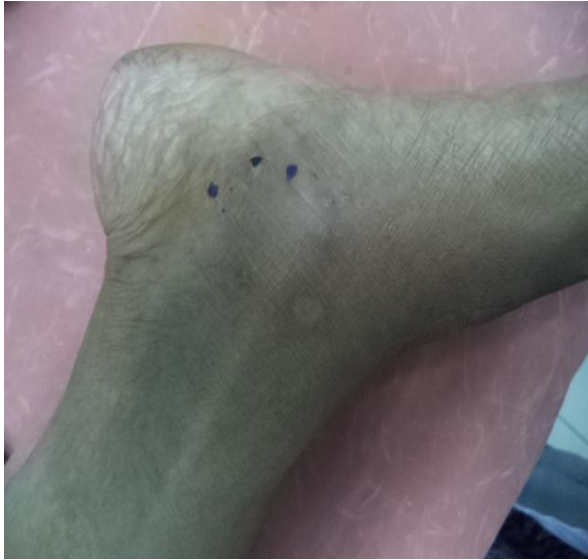


Figure-1

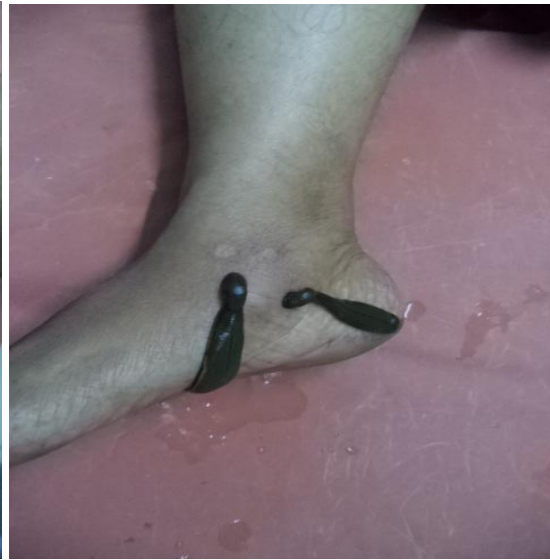

Figure -2

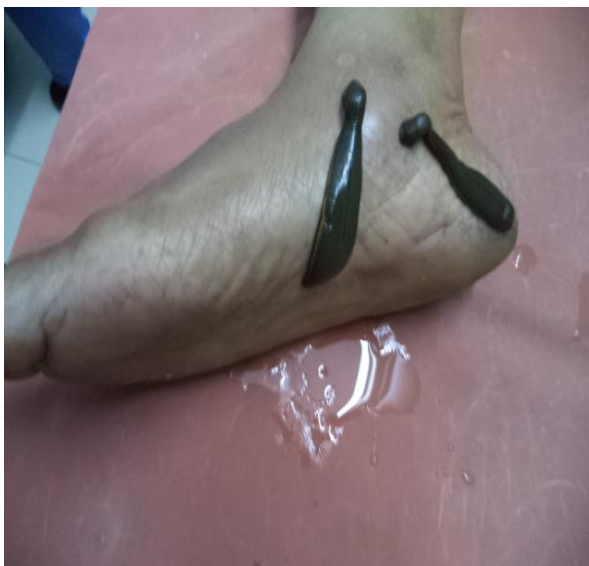

Figure-3

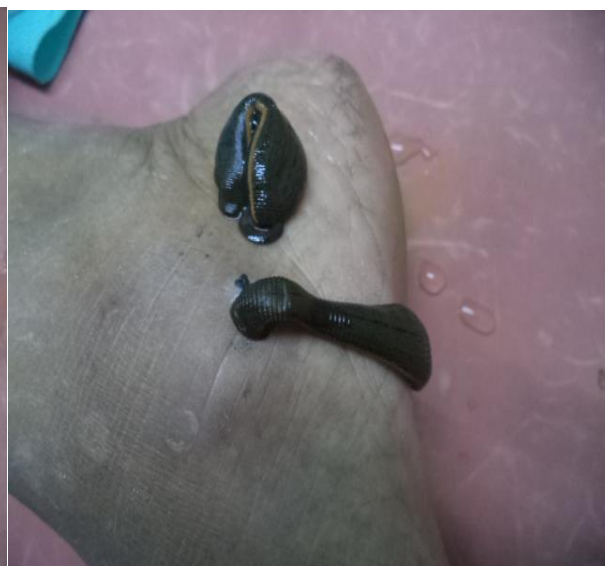

Figure-4

Figure 1: Shows mark in and around medial malleolus regionfor the application of leeches. Figure 2, 3&4 Shows leeches were sucking the blood in and around medial malleolus region.

Initially according to universal pain scale patient had severe pain which interfered with basic needs, after 5 sittings of Leech therapy it came to mild pain which can be ignored

V. Discussion

Medial and lateral Malleolar bursitis of the ankle can results from pressure from various causes such as boots, skates, sports activities and certain foot and gait abnormalities such as an abnormal toe joint, flat feet, bunions or hammer toes, can place additional stress on the bursa and lead to bursitis [8]. In this case there is no abnormal pressure to medial malleolar bursa was identified but the patient had flat foot.

The bursa is a closed sac made of synovial membrane and containing synovial fluid. It is usually located between bone and tendons, between bone and skin and between ligament and tendon so that reduces the shear forces caused by movements. The premalleolar bursa is located lateral and medial malleolar bone surface and subcutaneous tissue. The bursa is not palpable it become painful when a bursitis occur. There are two type of inflammation of bursa: the nonspecific bursitis mainly due to traumatic injuries and infective bursitis. The infective bursitis is caused by indirect or direct infection. In this case study medial malleolar bursitis is happened from unknown cause, and is also comes under nonspecific bursitis.

The condition is characterized by pain, swelling, and tenderness at the level of medial malleolus, limited ankle movements and also affects the day to day life activities. In modern science the cases were treated

in two ways, surgical and non-surgical. Thenon-surgical treatment includes use of non-steroidal anti-inflammatory drugs, aspiration of synovial fluid and corticosteroid injections, represents the first therapeutic approach. The surgical treatment is indicated in the presence of a relapsing bursitis or aseptic bursitis. Both surgical and non-surgical approach may cause some side effects. In Siddha system of medicine the diseases were treated by using internal medicine,external medicine and external therapy. This case was treated by using internal Siddha medicine and external therapy (Leech therapy).

Leech therapy is one of the Para surgicalprocedures indicated in siddha system of medicine to treat various inflammatoryconditions like bursitis. Leech therapy is painless, minimal invasive, cost effective and simple way of treatment in Bursitis without producing any serious adverse effect. Salivary secretion of Leech contains more than 100 biological compounds such as Hirudin, Calin, Destabilase, Hyaluronidase, Eglins, Acetylcholine, Anaesthetic substances and Histamine like substances which acts on collagen mediated platelets aggregation, and has action like Anti-inflammatory, Vasodilation etc. [9]. This may cause the effects of leech therapy in the treatment of bursitis.

The leech application increases the blood circulation of affected area and helps to reduce the inflammation and infection. The principle of leech therapy in Bursitis is removal of toxins, *senneerthathu* and vitiated *pithathodam* from body through blood. Bursitis is caused by vitiation of *pitham* gradually it join with *vatham* and *kabam* consecutively produce severe form of diseases. The leech has *thatpaveeriam* (cold potency) because they live in water. So the leech therapy mainly used to treat the diseases caused by vitiated *pithathodam*. Leech has properties to differentiation of blood and it sucks only impure blood [10].

VI. Conclusion

In modern science Bursitis cases were treated in surgical and non-surgical method. The non-surgical treatment includes use of non-steroidal anti-inflammatory drugs, aspiration of synovial fluid and corticosteroid injections. Both surgical and non-surgical approach may cause some side effects. In this study medial malleolarbursitis casewas treated by leech therapy along with Siddha medicine. Leech therapy is painless, cost effective and simple way of treatment for Bursitis without any adverse effect. From this study we can conclude that Attaivald (Leech therapy) is an effective treatment for the management of Medial malleolar bursitis. Further with the help of Leech therapy we can improve the quality of life of the patients.

References

- [1]. Dr.K.S.Uthamarayan,SiddharAruvai Maruthuvam,6th edition-2013
- [2]. Eldor A, Orevi M, Rigbi M. The role of the leech in medical therapeutics. Institute of Hematology, Tel-Aviv Sourasky Medical Center, Israel.Blood review Volume 10, Issue 4, December 1996, Pages 201-209
- [3]. G.S.Kulkarni,Textbook of Orthopedics and trauma,Jaypee,1st edition,1999
- [4]. Thyagarajan.R, GunapadamThathuJeevavaguppu, 3rdEdition, Chennai, Department of Indian Medicine and Homoeopathy, 1981.
- [5]. Knobloch K, Gohritz A, Busch K, Spies M, Vogt PM. Hirudomedicinalis-leech applications in plastic and reconstructive microsurgery--a literature review. Plastische, Hand- und Wiederherstellungschirurgie, MedizinischeHochschule Hannover, Carl-Neuberg-Strasse 1, 30625 Hannover. kknobi@yahoo.com, HandchirMikrochirplast Chir2007;39(2): 103-107DOI: 10.1055/s-2007-965138
- [6]. ParchiPD, Ciapini G, Poggetti A, Addevico F, Mannucci C, Castellini I, Chiellini F and Lisanti M Surgical Treatment for a Relapsing Malleolar Bursitis in a Professional Figure Skating: Case Report , Orthopedic & Muscular System: Current Research, Febrary I 2016
- [7]. Masashi Naito, Takumi Matsumoto, Song Ho Chang, Masachika Ikegami, Jun Hirose, and Sakae Tanaka, Case Report-Recalcitrant Lateral Premalleolar Bursitis of the AnkleAssociated with Lateral Ankle Instability, Hindawi, Case Reports in OrthopedicsVolume 2017, Article ID 4854812, 4 pages, Published 3 August 2017.
- [8]. Jin Su Kim,Woo Jong Kim, Ki Won Young, Kyu Hwan Bae, Han Hoon Kim, and Hong Seop Lee, Candy Closure Technique for Chronic Open Infective Lateral Malleolus Bursitis, HindawiBioMed Research International Volume 2019, Article ID 5490139, 5 pages, Published 17 March 2019
- [9]. AadityaBhavanbhai Shah,PoonamMohod, INDRALUPTA (ALOPECIA AREATA): A CASE SUCCESSFULLY TREATED WITH JALUKAVCHARANA (LEECH THERAPY), *International Journal of Ayurveda and Pharma Research*, 7(1). 2019-04-03
- [10]. Periyasami D., Aarthy K., Monika M., &Muthukumar N. (2018).Attaivald (leech therapy) in Siddha System of Medicine and their current concept in therapeutic application - a review, *International Journal of Ayurveda and Pharma Research*, 6(5)

D Periyasami. "Effectiveness of Attaivald (Leech Therapy) with Siddha Medicine Forthe Management of Medial Malleolar Bursitis-A Case Report Study." IOSR Journal of Dental and Medical Sciences (IOSR-JDMS), vol. 18, no. 12, 2019, pp 73-79.