

Spinal Cord Compression Due To Extra-medullary Hematopoiesis: A Case Report

Dr. Siladitya Das¹, Dr. Badal Kumar Sahu²

¹(Department of General Medicine, Burdwan Medical College/West Bengal University Of Health Sciences, India)

²(Department Of General Medicine, Burdwan Medical College/West Bengal University Of Health Sciences, India)

Corresponding Author: Dr. Siladitya Das

Abstract:

Background: Extra-medullary hematopoiesis refers to the conditions associated with a variety of chronic diseases, where, due to excess demand for blood components causes expansion of hematopoietic tissue outside the bone marrow(1)

Besides common location of spleen, liver and lymph nodes, it can occur in the dura mater of the spinal cord, and may encroach upon the epidural space.

We report a case of spinal cord compression due to spinal epidural extra-medullary hematopoiesis in a sixteen year old male patient.

Case History: A sixteen year old male patient presented to us with complaints of bilateral lower limb weakness for two months. Weakness was gradual in onset, progressive in nature, ascending from feet towards the trunk. It was associated with sensory loss upto seventh thoracic vertebra level. Patient was a known case of Hemoglobin E – Beta Thalassemia

MRI of dorsolumbar spine with contrast suggested extra-medullary hematopoiesis. NCV EMG was normal.

Patient was managed conservatively and was given blood transfusions which improved the patient to some extent.

Conclusion: Extra-medullary-hematopoiesis should always be a differential diagnosis in patients with ineffective erythropoiesis presenting with spinal cord compression. Treatment in such cases blood transfusions, surgical management, radiotherapy, hydroxy-urea, or a combination of these approaches.

Date of Submission: 02-12-2019

Date of Acceptance: 18-12-2019

I. Introduction

Extramedullary hematopoiesis can occur most often in sites related to fetal development such as spleen, liver, lymph nodes. It can also occasionally occur in organs like pleura, lungs, gastro-intestinal tract, heart, skin, dura mater of the spinal cord and the brain, kidney and adrenal glands. (2,3)

It is commonly found in case of primary and secondary myelofibrosis. It is extremely rare in other hematological diseases like inherited anaemias especially thalassemia and chronic myeloproliferative disorders including myeloid metaplasia, polycythemia vera, leukemia and Hodgkin's disease.(4)

Involvement of the spinal canal can be due to involvement of the epidural space or para-spinal muscles by extra-medullary hematopoiesis. The usual location is the thoracic spine due to currently unidentified mechanisms but a wide variety of theories have been proposed.

Unlike thalassemia major patients, who require regular blood transfusions, Hemoglobin E Beta Thalassemia patients do not receive regular transfusions. They have chronic anaemia and ineffective erythropoiesis, which can cause clinical symptoms.

II. Case report

A sixteen years old male known case of Hemoglobin E Beta Thalassemia, presented to our out patient department with chief complaint of weakness of both his lower legs for two months. Initially he started suffering from slipping of his chappals, which then progressed upwards. He started suffering from stiffness of his right lower limb followed by his left lower limb, which gradually progressed upwards to involve his thigh muscles then the lower part of his trunk. Then afterwards he started suffering from difficulty in getting up from sitting or lying down position. He also complained of losing control over his bowel and bladder few days prior to attending our out patient department.

Clinical examination revealed anaemia, typical hemolytic facies, stunted growth. Cranial nerves examination was normal. Motor system examination revealed increase in tone in bilateral lower limbs, power in the abductors, adductors, extensors, flexors of the hip, of knee, of ankle were 1/5 as per Medical Research Council scoring. Ankle clonus was present bilaterally. Upper limbs had normal tone and power of 4/5.

Sensory examination revealed upper limbs were within normal limit. While there was diminished pain, touch, temperature, position, vibration sense in the both the lower limbs and sensory level at T7 dermatomal level.

All superficial and deep reflexes were normal in the upper limbs while all superficial reflexes were lost below T7 level and plantar was bilaterally extensor and both knee and ankle reflexes bilaterally were exaggerated.

Lab examination revealed hemoglobin- 6.3 g % and WBC count- 9300 / cubic centimeters

MRI dorso-lumbar spine revealed extensive para-vertebral soft tissue thickening with epidural encroachment at D-L region with enhancement on contrast study. MRI of dorso lumbar spine with contrast suggests extra medullary haemopoiesis. NCV-EMG of both lower limbs was normal. The patient was given blood transfusion and conservative management

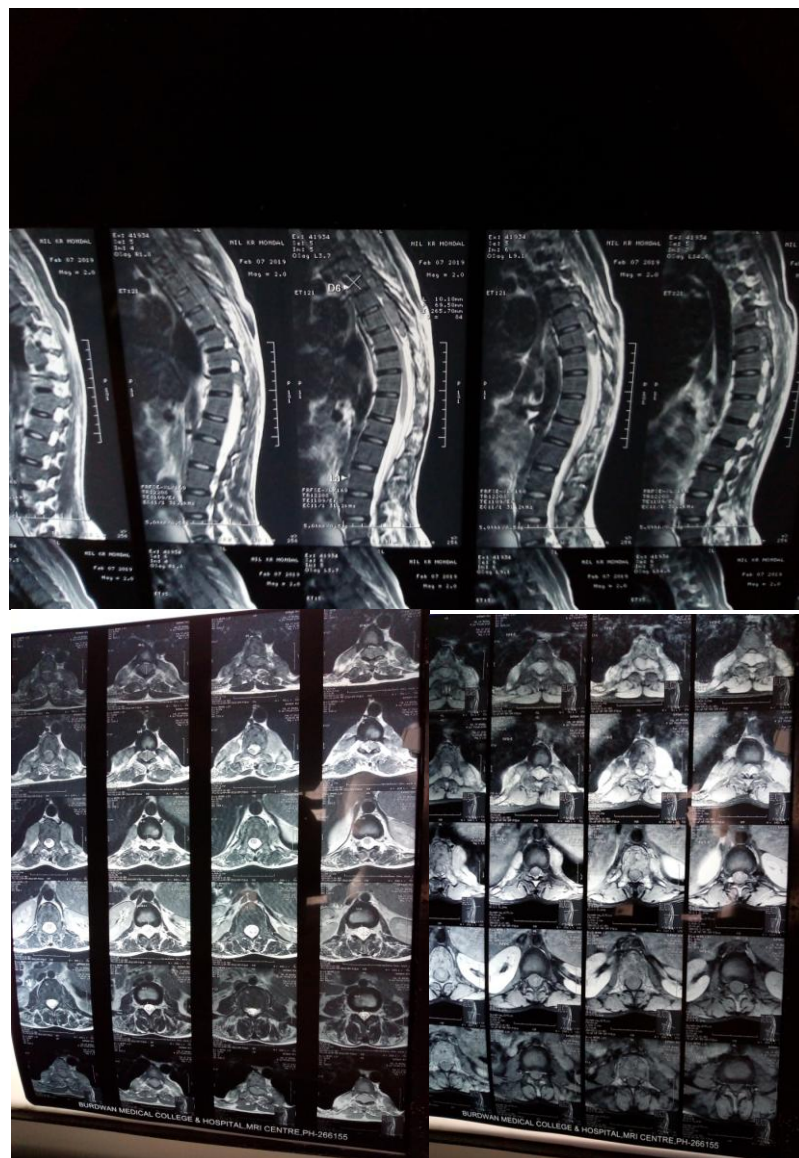


Figure 1: Sagittal section (upper panel) and axial section (lower panel) showing paravertebral soft tissue thickening with epidural encroachments at DL region with enhancement on contrast study

III. Discussion

Extra-medullary hematopoiesis (EMH) tends to occur in sites that were normally engaged in active hematopoiesis in fetal life. The dura mater of brain and spinal cord were one of those sites, and therefore it is likely that EMH of the epidural space develops from these primitive rests, i.e. by re-activation of retained hematopoietic capacity in fetal life (3,5).

It has been seen that there is a notable predilection for spinal epidural EMH to occur in the mid to lower thoracic region and several hypotheses have been proposed to explain this localization (6). A vascular territory proposition has also been introduced accordingly, relating the thoracic predilection to development of EMH from branches of the intercostal veins (7), or arterial embolic phenomena (8). Another proposition is extension from expanded bone marrow cavities of vertebrae, proximal ends of ribs and costo chondral junctions.

EMH, histologically, is composed of all hematopoietic elements, i.e. myeloid, erythroid and megakaryocytic components.

Thalassemia is an inherited intracorpuscular cause of hemolytic anaemia in human beings. It occurs due to genetic defects leading to defective synthesis of globin chains and the type of thalassemia is classified depending upon the globin chain missing. They can be Beta thalassemia major, Beta thalassemia intermedia, Beta thalassemia minor (when the beta chain synthesis is impaired). Similarly depending upon mutations in amino acid sequences in the globin chains hemoglobin variants are produced. Hemoglobin E occurs due to replacement of glutamate in 26th position of beta globin gene by lysine.

Given the appropriate clinical setting including proper history, general and neurological examination, findings on conventional radiography and CT scanning are usually sufficient to diagnose spinal cord compression due to EMH. But due to its multiplanar capability, MRI contributes further to the diagnosis by accurately delineating the extent of the lesion and thereby helps to localize the optimal field of radiation therapy or surgery, if they are contemplated.

In both T1- and T2- weighted MRI, active hematopoietic masses show higher intensity than the adjacent hemopoietic marrow within vertebral bodies. Old inactive lesions may show either high or low signal intensity in both T1- and T2-weighted MR images due to fatty infiltration or iron deposition respectively.

Active EMH are vascular lesions and therefore show post intra-venous gadolinium contrast enhancement, except for early lesions that show often minimal enhancement. Old inactive lesions show decreased contrast enhancement. MRI may show massive iron deposition in patients treated with blood transfusions. Fatty degeneration is most probably related to oxidative stress in non-transfused patients leading to lipid peroxidation of cell membranes and production of oxygen-free radicals. Fatty replacement and fibrosis also occur after radiation therapy (9,10,11).

Because of its rarity, very few evidence based guidelines for the treatment of spinal or paraspinal pseudotumors caused by EMH exist.

Management options include corticosteroids, blood transfusion, hydroxyurea, radiotherapy, surgical decompression, or a combination of these modalities. Therapy usually depends on the severity of symptoms, size of the mass, the patient's clinical condition, judgement of the treating physician and previous treatment (6,12).

Correction of the anaemia leads to decreased need for extra-medullary hematopoeisis and therefore shrinkage of the masses of hematopoeisis. This leads to decompression of the spinal cord and neurological improvement. But blood transfusion has its own side effects. It poses risk of infections, red cell alloimmunisation and iron overload.

A combination of blood transfusion and radio therapy can be useful as radiotherapy provides a quick way to cause neurological improvement. But side effects of radiotherapy include myelo-suppression, radiation induced tissue edema, increased infectious risk.

Hydroxyurea, a ribonucleotide reductase enzyme inhibitor, acts by decreasing globin chain synthesis, increasing fetal hemoglobin and by cyto-reduction by decreasing ineffective erythropoeisis.(13,14)

Laminectomy is another option for patients where the methods described previously cannot be done or are ineffective. It provides immediate relief of compression and therefore causes neurological improvement. But it also has side effects. Side effects include bleeding, risk of spine instability, kyphosis and also deterioration of the condition as the masses that were maintaining hemoglobin levels before removal cannot maintain their function.

It can be combined with post operation radiotherapy for better results.

IV. Conclusion

Extra-medullary hematopoiesis is an essential modality to be kept in mind while considering differential diagnosis of cord compression with chronic disease or anaemia or other hematological disorders. Early diagnosis remains the key to proper management of the patient and thereby prevention of complications and irreversible neurological sequelae. Differential diagnosis includes metastatic malignant disease, lymphoma, abscess, multiple myeloma, vascular anomalies. Currently MRI of spine is considered the diagnostic modality of choice for evaluation of patients with cord compression due to extra-medullary hematopoiesis.

References

- [1]. Amirjamshidi A, Abbassioun K, Ketabchi SE. Spinal extradural hematopoiesis in adolescents with thalassemia. Report of two cases and a review of the literature. *Childs Nerv Syst.* 1991; 7: 223-225.
- [2]. Aster J, Kumar V. White cells, lymph nodes, spleen, and thymus. *Pathologic basis of disease.* 6th ed. Philadelphia: Saunders; 1997; 644-695.
- [3]. Ashkzaran H, Delanote J, Casselman J, et al. Epidural extramedullary hematopoiesis. *JBR-BTR.* 2008; 91: 82-83.
- [4]. Piccaluga PP, Finelli C, Vigna E, et al. Paraplegia due to a paravertebral extramedullary haemopoiesis in a patient with polycythaemia vera. *J Clin Pathol.* 2007; 60 (5): 581-582.
- [5]. Haidar R, Mhaidli H, Taher AT. Paraspinal extramedullary hematopoiesis in patients with thalassemia intermedia. *Eur Spine J.* 2010; 19: 871-878.
- [6]. Niggemann P, Krings T, Hans F, et al. Fifteen-year follow-up of a patient with beta thalassaemia and extramedullary haematopoietic tissue compressing the spinal cord. *Neuroradiology.* 2005; 47: 263-266.
- [7]. Cone SM. Bone marrow occurring in intercostal veins. *JAMA.* 1925; 84: 1732-1733.
- [8]. Cardia E, Toscano S, La Rosa G, et al. Spinal cord compression in homozygous beta thalassemia intermedia. *Pediatr Neurosurg.* 1994; 20: 186-189.
- [9]. Pantongrag-Brown L, Suwanwela N. Case report: chronic spinal cord compression from extramedullary haematopoiesis in thalassaemia - MRI findings. *Clinical Radiology.* 1992; 46, 281-283.
- [10]. Tsitouridis J, Stamos S, Hassapoulou E, et al. Extramedullary paraspinal hematopoiesis in thalassemia: CT and MRI evaluation. *Eur J Radiol.* 1999; 30: 33-38.
- [11]. Lawson J, Ablow R, Pearson H. The ribs in thalassemia I the relationship to therapy. *Radiology.* 1981; 140: 663-672.
- [12]. Moncef B, Hafedh J. Management of spinal cord compression caused by extramedullary hematopoiesis in beta-thalassemia. *Inter Med.* 2008; 47: 1125-1128.
- [13]. Cianciulli P, di Toritto TC, Sorrentino F. Hydroxyurea therapy in paraparesis and cauda equina syndrome due to extramedullary haematopoiesis in thalassaemia: improvement of clinical and haematological parameters. *Eur J Haematol.* 2000; 64: 426-429.
- [14]. Cario H, Wegener M, Debatin KM, et al. Treatment with hydroxyurea in thalassemia intermedia with paravertebral pseudotumors of extramedullary hematopoiesis. *Ann Hematol.* 2002; 81: 478-482.

Dr. Siladitya Das. "Spinal Cord Compression Due To Extra-medullary Hematopoiesis : A Case Report." *IOSR Journal of Dental and Medical Sciences (IOSR-JDMS)*, vol. 18, no. 12, 2019, pp 19-22.