

Mucoepidermoid Carcinoma of the Palatine Tonsil: A Rare Case Report

Apurva Sharma, Corresponding Author Kalpana Rajiv Kumar, Swapnil Gosavi.

Department of otorhinolaryngology, MGM Hospital, Navi Mumbai

Corresponding Author: Apurva Sharma

Abstract: Mucoepidermoid carcinoma is the most common malignant salivary gland neoplasm. It is seen in both, adults and children and shows a slight female predilection. Tumors of minor salivary gland may arise, anywhere, in the oral cavity. However, malignant salivary gland tumor is uncommon in palatine tonsil and only few cases of mucoepidermoid carcinoma (MEC) in tonsil have been reported. Histologically it comprises of a mixture of cell types including mucous, epidermoid, and intermediate cells that can be arranged in solid nests or cystic structures.

The present paper is aimed to describe an unusual case of MEC arising from palatine tonsil.

Date of Submission: 23-11-2019

Date of Acceptance: 07-12-2019

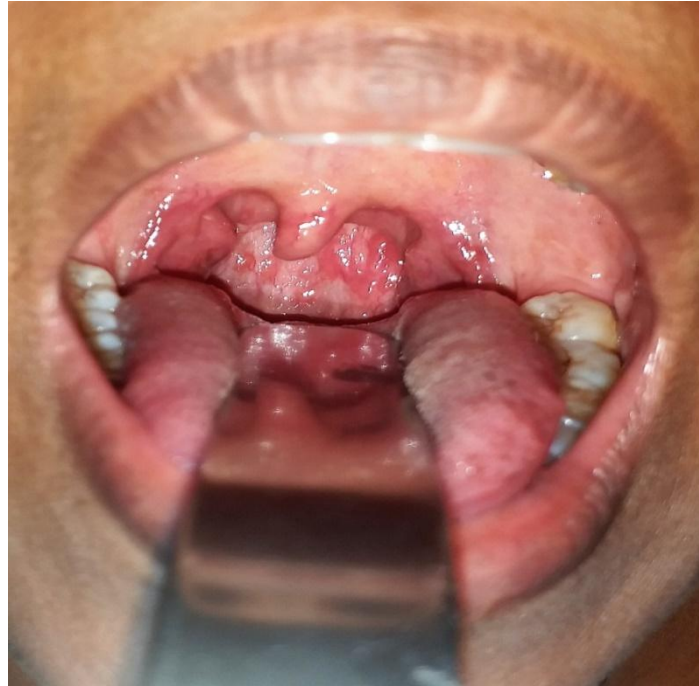I. Introduction

Mucoepidermoid carcinoma is the most common malignant salivary gland neoplasm (12-29% of all salivary gland malignancies). However, malignant salivary gland tumour is uncommon in palatine tonsil and only few cases of mucoepidermoid carcinoma have been described in the medical literature. Many different malignant neoplasms may arise from the palatine tonsils, with the most common histological type being the squamous cell carcinoma which accounts for up to 85% of all cases⁽¹⁻³⁾. Malignant lymphoproliferative diseases are the second most frequent malignancy of the palatine tonsil, with the diffuse large B-cell lymphoma (DLBCL) comprising approximately 30% of all lymphomas⁽⁴⁾.

MEC is the second most common malignant minor salivary gland neoplasm. Minor salivary gland tumours exhibit diverse histopathological features as well as varied clinical behaviour⁽⁵⁾. It may be derived from any of the minor salivary glands distributed throughout the oral cavity⁽⁶⁾. Interestingly despite the presence of minor salivary glands in the palatine tonsils, development of malignant salivary gland tumor is unusual. High grade tumours are highly aggressive and regional lymph node spread is common. The low grade variant usually demonstrates a favourable outcome but it is important to note that metastasis may also be present⁽⁷⁾. Distant metastasis to the lungs, brain, ovary and peritoneum have been reported⁽⁸⁾. Histologically the tumours are composed of mucous, basaloid, intermediate and epidermoid cells. The present paper is therefore, aimed to report a case of MEC arising in the palatine tonsil.

II. Case Report

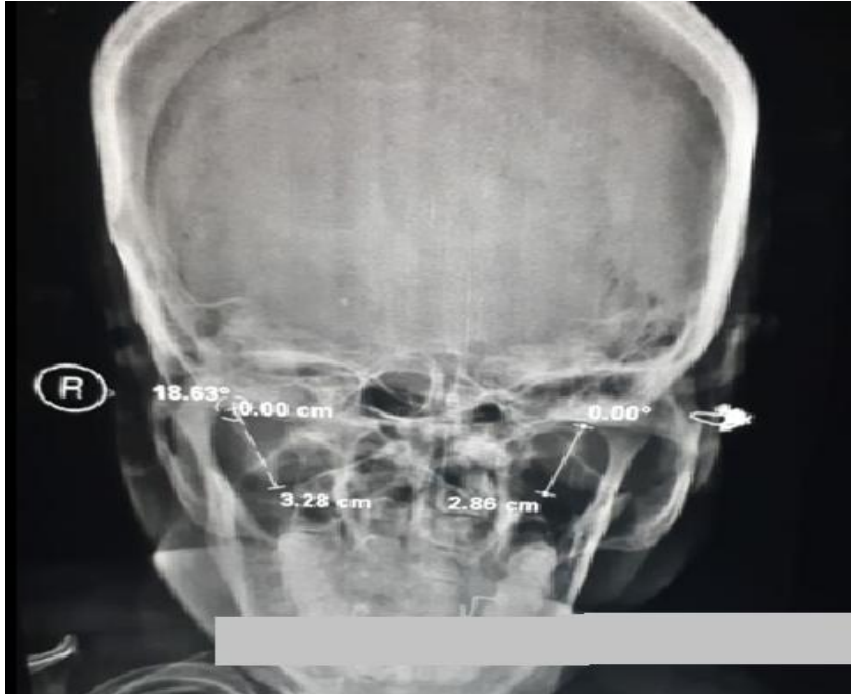
A 47 years old female presented to ENT OPD with unilateral throat pain mainly on the right side since 5-6 months. It was insidious in onset, progressive and radiating to the right ear. Pain aggravated on consumption of cold food and at night time. She also had history of halitosis. Her past medical, dental, social and family history was unremarkable. On examination oral cavity was normal, oropharynx anterior pillar flushed, bilateral grade II tonsillar hypertrophy. On digital examination of right tonsil there was pinpoint tenderness over superior pole of tonsil, left tonsil non tender.



(a)

Figure (a) Grade-II tonsillar hypertrophy, tonsillar mucosa normal, no mass visualized.

Indirect laryngoscopy was normal, No neck node palpable. X-ray Skulltowne's view suggestive of right sided styloid process elongation. On basis of clinical history, examination and investigation provisional diagnosis was made of right sided elongation of styloid process (eagle's syndrome).



(b)

Figure : (b) X-ray PNS towne's view suggestive of right sided styloid process elongation (normal styloid process length-2.5cm to 3.0cm)

Patient was planned for tonsillectomy with styloid process excision. Intraoperatively right styloid process was found not to be elongated. Due to suspicion of diagnosis tonsils were sent for histopathological examination.

Histopathologically right tonsil studied shows normal tonsillar tissue with feature of chronic tonsillitis, also seen a small focus of cells consisting of clear cells and epidermal cells showing glandular pattern with mild-moderate pleomorphism, some fragments separately show feature of mucoepidermoid carcinoma, and clear cell margins, the tumor is solid and tumor cells are arranged as nests. Mitosis is not identified, necrosis is not seen, lymphovascular emboli is not seen, perineural invasion not seen. Alcian blue was positive of extracellular mucin. On the basis of histopathological report diagnosis was made of mucoepidermoid carcinoma of palatine tonsil (intermediate grade).

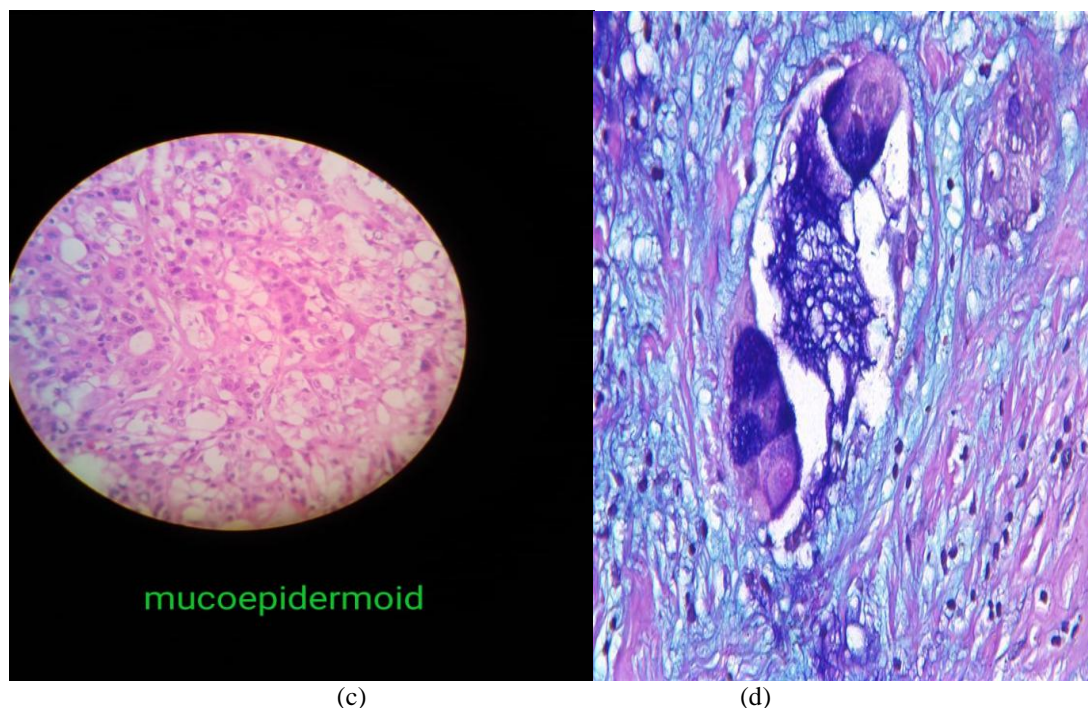


FIGURE: (c) H&E revealing small focus of cells showing bimodal population of cells consisting of clear cells and epidermal cells showing glandular pattern with mild-moderate pleomorphism, (d) Alcian blue positive of extracellular mucin.

Post-operative patient was advised CT scan of neck, which showed single nonspecific neck node. She underwent postoperative radiotherapy.

III. Discussion

Mucoepidermoid carcinoma (MEC) is slow growing invasive malignant neoplasm. It occurs in any age group from first to ninth decades, with highest incidence in fourth decade with females affected more than male in a 3:1 ratio. MEC is one of the most common malignancies of the minor salivary glands⁽⁸⁻¹⁰⁾ and is currently described as a malignant glandular epithelial neoplasm characterised by mucous intermediate and epidermoid cells with columnar, clear cell and oncocytoid features⁽¹¹⁾. It is classified as low grade, intermediate grade, and high grade, according to the percentage of cystic components, quantity of the three types of tumour cells seen and histologic features such as necrosis, mitosis, anaplasia⁽¹²⁾. MEC of minor salivary glands most frequently occurs at the palate and buccal mucosa and followed by tongue, gingiva, floor of the mouth and nasal cavity⁽¹³⁾. Approximately 70% of all cases of MEC are compromised by low grade and intermediate grade. Thus routine diagnosis of MEC is generally based on conventional H&E staining looking to identify the presence of cystic structure and mucous cell. High grade MEC can resemble squamous cell carcinoma and necessitates careful search for mucinous cells for correct diagnosis.

The standard approach for the treatment of MEC is total excision of tumor. However, minor salivary gland carcinomas of the oropharynx are often challenging to manage. Tonsillectomy with ipsilateral neck dissection has been used as a treatment option. Some studies have advised the use of radiotherapy for both high grade MEC and patient with unclear margins. On the other hand regarding chemotherapy in MEC is generally adopted in palliative management of inoperable tumours. Variant of MEC includes clear cell MEC, oncocytic

MEC, sclerosing variant and sclerosing MEC with eosinophilia. Prognosis is good for low and intermediate grade tumours and cure is possible in these grades. Unfavourable prognostic features includes lymph nodespread, perineural and vascular invasion, aneuploidy, mitotic count >2/10hpf, expression of MUC1 and lymph nodemetastasis.

IV. Conclusion

Although mucoepidermoid carcinoma is the most common malignant salivary gland tumour, it is a very rare occurrence within the substance of the palatine tonsil. MEC is to be considered, in differential diagnosis of oropharyngeal malignancies. It becomes necessary to diagnose such rare tumours, since early diagnosis and appropriate management are the determining factors in the prognosis of these malignancies.

References

- [1]. M. E. Guay and P. Lavertu, "Tonsillar carcinoma," *European Archives of Oto-Rhino-Laryngology*, vol. 252, no. 5, pp. 259–264, 1995.
- [2]. G. S. Mizono, R. F. Diaz, K. K. Fu, and R. Boles, "Carcinoma of the tonsillar region," *Laryngoscope*, vol. 96, no. 3, pp. 240–244, 1986.
- [3]. S. M. Golas, "Trends in palatine tonsillar cancer incidence and mortality rates in the United States," *Community Dentistry and Oral Epidemiology*, vol. 35, no. 2, pp. 98–108, 2007.
- [4]. A. Lopez-Guillermo, L. Colomo, M. Jimenez et al., "Diffuse large B-cell lymphoma: clinical and biological characterization and outcome according to the nodal or extranodal primary origin," *Journal of Clinical Oncology*, vol. 23, no. 12, pp. 2797–2804, 2005.
- [5]. A. Dalgic, O. Karakoc, U. Aydin et al., "Minor salivary gland neoplasms," *Journal of Craniofacial Surgery*, vol. 25, no. 3, pp. e289–e291, 2014.
- [6]. Balogh and L. Pantanowitz, "Mouth, nose, and paranasal sinuses," in *Histology for Pathologists*, S. E. Mills, Ed., pp. 403–430, Lippincott Williams & Wilkins, Philadelphia, Pa, USA, 2007.
- [7]. Buyukkurt S, Altintas A, Gumurdulu D, et al. Mucoepidermoid carcinoma of the parotid gland with ovarian and peritoneal metastasis. *J Obstet Gynaecol Res* 2008;34:271-3.
- [8]. F. A. de Oliveira, E. C. B. Duarte, C. T. Taveira et al., "Salivary gland tumor: a review of 599 cases in a Brazilian population," *Head and Neck Pathology*, vol. 3, no. 4, pp. 271–275, 2009.
- [9]. X.-D. Wang, L.-J. Meng, T.-T. Hou, and S.-H. Huang, "Tumours of the salivary glands in northeastern China: a retrospective study of 2508 patients," *British Journal of Oral and Maxillofacial Surgery*, vol. 53, no. 2, pp. 132–137, 2015.
- [10]. R. H. Spiro, "Management of malignant tumors of the salivary glands," *Oncology*, vol. 12, no. 5, pp. 671–680, 1998.
- [11]. R. K. Goode and A. K. El-Naggar, "Mucoepidermoid carcinoma," in *World Health Organization Classification of Tumours. Pathology and Genetics of Head and Neck Tumours*, L. Barnes, J. W. Eveson, P. Reichart, and D. Sidransky, Eds., pp. 219–220, IARC Press, Lyon, France, 2005.
- [12]. A. Coca-Pelaz, J. P. Rodrigo, A. Triantafyllou et al., "Salivary mucoepidermoid carcinoma revisited," *European Archives of Oto-Rhino-Laryngology*, vol. 272, no. 4, pp. 799–819, 2015.
- [13]. M. A. Luna, "Salivary mucoepidermoid carcinoma: revisited," *Advances in Anatomic Pathology*, vol. 13, no. 6, pp. 293–30, 2006.
- [14]. S. J. Jarvis, V. Giangrande, and P. A. Brennan, "Mucoepidermoid carcinoma of the tonsil: a very rare presentation," *Acta Otorhinolaryngologica*.

Apurva Sharma. "Mucoepidermoid Carcinoma of the Palatine Tonsil: Arare Case Report." *IOSR Journal of Dental and Medical Sciences (IOSR-JDMS)*, vol. 18, no. 12, 2019, pp 53-56.