

## A family case of X-linked Alport syndrome patients with a novel mutation

Benkova-Petrova M., Petrov A., Staykova S.

Medical University „Prof. Dr. Paraskev Stoyanov“, Varna, Bulgaria  
University Hospital “St. Marina”, Varna, Bulgaria

---

**Abstract:** Alport syndrome is a genetic disorder characterized by kidney disease, hearing loss, and eye abnormalities. Most affected individuals experience progressive loss of kidney function, usually resulting in an end-stage chronic kidney disease. In 80% of the cases Alport syndrome is inherited in an X-linked manner and is caused by mutations in the COL4A5 gene. This gene is responsible for encoding type IV collagen. We observed three generations of a family with hematuria onset in childhood. The proband is a 29-year-old female with a history for microscopic hematuria and mild proteinuria since age 5. Family history is relevant for ESRD and microscopic hematuria in her sister, her father and her aunt. Genetic analysis was performed in 10 members of the family. A nucleotide change c.1147G>C (p.Gly383Arg) was identified, causing an amino acid substitution of Gly to Arg at position 383 in heterozygous carriers in exon 19 of COL4A5 in 8 of the patients. The amino acid substitution affected a very important structure of collagen's– Gly-X-Y repeats, which resulted in the production of a pathogenic molecule.

**Key words:** genetic disorder, COL4A5 gene, nucleotide change c.1147G>C (p.Gly383Arg)

---

Date of Submission: 18-11-2019

Date of Acceptance: 04-12-2019

---

### I. Introduction

In 1927 Dr. Arthur Cecil Alport described three generations of a family with combinations of haematuria and deafness where the males were affected more severely than the females and some of the family members went on to develop renal failure. He suggested that this combination of symptoms represented a specific clinical syndrome but it was not until 1961 that the syndrome was named after him.

Alport syndrome is a genetic disorder characterized by kidney disease, hearing loss, and eye abnormalities. Most affected individuals experience progressive loss of kidney function, usually resulting in end-stage chronic kidney disease. [1]. It occurs in approximately 1 in 50,000 newborns [2].

In 80% of the cases Alport syndrome is inherited in an X-linked manner and is caused by mutations in the COL4A5 gene. Autosomal recessive and dominant forms also exist due to mutations in COL4A3 or COL4A4 that present in 15% and 5% of cases, respectively [3]. Alport syndrome is a genetically heterogeneous disease; however, the pathogenesis of X-linked Alport syndrome is attributed to mutations in one of the three genes encoding type IV collagen  $\alpha$ -chain isoforms ( $\alpha 3$ ,  $\alpha 4$ , and  $\alpha 5$ ). These genes are necessary for proper GBM development, which plays a crucial role in plasma filtration [4].

X-linked Alport syndrome is one of the most severe forms of inherited glomerulopathy and is characterized by the alternating thinning and thickening of the GBM, as well as splitting and lamellation of the lamina densa. At a young age, affected hemizygous males and heterozygous female carriers may present initially with a uniform thinning of the GBM, which progresses rapidly in affected males to a more severe thickened and lamellated structure. This is typically accompanied by the onset of proteinuria, hypertension, and renal failure, subsequently leading to ESRD sometime between adolescence and 30 years of age. In addition, sensorineural hearing loss and ocular abnormalities are present in approximately 82% and 44% of Alport syndrome patients, respectively [5].

Clinical presentation of Alport syndrome includes hematuria which is usually microscopic. Affected males have persistent microhematuria. Episodes of gross hematuria may also be observed. More than 90% of females with X-linked Alport syndrome have persistent or intermittent microhematuria. [6]. Hematuria appears to be persistent in both males and females with ARAS. About 50% of carriers of COL4A3 or COL4A4 mutations have hematuria [7,8].

Proteinuria is usually absent early in life, but increases progressively with age and may result in nephrotic syndrome. With progression of the disease the blood pressure rises and the renal function starts to decline slowly. End-stage renal disease develops in all affected males with XLAS, at a rate determined primarily by the nature of the underlying COL4A5 mutation. (5) Risk factors for chronic kidney disease (CKD) in affected

females are gross hematuria in childhood, nephrotic syndrome, and the finding of diffuse GBM thickening by electron microscopy[9].

Another symptom is high-frequency sensorineural hearing loss. Deafness occurs in about 80% of males and 25% to 30% of females with AS.[5,10].Hearing loss in Alport syndrome is never congenital.The patients with autosomal recessive Alport syndrome typically have childhood hearing loss, whereas the patients with autosomal dominant Alport syndrome develop it at a later age. It is estimated that about 80% of males with X-linked Alport syndrome develop hearing loss at some point in their lives, often by the time they are teenagers. In females with X-linked Alport syndrome hearing loss is less frequent and occurs later in life[11].

Ocular abnormalities occur in 30% to 40% of XLAS males and in about 15% of XLAS females.[5,10].Anterior lenticonus occurs in about 15% of X-linked Alport syndrome males and is almost entirely restricted to AS families with progression to ESRD before 30 years of age and deafness[5]. It is absent at birth, usually appearing during the second to third decade of life, and is bilateral in 75% of patients. Other common ocular manifestations of Alport syndrome are maculopathy, posterior polymorphous dystrophy and recurrent corneal erosion.

The association of AS with leiomyomatosis of the esophagus and tracheobronchial tree[12], bilateral posterior subcapsular cataracts and aneurysmal dilation of the thoracic and abdominal aorta[13] have also been reported.

In this study, we have described a novel mutation in the COL4A5 gene and characteristics of the disease in a Bulgarian family with X-linked Alport syndrome. Clinical examinations revealed that all affected family members have hematuria, 3 of them - renal dysfunction resulting in ESRD, one of the patients has hearing abnormalities and 4 of them have ocular abnormalities – astigmatism. We identified a novel pathogenic mutation determining the amino acid substitution of glycine to arginine at position 383 in heterozygous carriers in exon 19 of the COL4A5 gene, which may be clinically significant.

## **II. Materials and Methods**

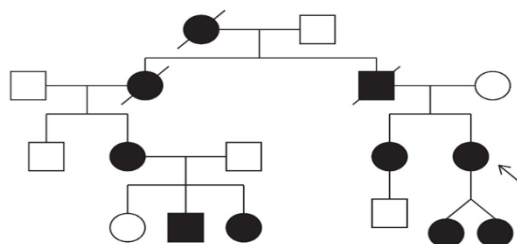
### **Study subjects**

The Bulgarian family with Alport syndrome is from Varna, Bulgaria. Clinical diagnosis was made by a physical exam, ocular examination and standard audiometry tests. Renal biopsy was performed in 3 other members of the family. Chronic glomerulonephritis was diagnosed in 2 of them, and one member has been diagnosed with chronic tubulointerstitial nephritis. Genetic analysis was performed in 10 members of the family.

We observed three generations of a family with hematuria onset in childhood. The proband is a 29-year-old female with a history for microscopic hematuria and mild proteinuria since the age of 5 years. A family history is relevant for ESRD and microscopic hematuria in her sister, her father and her aunt. The father had hearing loss. Her paternal grandmother had a history of kidney disease, without ESRD, and passed away at the age of 52 from an unknown etiology. The two proband's daughters were with hematuria, mild proteinuria and diffuse parenchymal changes in both kidneys shown on renal ultrasonography.

The proband was observed and diagnosed at the Nephrology Department in the University Hospital “St. Marina” Varna, Bulgaria in 2014. Urine analysis showed signs of proteinuria (0.15 g/day) and microscopic hematuria, ACR 2,76 g/mol, PCR – 13,64 g/mol. Clinical laboratory analysis revealed the following: hemoglobin (Hg) concentration 124 g/L, WBC  $6,7 \times 10^9/L$ ; RBC  $4 \times 10^{12}/L$ , PLT  $196 \times 10^9/L$ , creatinine (75 mmol/L), glomerular filtration rate (92 mL/min), Total Protein – 79,8 g/l, Albumin – 49 g/l, Cholesterol – 5,4 mmol/l, Triglycerides – 0,54 mmol/l, CRP – 0,08 mg/l. Immunology tests (antinuclear antibodies (ANA), anti-DNA antibodies, anti-sm- antibodies, anti-RNP-antibodies, anti-SS-A antibodies, anti-SS-B-antibodies, anti-Scl-70 antibodies, anti-Jo-1 antibodies, and anti-neutrophilic cytoplasmic antibody (ANCA)) are negative. The concentration of IgA in the sera was 1,53 g/l. Diffuse parenchymal changes in both kidneys were shown on renal ultrasonography. Symptoms such as edema or hypertension were not observed (blood pressure 85/55 mmHg). Arenal biopsy was performed and chronic glomerulonephritis was diagnosed. An audiogram confirmed normal hearing.

The other observed family members have no history of hearing loss, confirmed on formal serial evaluations, 4 of them have astigmatism. Renal biopsy was performed in 3 other members of the family because of the hematuria and proteinuria. Chronic glomerulonephritis was diagnosed in 2 of them, and one member has been diagnosed with chronic tubulointerstitial nephritis. One patient was with proteinuria in the nephrotic range. The family's pedigree is shown in Fig 1.



**Fig.1**

*Pedigree of a Bulgarian Family with X-Linked Alport Syndrome.*

*The proband is marked by an arrow. Affected individuals with kidney disease are shown with blackened squares (males) and circles (females). Normal individuals are shown with empty squares (males) and circles (females). Crossed squares or circles denote deceased individuals.*

### III. Results

Diagnosis is based on family history, clinical signs, kidney biopsy and genetic testing. We have identified the disease and inheritance pattern as X-linked Alport syndrome resulting from mutations in COL4A5. A genetic analysis was performed in 10 members of the family. We identified a nucleotide change c.1147G>C (p.Gly383Arg), causing an amino acid substitution of Gly to Arg at position 383 in heterozygous carriers in exon 19 of COL4A5 in 8 of the patients. The amino acid substitution affected a very important structure of collagen's – Gly-X-Y repeats, which resulted in the production of a pathogenic molecule.

### IV. Discussion

In this study, we investigated a Bulgarian family with Alport syndrome. Through genetic analysis we identified a novel mutation - a nucleotide change c.1147G>C (p.Gly383Arg), causing an amino acid substitution of Gly to Arg at position 383 in heterozygous carriers in exon 19 of COL4A5. The amino acid substitution affected a very important structure of collagen's – Gly-X-Y repeats, which resulted in the production of a pathogenic molecule.

Most reported COL4A5 mutations are missense mutations located primarily in the collagenous portion of the  $\alpha 5$ -collagen chains that incorporate conserved glycine residues important for the steric arrangement of the collagen chain [14]. Wang et al. previously studied the effect of glycine substitutions (G1015V and G1030S) on the collagen  $\alpha 5$ (IV) chain structure and structure-phenotype correlations in Alport syndrome. They concluded that the changes in the secondary protein structure might explain the phenotypic diversities of X-linked Alport syndrome [15]. In addition, glycine substitutions in the collagenous domain of the  $\alpha 5$  (IV)-chain will result in an adult form of Alport syndrome with a mean ESRD onset age of 35.8 years [15,16]. Barshagul T. Baikara et al. identified a nucleotide change 1922 G>A, causing amino acid substitutions of glycine to glutamic acid at position 641, in exon 25 of the COL4A5 gene in members of a Kazakh family. However, the proband of their study and her brother exhibited renal impairment during childhood. [17]

Two forms of X-linked Alport syndrome are usually recognized based on the age of onset of ESRD and the rate of clinical progression: the classical, well-recognized "juvenile" type and the "adult" type [18]. In the former, ESRD ensues rapidly in men in their twenties, whereas ESRD presents in a delayed fashion in the latter [19].

In conclusion, a novel mutation has been identified in the COL4A5 gene in patients with Alport syndrome. The phenotypic presentation has an important role to predict the prognosis of the disease and to provide better genetic counseling for affected families.

### References:

- [1]. Alport syndrome. Genetics Home Reference. December 2013; <http://ghr.nlm.nih.gov/condition/alport-syndrome>.
- [2]. Alport syndrome. Genetics Home Reference. December 2013; <https://ghr.nlm.nih.gov/condition/alport-syndrome#statistics>
- [3]. Lemmink HH, Mochizuki T, van den Heuvel LP, Schröder CH, Barrientos A, Monnens LA, et al. Mutations in the type IV collagen alpha 3 (COL4A3) gene in autosomal recessive Alport syndrome. *Hum Mol Genet.* 1994;3: 1269–1273. [PubMed] [Google Scholar]
- [4]. Kalluri R, Shield CF, Todd P, Hudson BG, Neilson EG. Isoform switching of type IV collagen is developmentally arrested in X-linked Alport syndrome leading to increased susceptibility of renal basement membranes to endoproteolysis. *J Clin Invest.* 1997;99: 2470–2478. [PMC free article] [PubMed] [Google Scholar]
- [5]. Jais JP, Knebelmann B, Giatras I, De Marchi M, Rizzoni G, Renieri A, et al. X-linked Alport syndrome: natural history in 195 families and genotype-phenotype correlations in males. *J Am Soc Nephrol.* 2000;11: 649–657. [PubMed] [Google Scholar]
- [6]. Kashtan CE, Kleppel MM, Gubler MC. Immunohistologic findings in Alportsyndrome. *ContribNephrol.* 1996;117:142-153.
- [7]. Boye E, Mollet G, Forestier L, et al. Determination of the genomic structureof the COL4A4 gene and of novel mutations causing autosomal recessiveAlport syndrome. *Am J Hum Genet.* 1998;63:1329-1340.
- [8]. Heidet L, Arrondel C, Forestier L, et al. Structure of the human type IV collagen gene COL4A3 and mutations in autosomal Alport syndrome. *J Am SocNephrol.* 2001;12:97-106.
- [9]. Grunfeld JP, Noel LH, Hafez S, Droz D. Renal prognosis in women withhereditary nephritis. *Clin Nephrol.* 1985;23:267-271.

- [10]. Jais JP, Knebelmann B, Giatras I, et al. X-linked Alport syndrome: Natural history and genotype-phenotype correlations in girls and women belonging to 195 families—A “European Community Alport Syndrome Concerted Action” study. *J Am Soc Nephrol.* 2003;14:2603-2610.
- [11]. <https://www.alportsyndrome.org/what-is-alport-syndrome/>
- [12]. Antignac C, Heidet L. Mutations in Alport syndrome associated with diffuse esophageal leiomyomatosis. *Contrib Nephrol.* 1996;117:172-182.
- [13]. Earl TJ, Khan L, Hagau D, Fernandez AB. The spectrum of aortic pathology in Alport syndrome: A case report and review of the literature. *Am J Kidney Dis.* 2012;60:821-822.
- [14]. Persikov AV, Pillitteri RJ, Amin P, Schwarze U, Byers PH, Brodsky B. Stability related bias in residues replacing glycines within the collagen triple helix (Gly-Xaa-Yaa) in inherited connective tissue disorders. *Hum Mutat.* 2004;24: 330–337. [PubMed] [Google Scholar]
- [15]. Wang YF, Ding J, Wang F, Bu DF. Effect of glycine substitutions on alpha5(IV) chain structure and structure-phenotype correlations in Alport syndrome. *Biochem Biophys Res Commun.* 2004;316: 1143–1149. [PubMed] [Google Scholar]
- [16]. Hertz JM. Alport syndrome. Molecular genetic aspects. *Dan Med Bull.* 2009;56: 105–152. [PubMed] [Google Scholar]
- [17]. Barshagul T, Baikara, Elena V, Zholdybayeva, Saule E, Rakhimova, Nazym B, Nigmatullina, Kuvat T, Momynaliev, Yerlan M, Ramanculov. A Novel Mutation in a Kazakh Family with X-Linked Alport Syndrome Published online 2015 Jul 13. doi: 10.1371/journal.pone.0132010
- [18]. Gross O, Netzer KO, Lambrecht R, Seibold S, Weber M. Meta-analysis of genotype-phenotype correlation in X-linked Alport syndrome: impact on clinical counselling. *Nephrol Dial Transplant.* 2002;17: 1218–1227. [PubMed] [Google Scholar]
- [19]. Haas M. Alport syndrome and thin glomerular basement nephropathy: a practical approach to diagnosis. *Arch Pathol Lab Med.* 2009;133: 224–232. [PubMed] [Google Scholar]

Benkova-Petrova M. “ A family case of X-linked Alport syndrome patients with a novel mutation.” *IOSR Journal of Dental and Medical Sciences (IOSR-JDMS)*, vol. 18, no. 11, 2019, pp 10-13.