

## Maxillary All-On-4 Implant Supported Fixed Full Arch Prosthesis As A Management For Anterior Maxillary Residual Alveolar Ridge Resorption In Combination Syndrome Cases.

Mohamed Saad Alrajhi<sup>1</sup>, Moustafa Elsayad<sup>2</sup>, ElSayedAbd Elkhalek<sup>3</sup> and Ahmed Habeeb<sup>4</sup>

<sup>1</sup> Master degree, Faculty of Dentistry, University of Mansoura.

<sup>2</sup> Professor of Prosthodontics, Department of Prosthodontics, Faculty of Dentistry – Mansoura University.

<sup>3</sup> Associated Professor of Prosthodontics, Department of Prosthodontics and Faculty of Dentistry – Mansoura University.

<sup>4</sup> Professor of Prosthodontics, Department of Prosthodontics, Faculty of Dentistry – Mansoura University.

---

### Abstract

**Purpose:** The aim of this preliminary study was to evaluate the effect of placement four implants following All-on-4 concept on anterior bone resorption in the upper completely edentulous patients opposing class I removable partial denture.

### Materials and methods:

Six patients with total edentulous maxillary ridges and partially edentulous mandibular ridges (class I Kennedy classification) were received maxillary fixed prosthesis on 4 implants according to the All on four protocol and mandibular distal extension RPD (Study group). The control group consisted of six patients whom received conventional maxillary dentures and distal extension mandibular RPD without any implant treatment. Evaluation of maxillary bone resorption for both groups was made at time of prosthesis insertion (T0) and 5 years later (T2) using the proportional area measurements made on digital panoramic radiographs for anterior 2.

**Results:** Control group showed highly significant higher anterior bone loss than test group ( $P < .001$ ).

**Conclusion:** Within the limitation of this study, All on four fixed prosthesis for edentulous maxilla opposed by remaining mandibular anterior teeth reduces maxillary anterior alveolar bone loss compared to conventional dentures. However, it does not prevent maxillary bone loss.

---

Date of Submission: 18-11-2019

Date of Acceptance: 04-12-2019

---

### I. Introduction

Maxillary completely edentulous cases with remaining lower anterior teeth treated with conventional upper single complete denture and lower partial dentures were found to have extrusion and overeruption of lower anterior teeth with their alveolar ridges and loss of lower posterior alveolar bone support which results in reversing the occlusal plane and increase forces of occlusion exerted on the upper anterior region causing the premaxilla becomes atrophied with instability upper denture during function resulting in papillary hyperplasia of the hard palate and extrusion of tuberosity area after long term of use resulting in condition known as combination syndrome which was described first by Kelly<sup>1</sup>

The improvement of upper anterior denture foundation area with placement of dental implants to assist upper complete denture with attachment was investigated early<sup>2</sup> and it was found that subjectively it improved patients' satisfaction as a result of increased stability and support. But patients are still wearing complete denture with palatal coverage and posterior residual ridge support.

Paulo Maló in 1990s developed a new concept for full arch rehabilitation based on four implants known as (All-On-4) where four implants are placed in the anterior maxilla or mandible avoiding posterior areas anatomical limitations by increasing the anterior posterior spread of implants distribution by simply tilting the posterior implant by 30 to 45 degrees posteriorly allowing the immediate support to 12-14 unit full arch bridge.<sup>3</sup>

Krekmanov et al, recommended the posterior tilting of distal implants as it will reduce cantilever lengths, increase anterior posterior spread, broaden the prosthetic base and improve implant to bone surface areas because longer implants can be used. The All-on-4 treatment concept has several advantages: (1) maximal use of the available bone to avoid invasive bone grafting procedures, resulting in significantly less morbidity; (2) minimization of micromovement to achieve osseointegration steadily; (3) placement of acrylic interim

protheses on the day of surgery for immediate loading of implants and maintaining oral functions; and (4) dramatically lower financial costs and less time-consuming treatment.<sup>4</sup>

Reviewing the literature, the use of All on four maxillary fixed prosthesis in prevention of development of combination syndrome was not a concern. Moreover, there is a lack of studies evaluating the maxillary bone loss under All on four fixed screw retained prosthesis.

## **II. Materials and methods**

Twelve patients with total edentulous maxillary ridges and partially edentulous mandibular ridges (class I Kennedy classification) were selected from outpatient clinic of the prosthodontic department, faculty of dentistry, Mansoura University with ages between 56 to 64 years. All selected patients were wearing upper complete removable denture and lower class I removable partial denture with dissatisfaction from the retention and stability of the upper denture. All patients were found to be healthy, free from any systemic diseases that relate to bone resorption such as uncontrolled diabetes or osteoporosis which was confirmed by physical examination. CBCT was done for each one to evaluate bone quantity and quality at the anterior area of maxilla and confirm ability to receive implants of at least 3.75 mm diameter and 11 mm length and were at least one year passed from the last extraction. The restorative space was evaluated from the mucosa covering the crest of the residual ridge to proposed occlusal plane to sufficient to receive fixed restoration (*class I and II according to Ahuja and Cagna*)<sup>5</sup>

On the other hand, patients with previous head and neck radiotherapy, patients with bleeding disorders or hepatic patients, metabolic disorders as uncontrolled diabetes mellitus, osteoporosis, long term immunosuppressive, corticosteroid drug therapy, neuromuscular diseases or TMJ problems were excluded. Or even patient who showed abnormal habits like clenching, bruxism, heavy smoking, uncooperating were also excluded. The patients were classified into 2 groups: 1- Study group; included 6 patients whom received four implants in the edentulous maxillary arch according to the All-on-four® concept and the implants were immediately loaded with maxillary denture. 2- Control group; included 6 patients whom received conventional maxillary dentures and distal extension mandibular partial dentures only without any implant treatment in the maxillary arch. The groups were not randomized. After the patients were informed about the line of treatment and the need for regular and frequent recalls, they all signed a written consent. The study was conducted according to the ethical principles stated and approved by the ethical committee of the faculty of dentistry (No.01020418).

### **Surgical and prosthetic procedures**

For study group, surgical stereolithographic guide was constructed using double-scanned or (dual scan protocol) as follow: radiographic template was constructed from modification of the old denture with holes that were drilled with (2mm in diameter) on the polished and fitting surface in different areas and filled with radiopaque material gutta percha. The radiopaque markers will act as specific reference points that allow super imposition of the digitized radiographic template from the 1<sup>st</sup> exposure to the radiographic template alone outside patients mouth. The 2<sup>nd</sup> exposure to the patient during wearing and occluding on the radiographic template result in CBCT image of the patient with radiopaque dots appear only over the bone. After overlapping the digitized radiographic model over the maxillary bone in the second CBCT image guided by the radiopaque dots using OnDemand 3D planner (fig. 1) we can evaluate mucosal thickness covering the residual ridge, implant relation to denture teeth and then virtual planning for the position and angulation of implants after specifying their type, diameter, length and distribution in order to design a specific surgical guide for each patient (fig. 2) which was done by one investigator.<sup>6</sup>

For each case the four implants were virtually placed using the accompanying software following the All on four protocol.<sup>7</sup>

Two implants were designed to be at canine/lateral incisor area perpendicular to occlusal plane and paralleling to each other, while the posterior ones were designed to be at premolar area just anterior to maxillary sinus and tilted distally forming a 30-degree angle from the vertical plane which allowed them to emerge in the mesial region of the first molar tooth. After virtual planning to the mucosal support surgical guide model and selecting positions of the anchor pins to be one in the mid line and 2 bilaterally in the molar areas, the STL file was sent to be printed in 3D printer using stereolithography technology\* with metal tubes that guide drilling in the proper planed angulation and position. A universal surgical kit\*\* was supplied with the template and consists of fixation pins, depth control drills, drills, initial drills and tissue punch, all which used during osteotomy preparation. Also, it includes the hand drill sleeves with successive increasing diameters that fits the template's sleeves. These sleeves were used during consecutive drilling to accommodate increasing in drill diameter.

---

\* Object 30 pro 3D printer (Stratasys, California, USA).

\*\* In2Guide Universal Kit Cybermed Inc.

Each patient was instructed to use chlorhexidinedigluconate 0.2% Started 3 days before surgery, immediately before the procedure rinsing or swabbing the mouth for 1 to 2 minutes, then daily for 7 days following the surgical procedure. And they also instructed to use amoxicillin and clavulanic acid (Augmentin® 1gm) were taken at 8 hours and 1 hour before the surgery and for 10 days following the procedure. Four implants were placed in their preplanner positions and angulations using one staged flapless protocol guided with the stereolithographic surgical guide(fig. 2). The implants insertion torque was sure to be at least 40 Ncm in order to allow immediate loading, however when the bone quality was low specially in the maxillary bone, we skipped the last osteotomy drill in order to allow increase resistance from surrounding bone during fixture insertion. After fixtures insertion multiunit abutments with 17° were screwed to the anterior fixtures in order to upright labial inclination of anterior implants while multiunit with 32° were screwed to the posterior fixtures to upright the posterior tilting. The old complete denture was modified to act as an immediate screw retained full arch prosthesis. Holes were drilled through the old complete denture opposite to the multiunit abutments guided by bite registration paste added to the fitting surface of the denture and the denture was placed in the mouth in its place. After setting of the bite registration material the imprints of the multiunit abutments located the areas where the holes made. Temporary metal caps were screwed to the multiunit abutments and checked through the prepared holes in the denture. Pickup of the temporary metal caps and incorporation to the complete denture was done using auto polymerized acrylic resin after blocking out to undercuts surrounding the multiunit abutments using rubber dam and utility wax below it. After curing of the resin the complete denture is unscrewed through the metal caps to be finished and polished at the same time the old denture was modified by removing the flanges and second molar tooth and reducing occlusal surface of the 1<sup>st</sup> molar in order to reduce occlusal loads on the inclined posterior implants the anterior canine area shared most of the occlusal loads in centric and lateral occlusal contacts.<sup>8</sup>

All patients were left for six months with the immediate modified complete denture for osseointegration then they were appointed for making the final impression on which master cast was obtained for the construction of the permanent restoration. At the final impression appointment an open tray multiunit abutment level impression was made by screwing in the long transfer abutment to the multiunit abutments and splinted to each other using light cure composite resin and dental floss stretched between the transfer copings in order to prevent movement during impression making. Perforated stock tray opposite to the transfer copings was tried in then light body addition silicon rubber base material was injected around transfer copings while heavy body material was loaded to the stock tray at the same time to be inserted over the transfer copings till the top of the transfer coping appeared through the impression material. Unscrewing to the transfer coping was done to allow removal of the impression. Multiunit analogues were connected to the transfer abutment before pouring the impression with extra hard stone to form the master cast. On the master cast we constructed screw retained ceramometal full arch prosthesis(fig. 3). The prosthesis was checked for passivity using one screw test of Sheffield intra orally by screw only the last abutment and evaluate the others to be not lifted then repeat the test for other abutments. The bridge was screwed to the abutment at 20 Ncm torque, oral hygiene measures were stressed and reviewed.

### **Evaluation of anterior maxillary bone resorption**

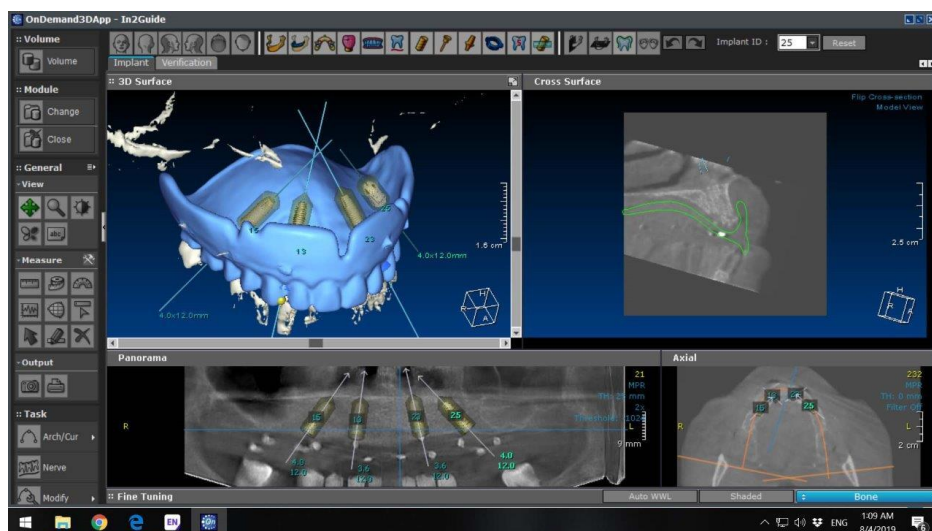
The anterior maxillary bone resorption was evaluated using panoramic x-ray Maxillary bone resorption was evaluated using the proportional area measurements previously described by *Kreisler, et al.*<sup>9</sup> Evaluation at two intervals for each group, at time of denture insertion (control group) or implant loading (study group) (T0) and 2 years later (T2).

In order to standardize the panoramic x-ray images each patient had a customized acrylic occlusal stent connected to the chin stabilizer of the panoramic x-ray device in order to guide the patients head to a fixed repeatable position in relation to the panoramic device. The panoramic device was adjusted to a fixed parameter (69 kV with a constant current of 16 mA/s and an exposure time of 16 seconds) the panoramic x-ray images produced was accepted only if the anatomical reference land marks were clear. After accepting the panoramic radiographic image Reference points and lines were traced on the images digitally using *AutoCAD 2008 (Autodesk, Inc., USA)*. As follow: Anterior nasal spine S, two lowermost bony margins of the orbit  $O_{right}$  and  $O_{left}$ , line  $o$  joins  $O_{right}$  and  $O_{left}$  and form the 'central triangle' with S (OSO). P line begins from point S and interscet with O line at right angle at point P,  $P'$  was marked by measuring the distance  $SP$  starting from S downward, the point R divides the distance  $PO$  into two thirds and one third. From point R a line  $r$  runs perpendicular to OP line downward on each side,  $u$  is a line parallel to  $o$  through S,  $u$  and  $r$  meet at the point U.  $R'$  was marked by measuring the distance  $UR$  starting from U, the line  $i$  connects  $R'_{right}$  and  $R'_{left}$  passing through  $P'$ . 1 is the intersection of the alveolar crest with  $p$ , 2 is the intersection of the alveolar crest with  $r$ . According to this design the anterior alveolar bone area is divided into two sides. For each side the experimental area is outlined by the area  $S12U$  and the reference area by the area  $SP'R'U$ .<sup>10</sup>

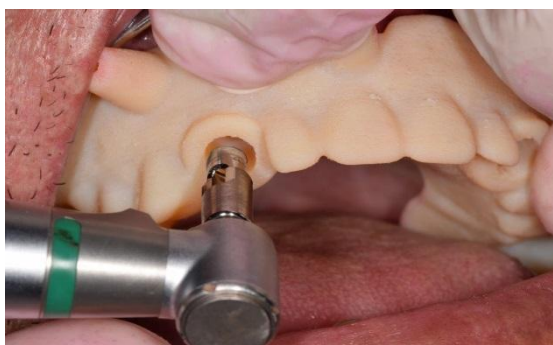Anatomic and reference areas on the right and left sides were pooled and a ratio (R) for the anterior bone area was calculated as follows:  $R = \text{experimental} / \text{reference area}$ . The anterior maxillary residual ridge resorption was calculated by subtracting R at T0 from R at T2. A negative difference indicated bone resorption, and a positive difference indicated bone apposition<sup>11</sup>. Radiographic measurements were done by one operator (P.S.W) blinded to treatment groups.

### Statistical analysis

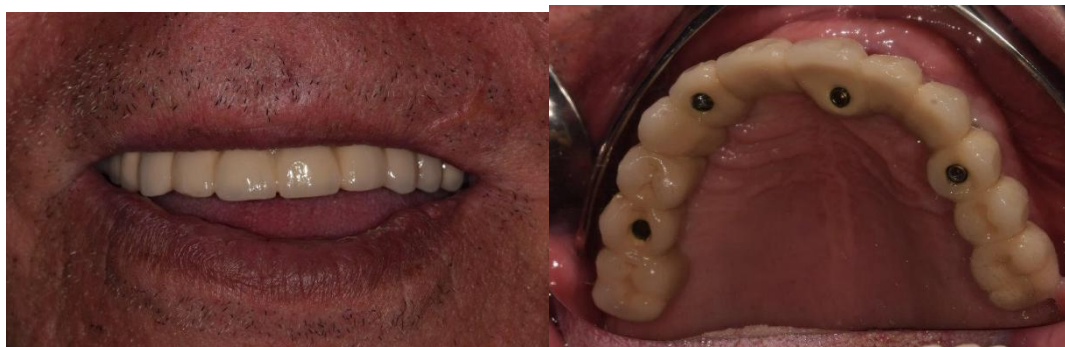All data were analysed with SPSS program version 22 Statistical Packages for Social Science (SPSS Inc., Chicago, IL, USA). Differences in maxillary bone ratios (R) between the 2 groups were analyzed with Mann Whitney test. P is significant if  $< 0.05$  at confidence interval 95%. P was significant if it was  $< .05$ .



**Fig 1.** The CT scan and virtual implant planning using the soft ware



**Fig 2.** Implants placement steps using stereolithographic implant guide following All-on-4 protocol.



**Fig 3.** Insertion of the Fixed partial denture

### III. Results

- Base line characters of participants at the beginning of the study was demonstrated in table 1.
- Comparison of base line characters are presented in the same table
- No difference in base line criteria between groups at the beginning of the study was noted

#### Comparison of R of anterior maxillary areas between groups

- Negative sign indicated bone resorption and positive sign indicated bone deposition.
- Descriptive statistics of R values in terms of mean, standard deviation, median, minimum, maximum was presented.
- Comparing alveolar bone changes in the anterior area of maxilla indicated that there was significant bone loss (<.001\*) noticed in the control group. (table2) and (fig. 4)

Table (1) Baseline criteria of the study groups

	Control group	Study group	P value
Mean age	55.66±3.01	57.26±3.11	.85
Sex (male/female)	(4/8)	(4/8)	.99
Maxillary bone height	16.1±1.1	17.4±1.4	.88
Period of edentulism	3.8±1.01	2.1±.99	.36
Anterior ridge length	24.8±2.1	25.9±1.8	.89
Posterior ridge length	37.1±2.1	37.8±2.6	.41

Table (2) Mean change in R for anterior and posterior areas in both groups

		Anterior R	
Control group	X		-.506
	SD		.042
	M		-.530
	Min		-.56
	Max		-.45
Study group	X		-.153
	SD		.024
	M		-.1500
	Min		-.19
	Max		-.12
P value			<.001*

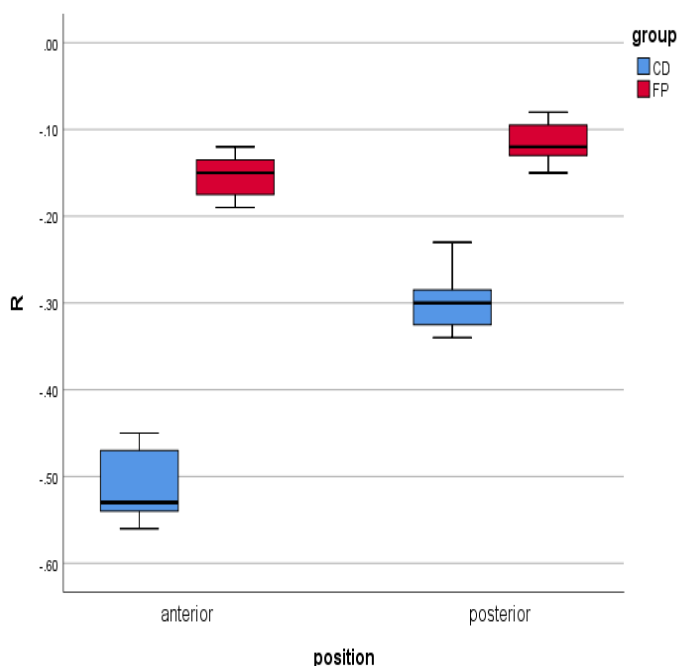


Fig 3. Boxplot showing comparison of R between groups for anterior and posterior maxillary areas

#### IV. Discussion

Increasing the functional loading on the anterior portion of the completely edentulous maxillary residual ridge opposed by remaining lower anterior teeth or even complete lower overdenture assisted with anterior implants was found to result in bone resorption in the anterior part of the residual ridge of maxilla with flappy tissue formation a syndrome was described by Kelly known as combination syndrome.

Improving the supporting structure of the anterior portion of maxillary residual alveolar ridge in these cases by All on Four implant supported fixed screw retained prosthesis in rehabilitation of edentulous maxilla was proved to be an efficient and successful long-term prosthetic solution as tilting implants reduce cantilever lengths, better implant anchorage, short cantilever length, and large inter implant distance which allows broaden prosthetic base by increase prosthesis length with an average of 6.6mm in the mandible and 9.3mm in the maxilla which resulted in better biomechanics. and improve implant to bone surface areas because longer implants<sup>12,13</sup>

The provisional denture contained 10 teeth, the cantilever posterior to the last implant was avoided to minimize the risk of fracture. For final restoration, in this study the cantilever length was less than 1.5 the anteroposterior spread as suggested by *Mericske-Stern*.<sup>14</sup> This provided a significant alternative for restoration of maxillary and mandibular posterior segment without bone grafting.

The degree of how much this treatment modality can preserve bone loss in these cases in comparison to the conventional complete denture was not determined.

However panoramic radiographs have some limitations like magnification, distortion, head positioning errors<sup>15</sup> and reduced radiation dose by five times in comparison to CBCT evaluation<sup>16</sup>. The proportional measurements are suitable and reliable for the assessment of residual resorption in the maxilla than absolute measurements.<sup>9</sup>

In anterior maxillary areas, CD group showed significant higher bone loss than All on four group. The effect of prosthesis was that FP had .270 lower change maxillary bone loss than CD i.e. CD had .270 more bone loss compared to FP (All on four group). Which was in agreement with the findings of Kelly # as he related anterior maxillary bone loss and flappy tissue formation to increased bone loading from the increased biting forces from the opposed natural mandibular anterior teeth and a class I removable partial denture over a 3-year period using cephalometric radiographs and found a loss of 1 to 3 mm of anterior maxillary ridge height. That was explained biomechanically as during loading the CD a fulcrum line will be formed at the area of premolar allowing the CD to rotate anteriorly compressing the anterior area of maxilla causing overloading and decompression to the posterior area, the anterior overloading was related to patients preference to bite on the remaining anterior teeth, over eruption of remaining anterior teeth and lower posterior bone resorption under class I partial denture.<sup>17</sup>

Combination syndrome was also noticed in cases had upper CD opposed by lower complete overdenture assisted with two anterior implants, which has the same biomechanical explanation<sup>11,18</sup>

Kreisler et al.<sup>15</sup> in a retrospective study, found higher resorption in the anterior (5- 12%) than in the posterior part (2-7%) of the edentulous maxilla opposed by mandibular ovoid bar retained overdentures on 2 implants after 8 years. Other authors found a decrease in bone height in the anterior region than in the posterior region of maxillary jaw bone.

They attributed their finding to the transference of significant occlusal forces into the anterior maxilla with subsequent maxillary alveolar bone resorption and soft tissue inflammation. Also they explained this finding to the instability of the complete dentures, which contributes to an unfavorable stress distribution among the denture bearing areas.<sup>19</sup>

Jacobs et al. were found a significant vertical bone loss in the anterior maxillary bone radiographically per year was ranged, from 0.00 to 0.99 mm, with a mean of 0.28 mm in mucosa implant-supported mandibular complete overdenture, compared with that using mucosa-supported one<sup>20</sup>

Another study was done by Barber et al.<sup>21</sup> were reported a mean vertical bone loss in the anterior maxilla of 0.43 mm + 1.36 per year under maxillary CD opposing trans mandibular implants.

In contrast, *Narhi et al.*<sup>22</sup> concluded that the decrease in the width of the maxillary residual ridge was small and not associated with the type of mandibular denture, being an implant supported overdenture on five bars retained by a trans mandibular implant, an implant-mucosa-supported overdenture on a single bar retained by two implants or a conventional complete denture.

*Tymstra et al.*<sup>11</sup> have studied the effect of different lower prosthesis support on the degree of maxillary bone resorption restored with CD they found that mean reduction in the measured proportional areas in the anterior maxilla was 0.12 in the two-implant group, and 0.11 in the four-implant group which was higher than that of CD group (0.04) after 10-year evaluation period concluded that fixed implant-supported mandibular prostheses are superior to overdentures with regard to the preservation of the alveolar ridge in the opposing maxilla and in the posterior mandible due to equal occlusal loading anteroposteriorly.

Using implants to provide total support for the maxillary prosthesis will protect the residual alveolar ridge from occlusal loading and then prevent bone resorption which was found in our study after placement of four implants following the concept of All-on-four. This finding was in agreement with a systematic review made by *Khalifa AK et al.*<sup>23</sup> as they reported that implant restoration has a noticeable residual alveolar ridge preservation which varies from reducing rate of physiologic resorption to bone apposition.

However, when *Narhi et al.*<sup>22</sup> adopted occlusal concept with anterior open bite occlusion, as an attempt to avoid overloading of the anterior maxillary ridge, it was found that the reduction in the anterior ridge was not associated with implant supported or conventional removable prostheses.

The limitations of this study include the small sample size, and the short follow up period. Therefore, future long term randomized controlled trials are needed to ensure the findings of this study.

## V. Conclusion

Within the limitation of this study, All on four fixed prosthesis for edentulous maxilla opposed by remaining mandibular anterior teeth reduces maxillary anterior alveolar bone loss compared to conventional dentures. However, it does not prevent maxillary bone loss.

## References

- [1]. Kelly E. Changes caused by a mandibular removable partial denture opposing a maxillary complete denture. *J Prosthet Dent.* 1972;27:140-150.
- [2]. Cune MS, de Putter C HJ. Treatment outcome with implant-retained overdentures: Part II--Patient satisfaction and predictability of subjective treatment outcome. *J Prosthet Dent.* 1994;72:152-158.
- [3]. Maló P, Rangert B NM. "All-on-Four" Immediate-Function Concept with Brånemark System® Implants for Completely Edentulous Mandibles: A Retrospective Clinical Study. *Clin Implant Dent Relat Res.* 2003;5:2-9.
- [4]. Krekmanov L, Kahn M, Rangert B LH. Krekmanov L, Kahn M, Rangert B, Lindstrom H. Tilting of posterior mandibular and maxillary implants for improved prosthesis support. *Int J Oral Maxillofac Implants.* 2000;15:405-414.
- [5]. Ahuja S CD. Defining available restorative space for implant overdentures. *J Prosthet Dent.* 2010;6:104:133.
- [6]. Browaeys H, Dierens M, Ruyffelaert C, Matthijs C, De Bruyn H VS. Ongoing Crestal Bone Loss around Implants Subjected to Computer-Guided Flapless Surgery and Immediate Loading Using the All-on-4® Concept. *Clin Implant Dent Relat Res.* 17:831-843.
- [7]. Malo P, de Araujo Nobre M, Lopes A, Francischone C RM. 'All-on-4' immediate-function concept for completely edentulous maxillae: a clinical report on the medium (3 years) and long-term (5 years) outcomes. *Clin Implant Dent Relat Res.* 2012;139-50(14).
- [8]. Weinstein R, Agliardi E, Fabbro MD, Romeo D FL. Immediate rehabilitation of the extremely atrophic mandible with fixed full-prosthesis supported by four implants. *Clin Implant Dent Relat Res.* 2012;14:434-441.
- [9]. Kreisler M, Schulze R, Schalldach F, d'Hoedt B, Behneke A BN. A new method for the radiological investigation of residual ridge resorption in the maxilla. *Dentomaxillofac Radiol.* 2000;29:368-375.
- [10]. Elysyad MA HA. Implant-supported versus implant-retained distal extension mandibular partial overdentures and residual ridge resorption: a 5-year retrospective radiographic study in men. *Int J Prosthodont.* 2011;24:306-313.
- [11]. Tymstra N, Raghoebar GM, Vissink A MH. Maxillary anterior and mandibular posterior residual ridge resorption in patients wearing a mandibular implant-retained overdenture. *J Oral Rehabil.* 2011;38:509-516.
- [12]. Krekmanov L, Kahn M, Rangert B LH. Tilting of posterior mandibular and maxillary implants for improved prosthesis support. *Int J Oral Maxillofac Implant.* 2000;15:405-414.
- [13]. Saunders TR, Gillis RE, Jr. DR. The maxillary complete denture opposing the mandibular bilateral distal-extension partial denture: treatment considerations. *J Prosthet Dent.* 1979;41:124-128.
- [14]. Mericske-Stern RD, Taylor TD BU. Management of the edentulous patient. *Clin Oral Implant Res.* 2000;11(1):108-125.
- [15]. Kreisler M, Behneke N, Behneke A d'Hoedt B. Residual ridge resorption in the edentulous maxilla in patients with implant-supported mandibular overdentures: an 8-year retrospective study. *Int J Prosthodont.* 2003;16:295-300.
- [16]. Chau AC FK. Comparison of radiation dose for implant imaging using conventional spiral tomography, computed tomography, and cone-beam computed tomography. *Oral Surg Oral Med Oral Pathol Oral Radiol Endod.* 2009;107:559-565.
- [17]. A T. The continuing reduction of the residual alveolar ridges in complete denture wearers: a mixed-longitudinal study covering 25 years. *J Prosthet Dent.* 1972;27:120-132.
- [18]. Thiel CP, Evans DB BR. Combination syndrome associated with a mandibular implant-supported overdenture: a clinical report. *J Prosthet Dent.* 1996;75:107-113.
- [19]. Abd El-Dayem MA, Assad AS A-GM. The effect of different mandibular dentures on antagonistic maxillary ridge. *Implant Dent.* 2007;16:421-429.
- [20]. Jacobs R, van Steenberghe D, Nys M NI. Maxillary bone resorption in patients with mandibular implant-supported overdentures or fixed prostheses. *J Prosthet Dent.* 1993;70:135-140.
- [21]. Barber HD, Scott RF, Maxson BB FR. Evaluation of anterior maxillary alveolar ridge resorption when opposed by the transmandibular implant. *J Oral Maxillofac Surg.* 1990;48:1283-1287.
- [22]. Narhi TO, Geertman ME, Hevinga M, Abdo H KW. Changes in the edentulous maxilla in persons wearing implant-retained mandibular overdentures. *J Prosthet Dent.* 2000;84:43-49.
- [23]. Kreisler M, Behneke N, Behneke A d'Hoedt B. Residual ridge resorption in the edentulous maxilla in patients with implant-supported mandibular overdentures: an 8-year retrospective study. *Int J Prosthodont.* 2003;16:295-300.

Disha Modi. "A Rare Case of Spontaneous Hemoperitoneum in a Gravid Patient Uterine Variceal Rupture." *IOSR Journal of Dental and Medical Sciences (IOSR-JDMS)*, vol. 18, no. 11, 2019, pp 11-17.