

## Posterior Condylar Foramina of Occipital Bone: Anatomical Variations And Clinical Implications

Pooja K, Singh S, Rani A

Department of Anatomy, King George's Medical University, Lucknow, Uttar Pradesh, India  
Corresponding Author: Pooja K.

---

### Abstract

**Introduction:** The condylar fossa, lies immediately posterior to occipital condyle and may contain a posterior condylar canal for an emissary vein from the sigmoid sinus. Opening of this canal is known as posterior condylar foramen. Anatomical variations of the posterior condylar foramina are important during the treatment of dural arteriovenous fistula. Aim was to study the variations of posterior condylar foramina in North Indian skulls.

**Material & Methods:** The study included 50 dry skull bones irrespective of age and sex from Department of Anatomy, King George's Medical University, Lucknow, Uttar Pradesh, India. The study was done by naked eye examination carefully and by passing the probe in the foramen.

**Results:** Out of 50 human dry skulls, posterior condylar foramen was observed in 47 skulls. The presence of bilateral posterior condylar foramina was noted in 27 skulls (54%) and unilateral foramina in 20 (left 10, right 10) skulls (40%) while foramen was absent in 3 (6%) skulls.

**Conclusion:** The study gives basic knowledge to the clinicians and surgeons before planning a surgery in the occipital condylar region.

**Keywords:** occipital, foramen, condylar, posterior, skull.

---

Date of Submission: 13-11-2019

Date of Acceptance: 27-11-2019

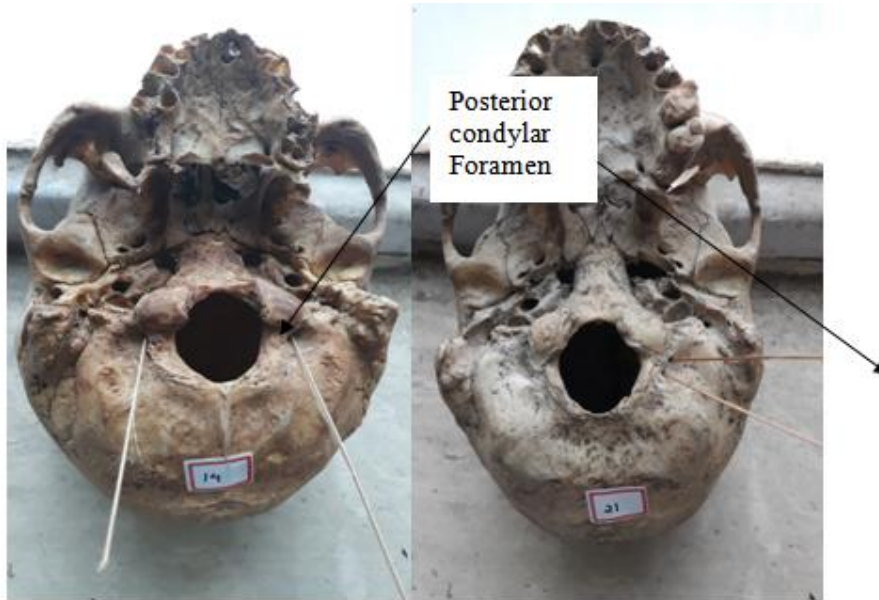
---

### I. Introduction

At the base of skull, occipital bone is having two lateral condyles on either side of foramen magnum for articulation of the superior articular facets of the atlas vertebra. Occipital condyles are convex and covered with hyaline cartilage. Their posterior poles are separated by the diameter of foramen magnum, but their anterior poles are much close together. A shallow fossa is present behind each condyle and floored by thin bone known as posterior condylar fossa [1]. This fossa contains foramen or posterior condylar canal. Posterior condylar canal carries a sigmoid emissary vein from the sigmoid sinus to the suboccipital venous plexus. A condylar fossa, behind each condyle, fits the posterior margin of the superior facet of the atlas vertebra in full extension of the skull [2]. Condylar canal transmits an emissary vein to the sigmoid sinus as well as nerves, which supply the duramater of the posterior cranial fossa [3] Emissary veins are important clinically because infections from outside cranial cavity can spread to dural venous sinuses via emissary veins. For example infection can spread from mastoid to sigmoid sinus or from paranasal sinuses to cavernous sinus. These emissary veins provide an alternative venous drainage when internal jugular vein is blocked or tied [1]. Emissary condylar veins are divided into three groups as posterior, lateral and anterior condylar vein [4,5]. The posterior condylar vein usually took its origin from the superior bulb of the internal jugular vein. It courses along the posterior condylar vein canal, emerges from its foramen and drains into the deep cervical vein.

### II. Material And Method

This study was conducted on 50 dry skull bones irrespective of age and sex collected from the Department of Anatomy, King George's Medical University, Lucknow, Uttar Pradesh, India. The study was done carefully by naked eye examination by passing the probe in the posterior condylar foramen. Each cranium was observed for presence or absence, unilateral or bilateral and variations in the number of condylar canal (Fig. 1&2).



**Fig. 1: Photograph showing bilateral posterior condylar foramina**

**Fig. 2: Photograph showing unilateral double posterior condylar foramina**

### III. Observations And Results

In present study, we observed that posterior condylar foramina were present in 47 skulls of which 27 (54%) showed bilateral foramina and 20 (40%) unilateral foramina. Out of these 40% unilateral cases, 20% was present on right side and 20% on left side. The foramen was absent in rest 3 (6%) skulls (Table 1).

**Table 1: Presence of unilateral and bilateral posterior condylar foramen**

Posterior condylar foramen	Number of skulls	Percentage
Unilateral left	10	20%
Unilateral right	10	20%
Bilateral	27	54%
Absent	3	6%
Total	50	100%

In present study, we observed that 5 (10%) skulls out of 50 were having double posterior condylar canal. Out of these, 2 posterior condylar foramina were present on right side of 2 (4%) skulls and on left side of 3 (6%) skulls (Table 2).

**Table 2: Presence of number of posterior condylar foramen**

Posterior condylar foramen	No.	Number of skulls	Percentage
Right side	2	2	4%
Left side	2	3	6%
Total		5	10%

### IV. Discussion

The posterior condylar canal forms a communication between the jugular foramen and the condylar fossa just posterior to the occipital condyles. It transmits an emissary vein which allows anastomosis of the jugular bulb or sigmoid sinus to the sub-occipital venous plexus [1]. In present study, posterior condylar foramen was observed in 94% skulls among which 54% bilateral, 40% unilateral and absent in 6%. Boyd (1930) [6] found unilateral posterior condylar canal in 77% skulls, which was higher than present study. Krause (1988) [7] observed 21% bilateral and 38% unilateral posterior condylar canal, which was less as compared to our study. Ginsberg (1994) [8] did CT study of posterior condylar canal and observed that foramina were bilateral in 31% cases and unilateral in 50% cases; our findings did not coincide with his study. Vanitha et al. (2015) [9] found posterior condylar canal in 88.2% skulls out of which 49% were bilateral and 39.2% unilateral. Manoj et al. (2015) [10] observed posterior condylar canal unilateral in 33.33%, bilateral in 48.33% and

absent in 16.66% skulls. Our findings are nearly similar to this study. Berge et al. (2001)[11] found that posterior condylar canal was unilaterally double in 4% and triple in 1% skull. Vanitha et al. (2015)[9] studied 88.2% skull and found 39.2% unilateral posterior condylar canal out of which 2 foramina was present in 1.1% and 3 in 1.1% on same side of skull. In our study, unilateral double foramen was 4% on right side and 6% on left side and we did not found unilateral triple foramen in any skull of study group.

## V. Conclusion

The posterior condylar canal is one among large emissary channels in the skull. Knowledge of anatomical variations of the posterior condylar foramina provide important clues during the treatment of dural arteriovenous fistula. Also, it gives important fundamental information to the anatomists, clinicians, radiologists and surgeons prior to operative procedures involving base of skull.

## References

- [1]. Vaishnani HV, Jethva K, Sharma P, Gandotra AR, Shah GV, A study of posterior condylar foramen in human skeletal in central Gujarat region. *Int J Anat Res*, 5(4.3), 2017, 4736-39.
- [2]. Standring S, *Gray's anatomy. The anatomical basis of clinical practice*. 41<sup>st</sup> ed. (Churchill Livingstone, Elsevier), 2016, 713.
- [3]. Kothandaraman U, Lokanadham S, Posterior condylar foramen-anatomical variation, *International Journal of Medical Science and Public Health*, 4(2), 2015, 222-224.
- [4]. Reis CV, Deshmukh V, Zabramski JM, Crusius M, Desmukh P, Spetzler RF, Preul MC, Anatomy of the mastoid emissary vein and venous system of the posterior neck region: neurosurgical implications, *Neurosurgery*, 61 (5.2), 2007, 193-200.
- [5]. Jeevan DS, Anisow P, Jayamohan J, Abnormal venous drainage in syndromic craniosynostosis and the role of CT venography. *Childs Nerv Syst*, 24(12), 2008, 1413-20.
- [6]. Boyd GI, The emissary foramina of the cranium in man and the Anthropoids, *J Anat*, 65(1), 1930, 108-21.
- [7]. Krause W, The posterior condylar canal. In: Testut L, Latarjet A, eds. *Treaty of human anatomy*, (Barcelona, Spain: Salvat), 1988, 1.152-8. 7
- [8]. Ginsberg LE, The posterior condylar canal, *AJNR. Am J Neuroradiol*, 15(5), 1994, 969-72.
- [9]. Vanitha et al. Study on incidence of posterior condylar canal in North Karnataka, *Int J Clin Surg Adv*, 3(1), 2015, 50-51.
- [10]. Kumar M, Variations of posterior condylar canal in south Indian skulls, *J Pharm Sci & Res*, 7(9), 2015, 762-763.
- [11]. Berge JK, Bergman RA, Variations in size and in symmetry of foramina of the human skull. *Clin. Anat*, 14(6), 2001, 406-13.

Pooja K. "Posterior Condylar Foramina of Occipital Bone: Anatomical Variations And Clinical Implications." *IOSR Journal of Dental and Medical Sciences (IOSR-JDMS)*, vol. 18, no. 11, 2019, pp 51-53.