

## A Study on Origin Course Branching pattern and Termination of Brachial Artery in Human Cadavers

Dr T Naveen Sagar<sup>1</sup>, Dr M Venkata Raga Mayuri<sup>2</sup>

Dr T Naveen Sagar, Assistant Professor, Department of Anatomy, Apollo Institute of Medical Sciences and Research, Chittoor, Andhra Pradesh.

Phone: 8106701848, 9573084236.

Dr M Venkata Raga Mayuri, Assistant Professor, Department of Anatomy, Meenakshi Medical college, Kanchipuram, Tamil Nadu.

---

### Abstract:

**Introduction :** In present day practice of medicine and surgery every day we have cases of road traffic accidents, and direct trauma due to violence and also injuries due to sports and fall. In all the above mentioned cases injury to the arm bones and neuro vascular bundles in the arm is commonly seen. In the present study undertaken we are going to study the origin, course, branching pattern and termination of brachial artery in the upper limbs of human cadavers. Brachial artery and its variations like high division of brachial artery, superficial brachial artery, superficial brachioradial artery, trifurcation of brachial artery at its termination are commonly seen.

**Aims:** Aim of the study is to study the origin course branching pattern and termination of brachial artery in 50 upper limbs of both right and left sides in human cadavers of both sexes

**Objectives :** The objective of the study is to know the origin course branching pattern and termination of brachial artery and its importance in surgical approaches of the upper limb

**Methods :** Under aseptic precautions Standard dissection procedures were followed to dissect out the brachial arteries in the 50 upper limbs of both right and left sides in the human cadavers of both sexes and the brachial arteries were studied in detail for the origin course branching pattern and termination and images were taken with digital camera for proper presentation of the study.

**Results and conclusion:** In the present study undertaken the brachial artery along with median nerve was passing through the substance of the coracobrachials in 2 upper limb specimens rest of the brachial arteries followed the normal pattern in origin course branching pattern and termination. To conclude it is important for the surgeons especially trauma care and vascular surgeons to keep in mind the all possible variations of the neurovascular structures of the upper limb

**Key words:** Brachial artery, Superficial Brachial artery, Radial artery, Coracobrachialis

---

Date of Submission: 04-10-2019

Date of Acceptance: 21-10-2019

---

### I. Introduction

In present day practice of medicine and surgery every day we have cases of road traffic accidents, and direct trauma due to violence and also injuries due to sports and fall. In all the above mentioned cases injury to the arm bones and neuro vascular bundles in the arm is commonly seen. Minor injuries can be addressed with immobilization and proper medications. But when it comes to the management of compound comminuted fractures of humerus and associated neuro vascular trauma in the arm surgical management is the appropriate choice of treatment. To adequately repair a bone and damaged tissue in any region surgeon should have a detailed knowledge of normal Anatomy of bones, vessels, nerves, muscles and possible variations in neurovascular structures and also muscular attachments. In the present study undertaken we are going to study the origin, course, branching pattern and termination of brachial artery in the upper limbs of human cadavers. Brachial artery and its variations like high division of brachial artery, superficial brachial artery, superficial brachioradial artery, trifurcation of brachial artery at its termination are commonly seen.

### II. Aims & Objectives

**Aims:** Aim of the study is to study the origin course branching pattern and termination of brachial artery in 50 upper limbs of both right and left sides in human cadavers of both sexes

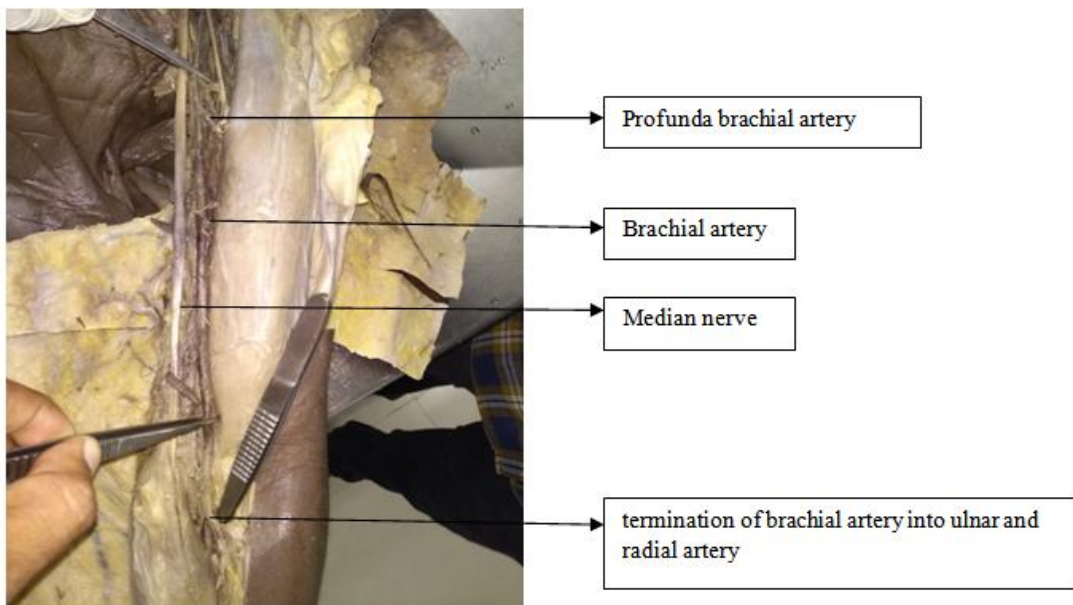
**Objectives :** The objective of the study is to know the origin course branching pattern and termination of brachial artery and its importance in surgical approaches of the upper limb

### III. Materials and Methods

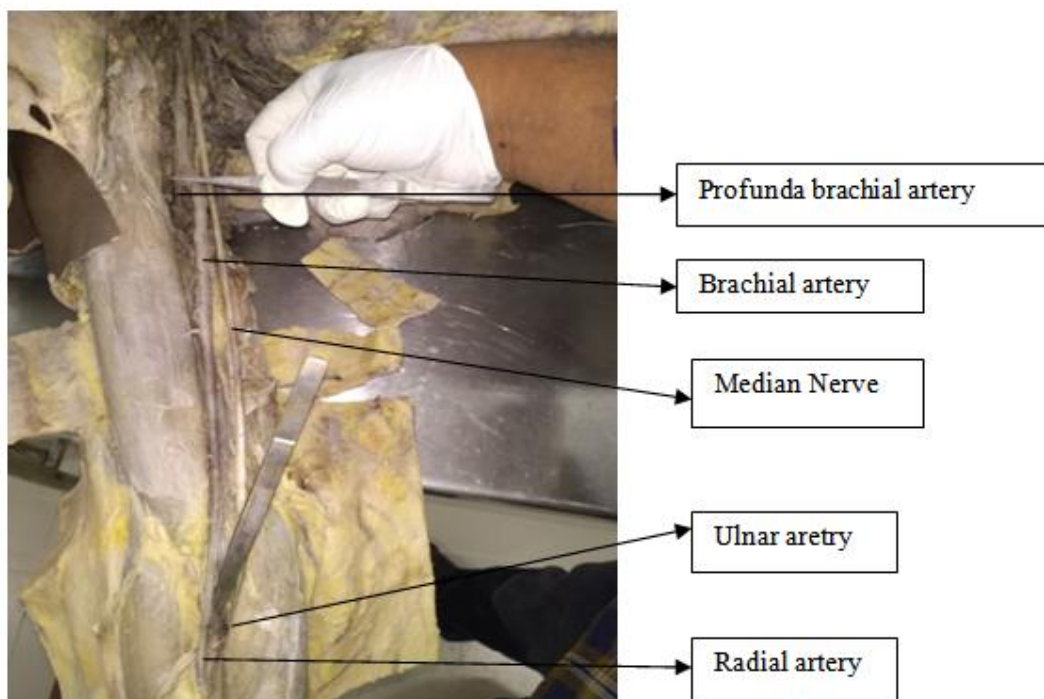
**Materials :** In the present study all the upper limbs used for the study were obtained from the Department of Anatomy, Apollo Institute of Medical Sciences and Research, Murukambattu, Chittoor, Andhra Pradesh. The materials used are as follows: Dissection knife, Toothed forceps, Blunt forceps, Pointed forceps, Scissors, needles, Cotton, A high resolution digital camera was used for obtaining high quality images. A computer was used for better presentation and editing of the study.

**Methods :** Under aseptic precautions Standard dissection procedures were followed to dissect out the brachial arteries in the 50 upper limbs of both right and left sides in the human cadavers of both sexes and the brachial arteries were studied in detail for the origin course branching pattern and termination and images were taken with digital camera for proper presentation of the study.

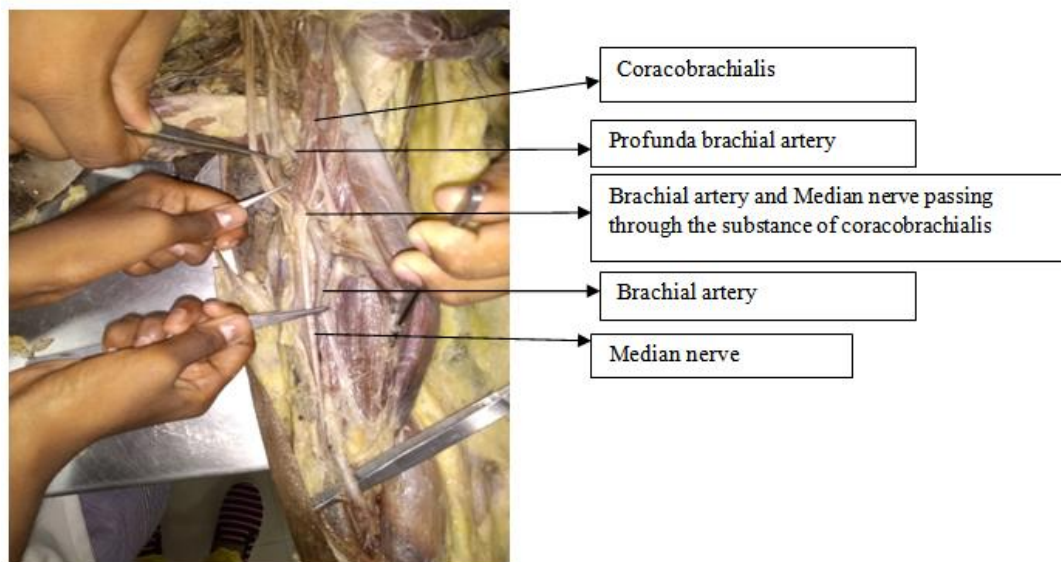
### IV. Observation and Results



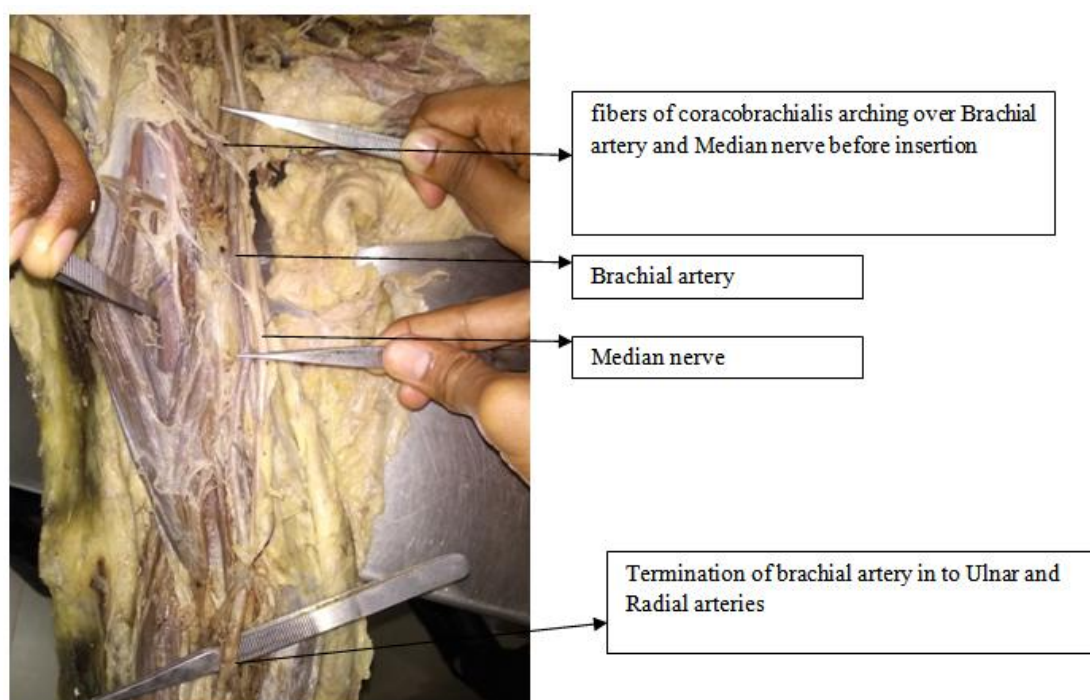
**Fig 1.** Brachial artery showing normal course



**Fig 2.** Brachial artery showing normal pattern of termination into radial and ulnar arteries.



**Fig 3.** Brachial artery along with median nerve passing through the substance of coracobrachialis in left upper limb



**Fig 4.** Few fibers of coracobrachialis arching over Brachial artery and Median nerve

**Observation and Results :** In the present study 50 upper limbs were dissected and the origin, course, branching pattern and termination of brachial arteries and its variations were studied. In all the 50 upper limbs the brachial artery was originating from the axillary artery at the level of lower border of teres major. the course of the brachial artery followed normal pattern in 48 upper limbs, in one left upper limb the brachial artery along with the median nerve was passing through the substance of the coracobrachialis (Fig 3) and rest of the course of brachial artery was normal. similar pattern was observed in one right upper limb but here only few fibers of the coracobrachialis were arching over the brachial artery and median nerve (Fig 4) and the rest of the course of the brachial artery followed normal pattern. No variations were observed in the branching pattern and termination of the brachial arteries.

## V. Discussion

According to Haładaj, Wyśiadecki, Dudkiewicz, Polgúj, Topol The radial artery was found to have a high origin in 9.2% of total number of the limbs: two cases from the axillary artery; nine cases from the brachial artery. Anastomosis between the brachioradial and "normal" brachial arteries in the cubital fossa was also frequently observed (54.6%). The anastomosis ("cubital crossover") was dominant in one case, balanced in three cases, minimal in two cases, and absent in five cases. But in present study undertaken all the radial arteries were arising from the termination of brachial artery in the cubital fossa.

According to Narayanan, Murugan brachial artery bifurcates into a common radial-interosseous trunk and superficial ulnar artery they explain it embryologically as follows the radial artery establishing a connection with the axis artery just below the level of origin of ulnar artery, the posterior interosseous artery arising from the axis artery distal to the origin of the radial artery. The part of axis artery between origin of ulnar and radial artery must have developed into the common radial-interosseous trunk. The part of axis artery between origin of radial and posterior interosseous arteries develops as the common interosseous artery. In the present study undertaken all the brachial arteries were terminating into ulnar and radial arteries there was no radial-interosseous trunk. According to Tamgire, Sontakke, Rajasekhar, Aravindhan the brachial artery was dividing into radial and ulnar arteries at the level of insertion of coracobrachialis. In the present study no such higher division of brachial artery was observed, all the brachial arteries were terminating in the cubital fossa. According to Wyśiadecki, Polgúj, Haładaj, Topol The radial artery arose under the pronator teres muscle, 76 mm below the intercondylar line of the humerus. After emerging from under the tendon of the pronator teres muscle, the radial artery took a typical course and terminated in the deep palmar arch. Additionally, the double radial recurrent artery branched directly off the brachial artery, near the level of the radial neck. According to recent theories, the plexiform appearance of the arteries at early stages of upper limb development allows for formation of alternative pathways of blood flow, which may give rise to variations in the definitive arterial pattern. According to Gupta, Anshu, Dada The brachial artery was placed superficial to median nerve in the arm and therefore it was called superficial brachial artery. In the cubital fossa, 2.8 cm distal to intercondylar line of elbow joint, this superficial brachial artery terminated by trifurcation into radial, common interosseous and ulnar branches. In the present study undertaken all the brachial arteries bifurcated into ulnar and radial arteries no trifurcation of brachial artery was observed. The main observation in the present study was the brachial artery and median nerve were passing through the substance of coracobrachialis (Fig 3) in one left upper limb and similar pattern was observed in one right upper limb but only few fibres of coracobrachialis were arching over the brachial artery and median nerve (Fig 4) and getting inserted to humerus. The embryological basis for this variation is yet to be understood.

## VI. Summary and Conclusion

The variations of neurovascular structures of the upper limb are commonly observed, the brachial artery also shows many variations like higher division into radial and ulnar arteries, radial having higher origin from axillary artery. In rare situations lower origin of radial artery at the level of pronator teres insertion. In some cases brachial artery trifurcates into radial, common interosseous and ulnar arteries. In clinical situations pseudo aneurysm of brachial artery and rarely a true aneurysm of brachial artery will also be encountered. In the present study undertaken the brachial artery along with median nerve was passing through the substance of the coracobrachialis in 2 upper limb specimens rest of the brachial arteries followed the normal pattern in origin course branching pattern and termination. To conclude it is important for the surgeons especially trauma care and vascular surgeons to keep in mind the all possible variations of the neurovascular structures of the upper limb for providing better care to the patients.

## References

- [1]. The High Origin of the Radial Artery (Brachioradial Artery): Its Anatomical Variations, Clinical Significance, and Contribution to the Blood Supply of the Hand. Haładaj R1, Wyśiadecki G1, Dudkiewicz Z2, Polgúj M3, Topol M1 *Biomed Res Int.* 2018 Jun 11;2018:1520929. doi: 10.1155/2018/1520929. eCollection 2018.
- [2]. Bifurcation of brachial artery into a common radial-interosseous trunk and superficial ulnar artery: a rare variation. Narayanan S1, Murugan S2. *Anat Sci Int.* 2018 Jun;93(3):400-403. doi: 10.1007/s12565-017-0427-5. Epub 2017 Dec 26.
- [3]. A Unique Triad of Muscular, Vascular and Nervous Variations in Upper Limb. Tamgire DW1, Sontakke YA1, Rajasekhar S1, Aravindhan K2. *J Clin Diagn Res.* 2017 May;11(5):AD01-AD03. doi: 10.7860/JCDR/2017/25552.9927. Epub 2017 May 1.
- [4]. Accessory Flexor Carpi Ulnaris and Bilaterally Variant Vascular Anatomy of Upper Limb: An Unusual Presentation. Sakthivel S1, Verma S1. *Int J Appl Basic Med Res.* 2017 Apr-Jun;7(2):143-145. doi: 10.4103/ijabmr.IJABMR\_326\_16.
- [5]. Low origin of the radial artery: a case study including a review of literature and proposal of an embryological explanation. Wyśiadecki G1, Polgúj M2, Haładaj R3, Topol M3. *Anat Sci Int.* 2017 Mar;92(2):293-298. doi: 10.1007/s12565-016-0371-9. Epub 2016 Sep 15.
- [6]. Trifurcation of superficial brachial artery: a rare case with its clinico-embryological implications. Gupta N1, Anshu A2, Dada R3. *Clin Ter.* 2014;165(5):243-7. doi: 10.7417/CT.2014.1753.
- [7]. Superficial brachial arteries observed in bilateral arms. Nakatani T1, Tanaka S, Mizukami S. *Kaibogaku Zasshi.* 1996 Aug;71(4):308-12.

*A Study on Origin Course Branching pattern and Termination of Brachial Artery in Human Cadavers*

- [8]. Superficial brachioradial artery (radial artery originating from the axillary artery): a case-report and its embryological background. Konarik M1, Knize J, Baca V, Kachlik D. *Folia Morphol (Warsz)*. 2009 Aug;68(3):174-8.
- [9]. Bilateral superficial brachial artery. Sharma T1, Singla RK, Sachdeva K. *Kathmandu Univ Med J (KUMJ)*. 2009 Oct-Dec;7(28):426-8.
- [10]. Acute Upper Limb Ischemia Due to Delayed Presentation of a Brachial Artery Pseudoaneurysm Post-Venipuncture. Lee AHH<sup>1,2</sup>, Qi SD<sup>1,2</sup>, Chiang N<sup>2</sup>. *Vasc Endovascular Surg*. 2019 Sep 18:1538574419877620.doi: 10.1177/1538574419877620.
- [11]. Giant iatrogenic pseudoaneurysm of the brachial artery: A case report.
- [12]. Leite T<sup>1</sup>, Pires M<sup>2</sup>, Pires L<sup>3</sup>, Chagas C<sup>4</sup>, Oliveira AC<sup>5</sup>. *Int J Surg Case Rep*. 2017;37:193-195. doi: 10.1016/j.ijscr.2017.06.044. Epub 2017 Jul 3.
- [13]. Median nerve neuropraxia by a large false brachial artery aneurysm. Lijftogt N<sup>1</sup>, Cancrinus E<sup>2</sup>, Hoogervorst EL<sup>3</sup>, van de Mortel RH<sup>2</sup>, de Vries JP<sup>2</sup>. *Vascular*. 2014 Oct;22(5):378-80. doi: 10.1177/1708538113516321. Epub 2013 Dec 17.
- [14]. A True Distal Brachial Artery Aneurysm Treated with a Bifurcated Saphenous Vein Graft. Ben Mrad M1, Neifer C2, Ghedira F1, Ghorbel N1, Denguir R1, Khayati A1. *Ann Vasc Surg*. 2016 Feb;31:207.e9-207.e11. doi: 10.1016/j.avsg.2015.08.009. Epub 2015 Nov 17.
- [15]. True aneurysm of brachial artery. Hudorović N1, Lovričević I, Franjić DB, Brkić P, Tomas D. *Wien Klin Wochenschr*. 2010 Oct;122(19-20):588-91. doi: 10.1007/s00508-010-1425-y. Epub 2010 Sep 27.

Dr T Naveen Sagar. "A Study on Origin Course Branching pattern and Termination of Brachial Artery in Human Cadavers." *IOSR Journal of Dental and Medical Sciences (IOSR-JDMS)*, vol. 18, no. 10, 2019, pp 22-26.